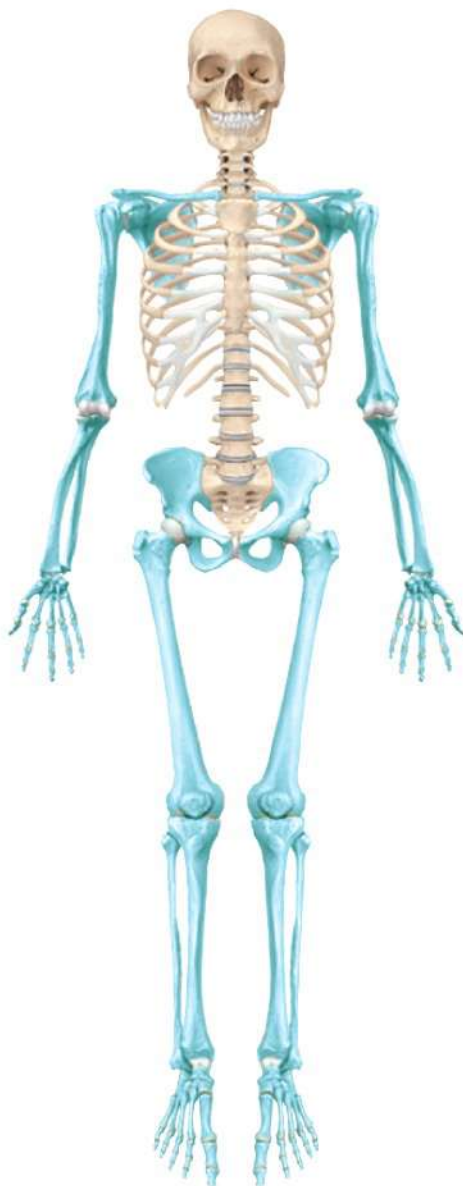

C8.4

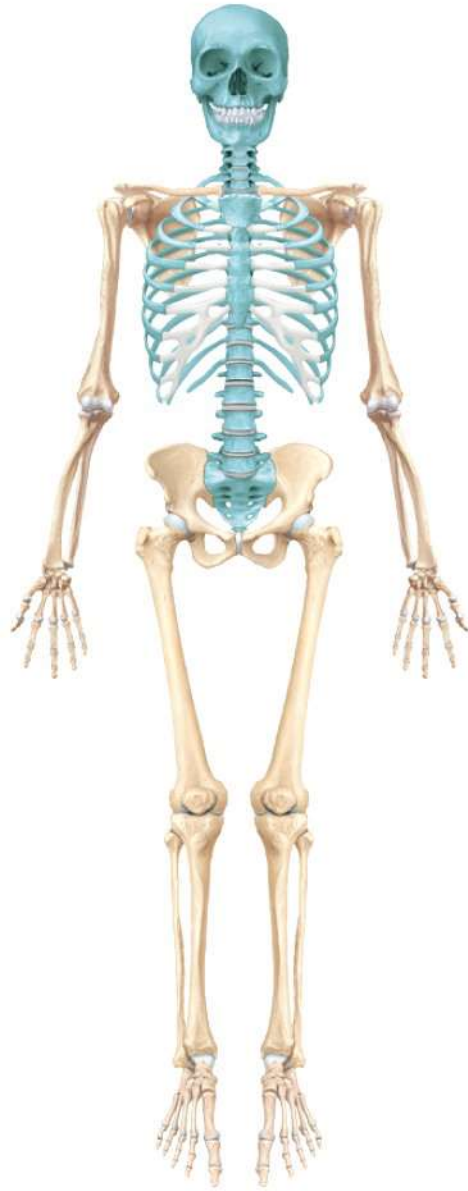The Axial Skeletal System

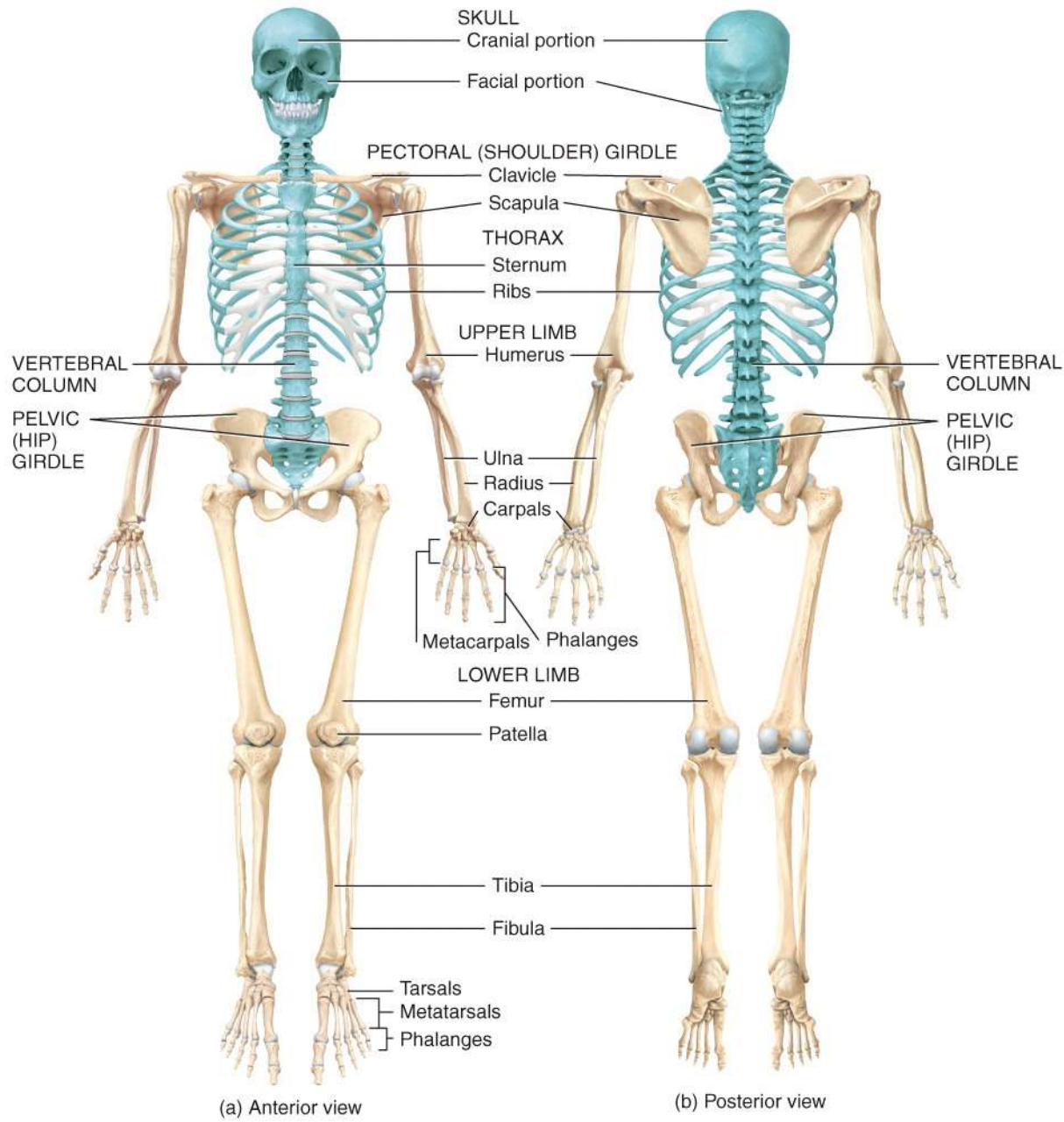
Images Only

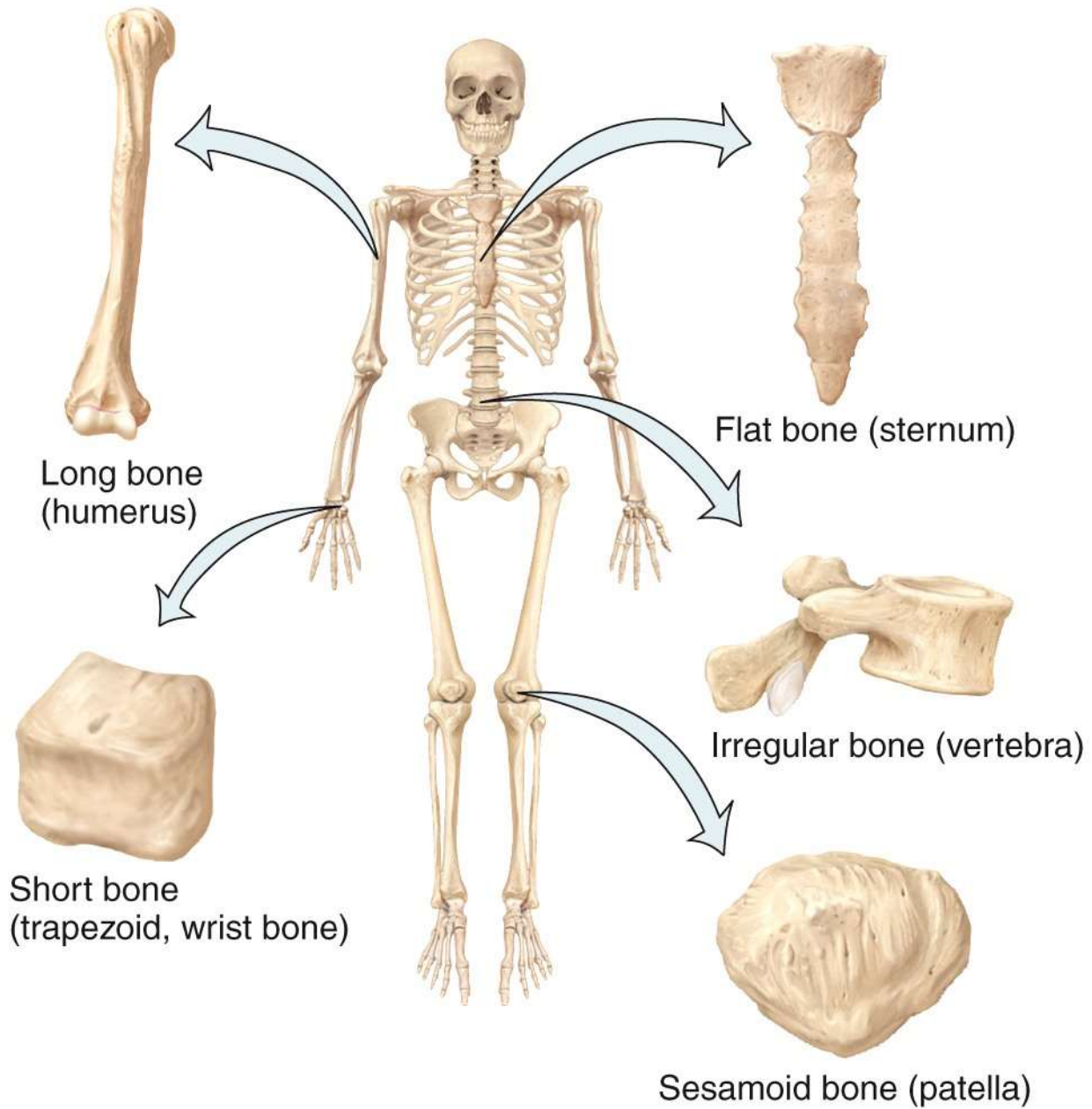
Appendicular skeleton



Axial skeleton







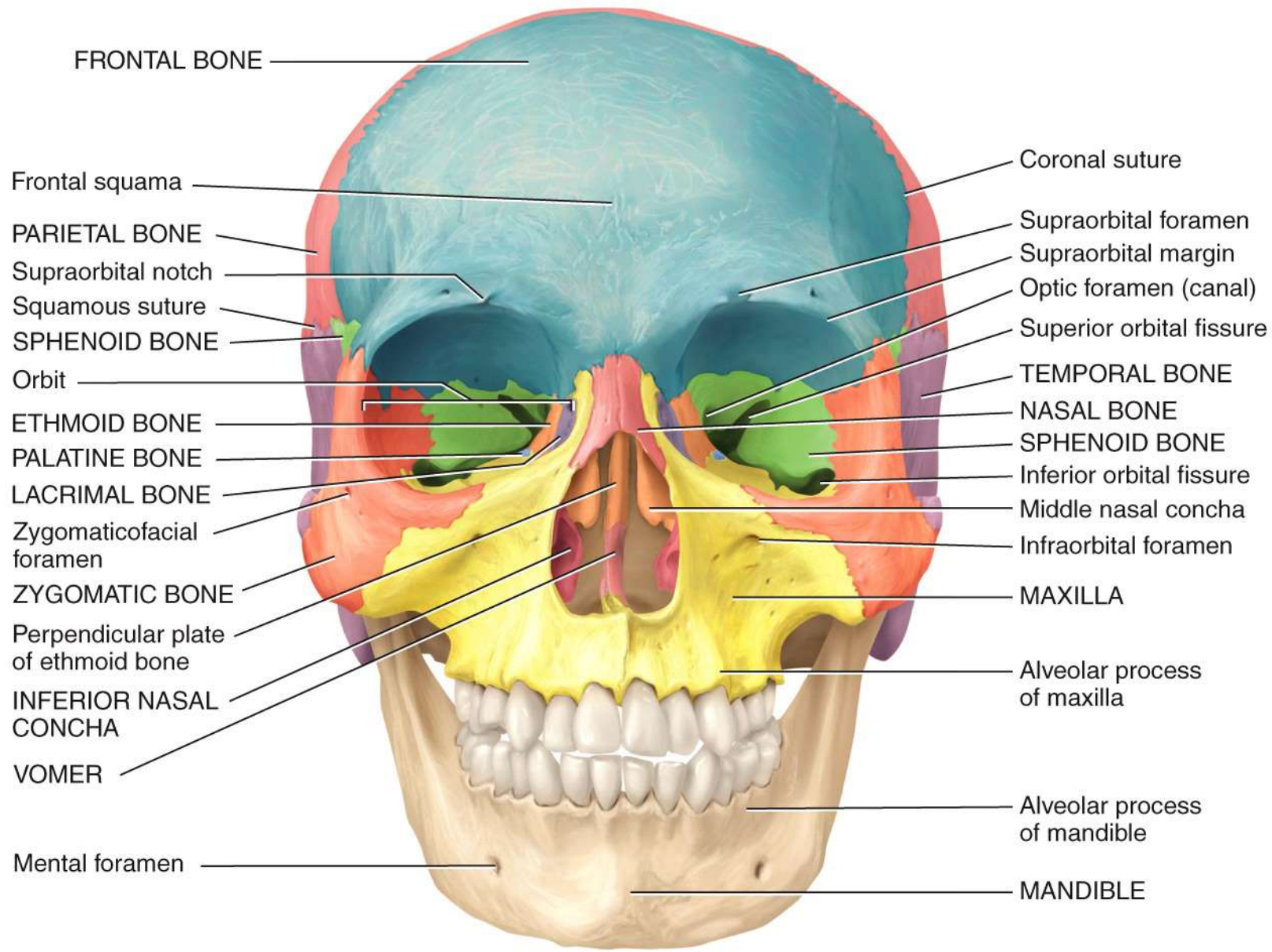
Long bone
(humerus)

Flat bone (sternum)

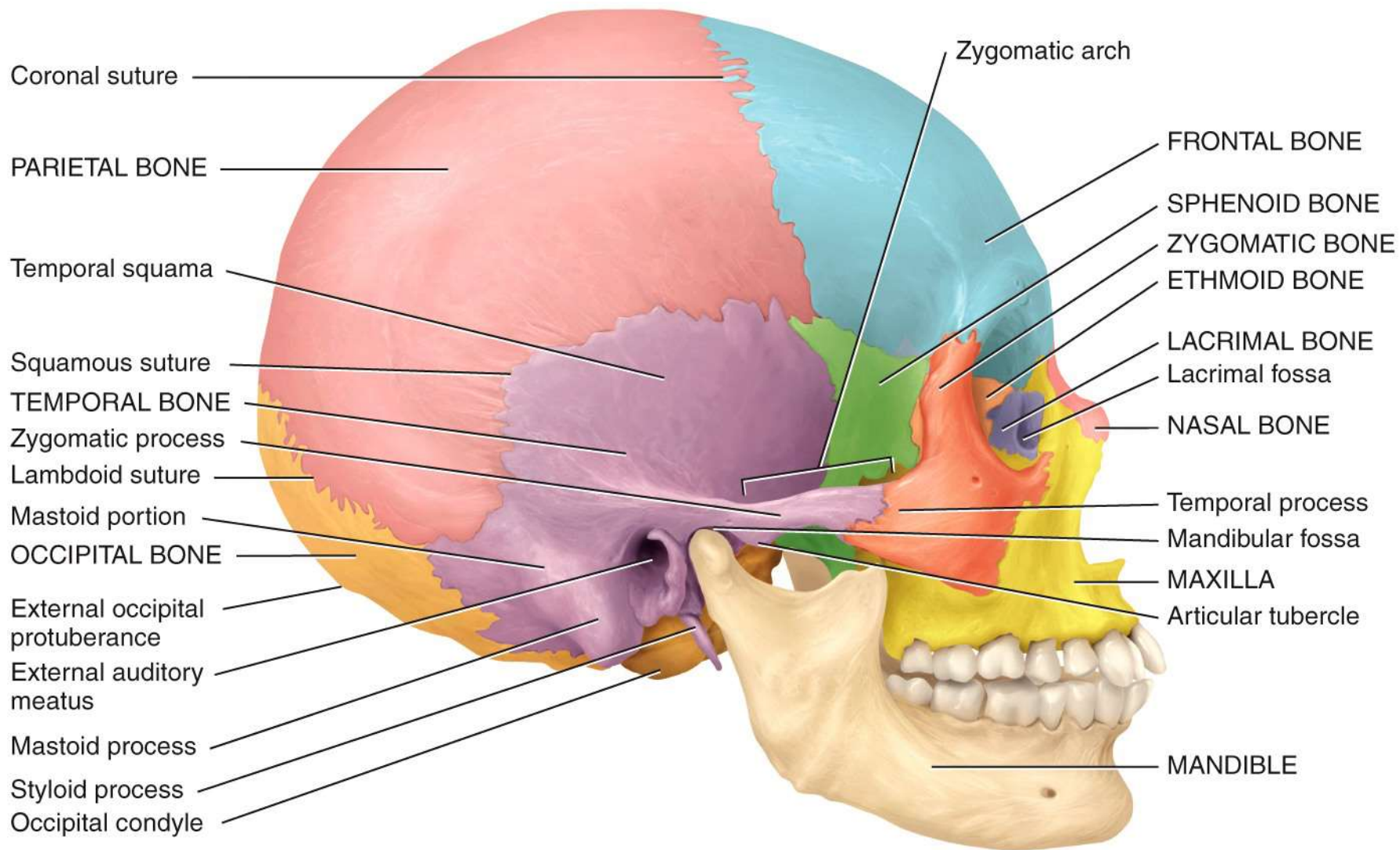
Short bone
(trapezoid, wrist bone)

Irregular bone (vertebra)

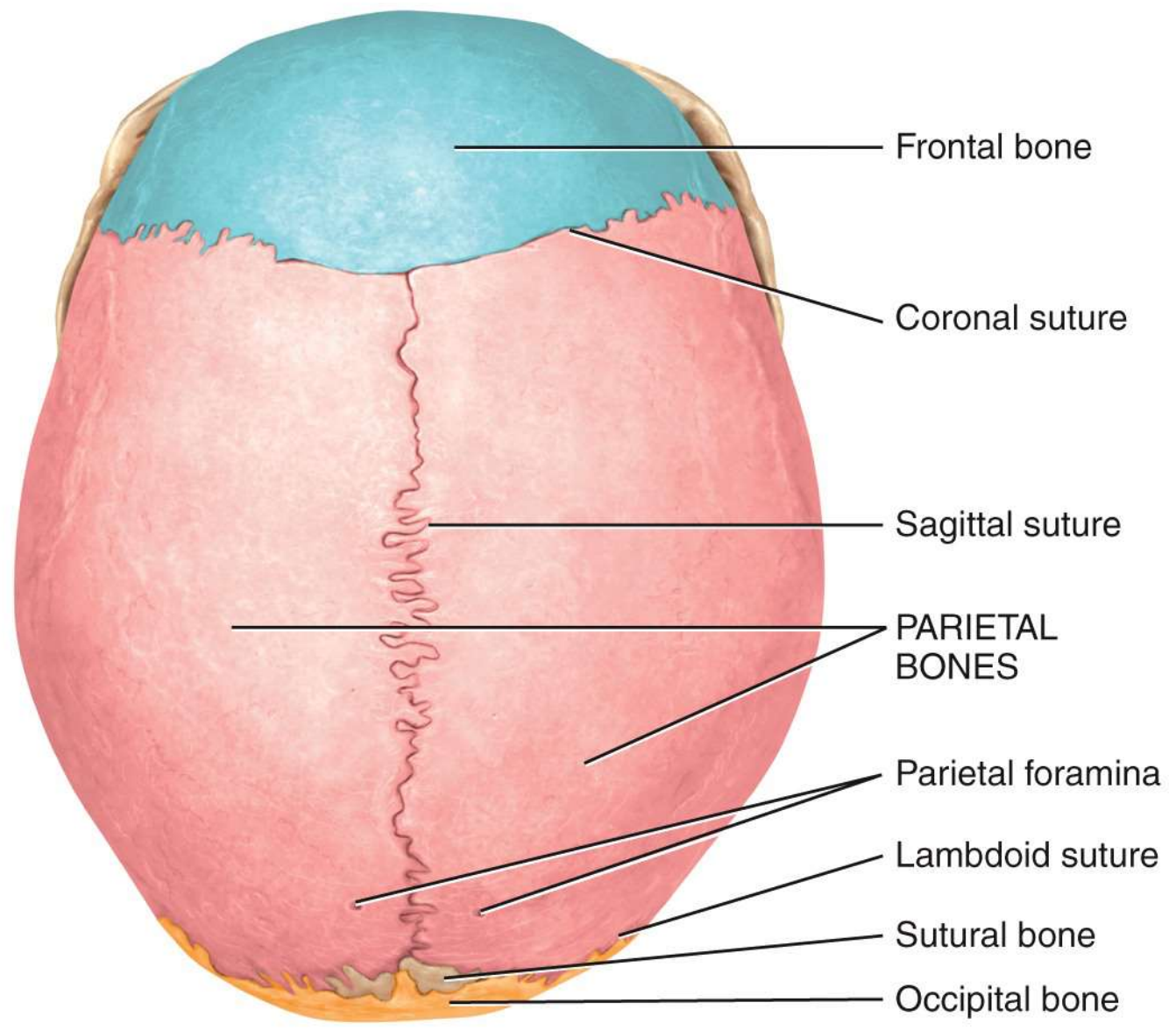
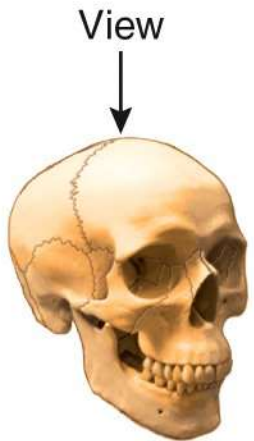
Sesamoid bone (patella)



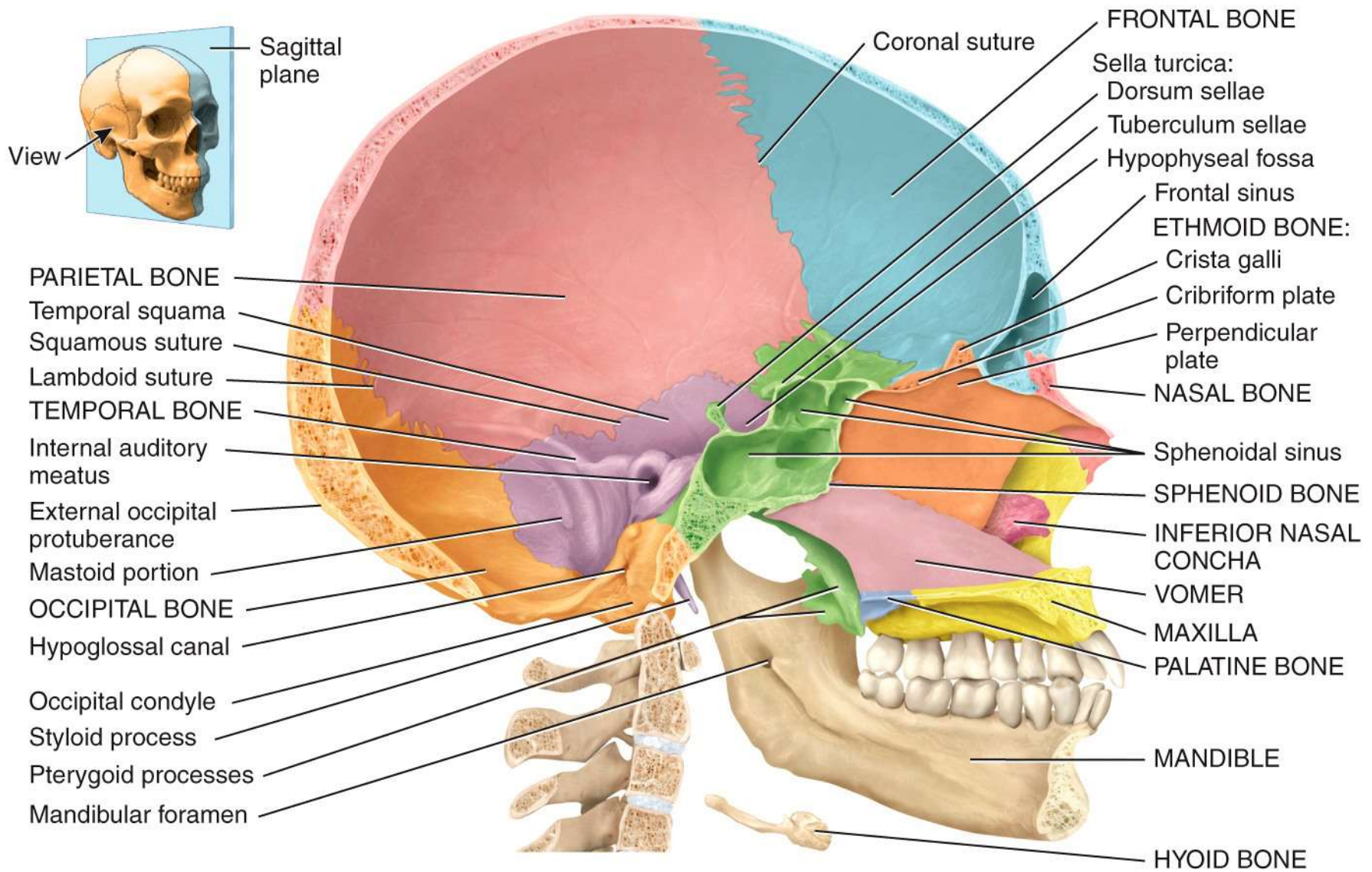
Anterior view



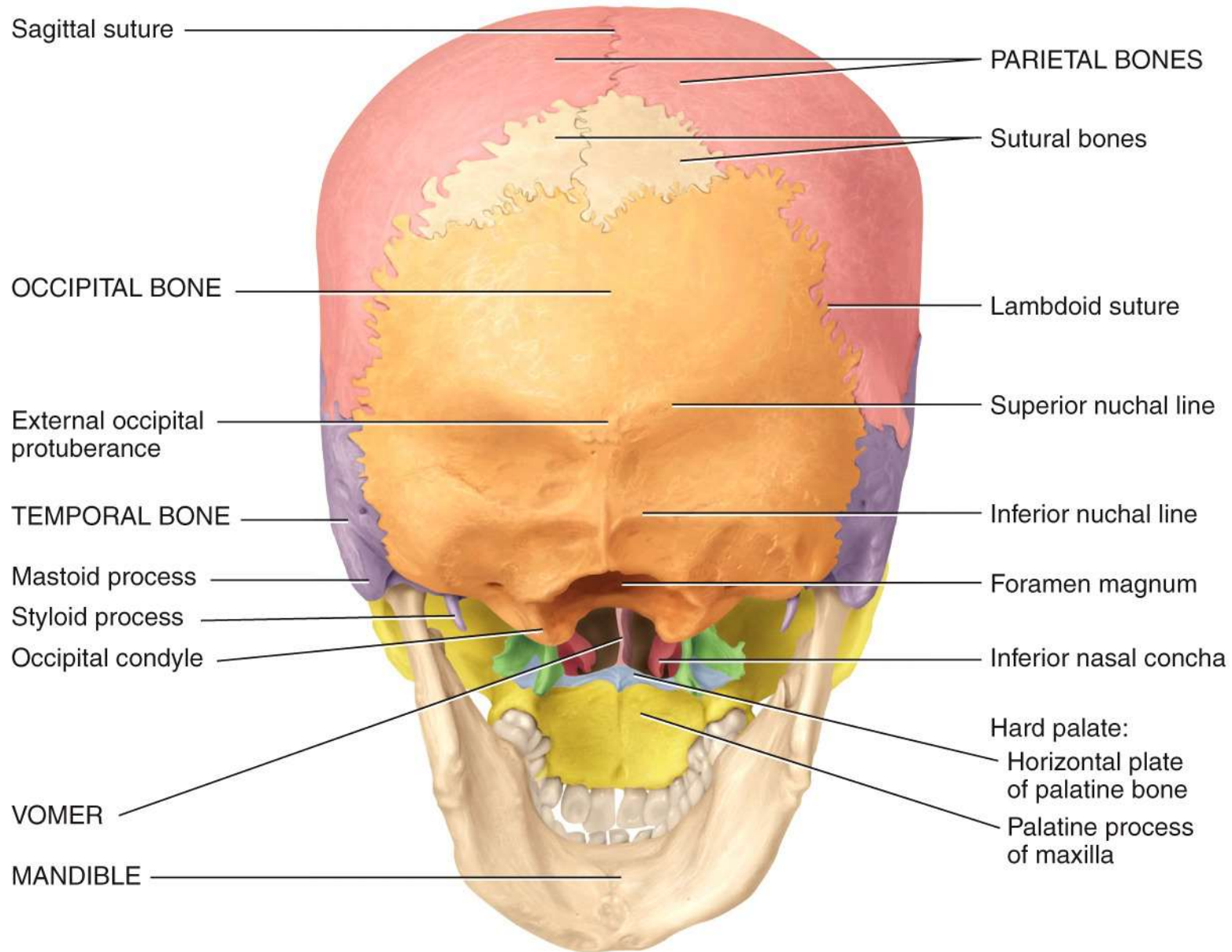
(a) Right lateral view



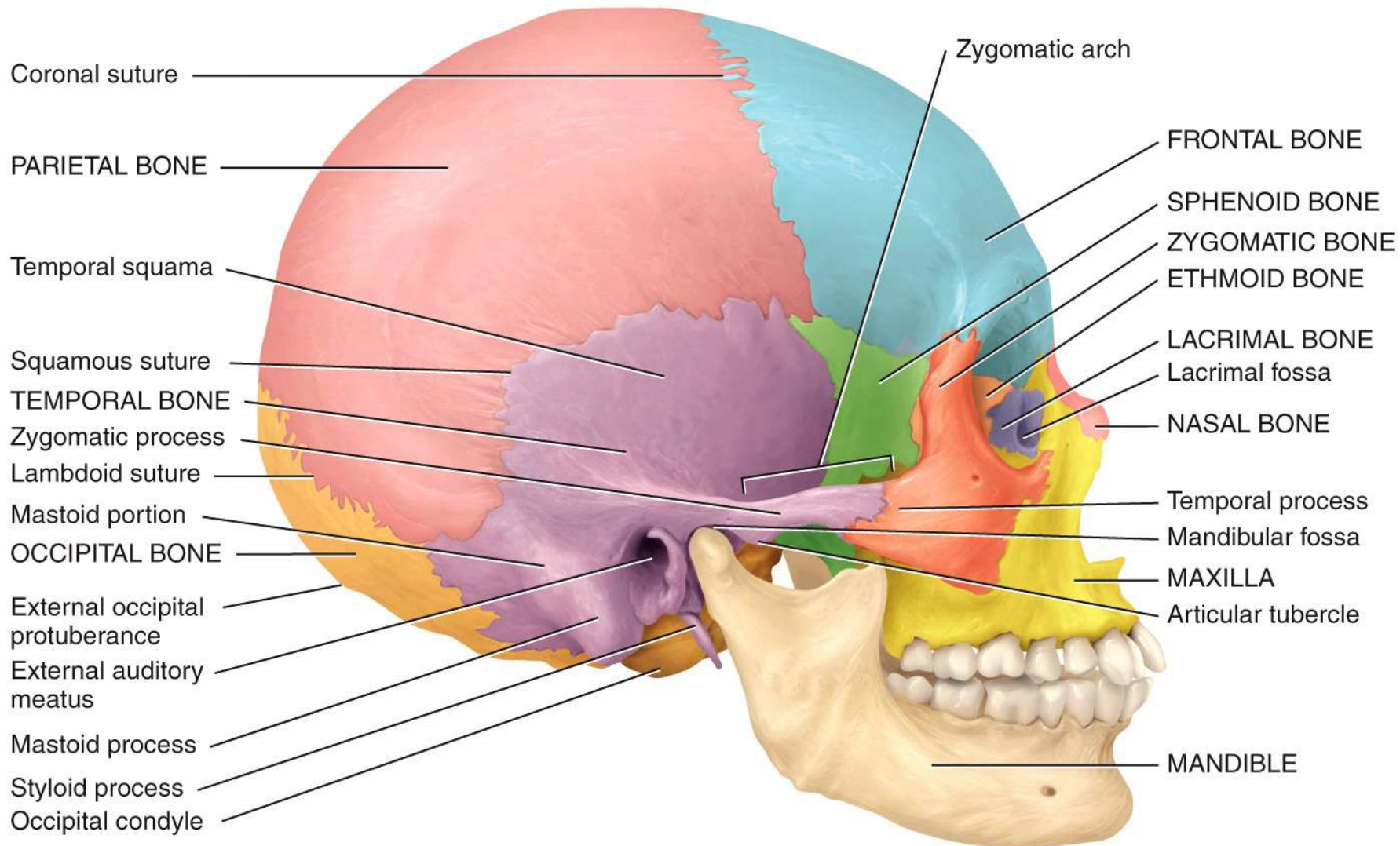
(b) Superior view



Medial view of sagittal section



Posteroinferior view



Coronal suture

PARIETAL BONE

Temporal squama

Squamous suture

TEMPORAL BONE

Zygomatic process

Lambdoid suture

Mastoid portion

OCCIPITAL BONE

External occipital protuberance

External auditory meatus

Mastoid process

Styloid process

Occipital condyle

Zygomatic arch

FRONTAL BONE

SPHENOID BONE

ZYGOMATIC BONE

ETHMOID BONE

LACRIMAL BONE

Lacrimal fossa

NASAL BONE

Temporal process

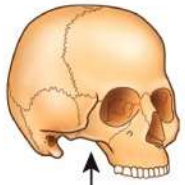
Mandibular fossa

MAXILLA

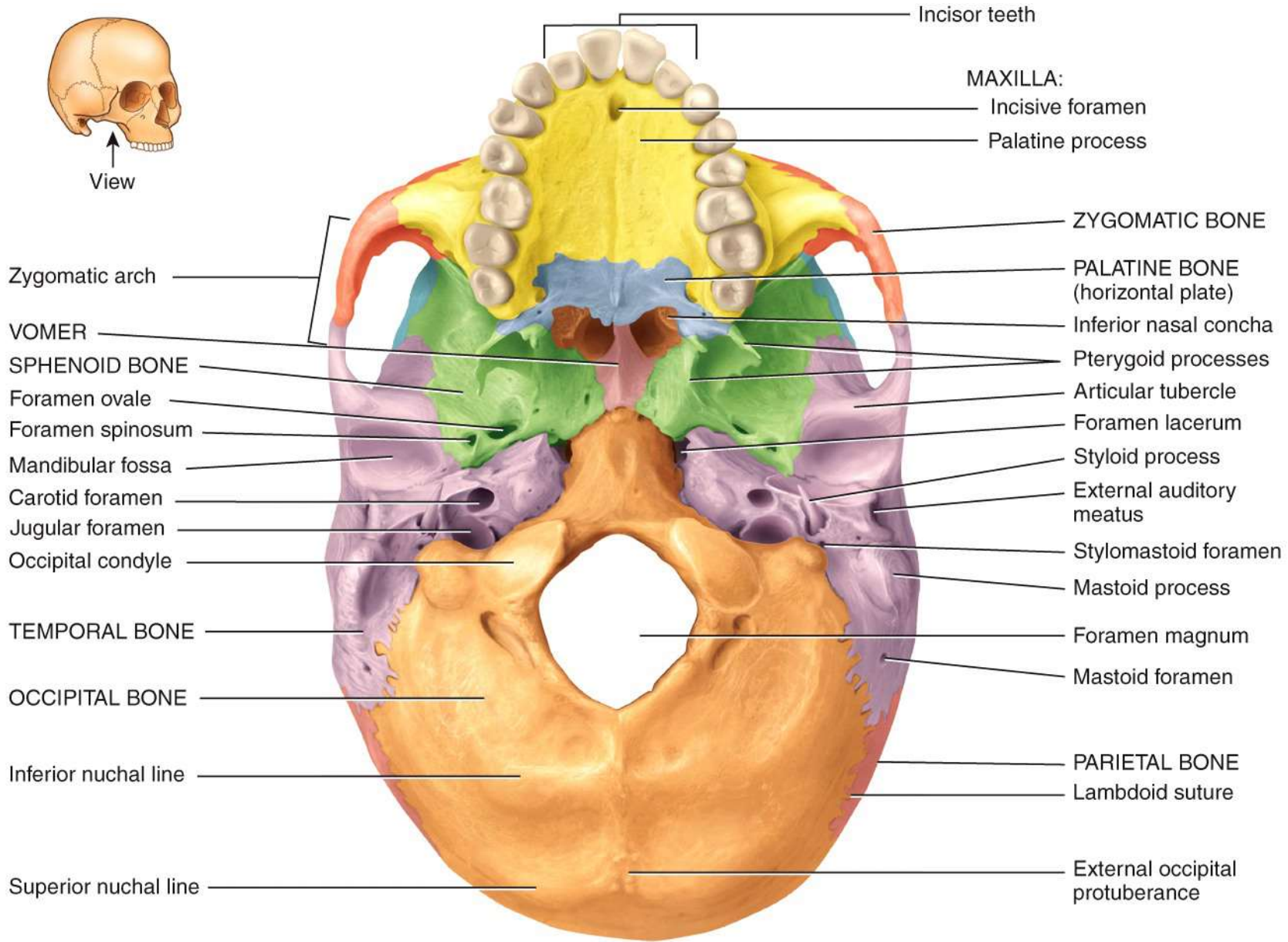
Articular tubercle

MANDIBLE

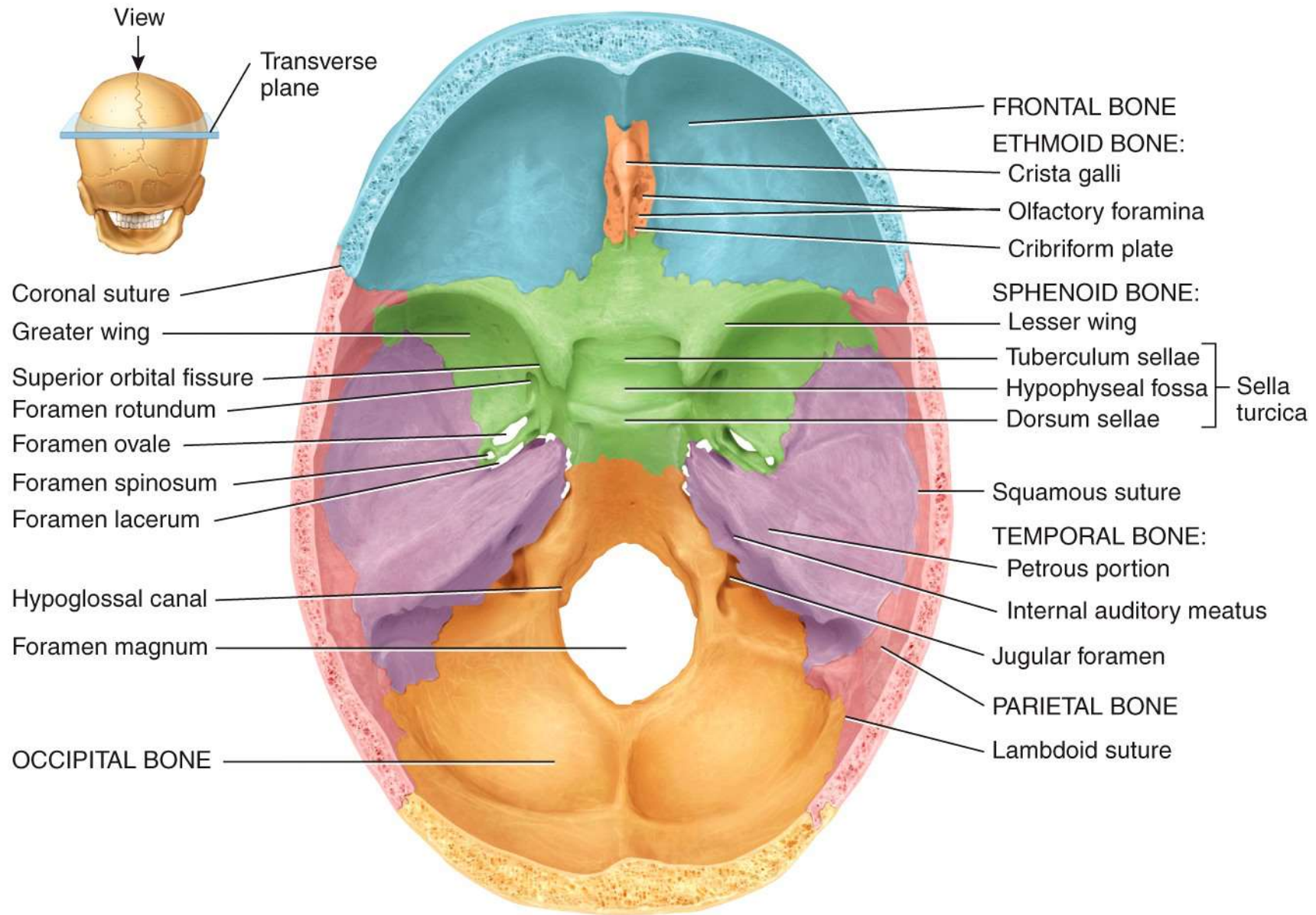
(a) Right lateral view



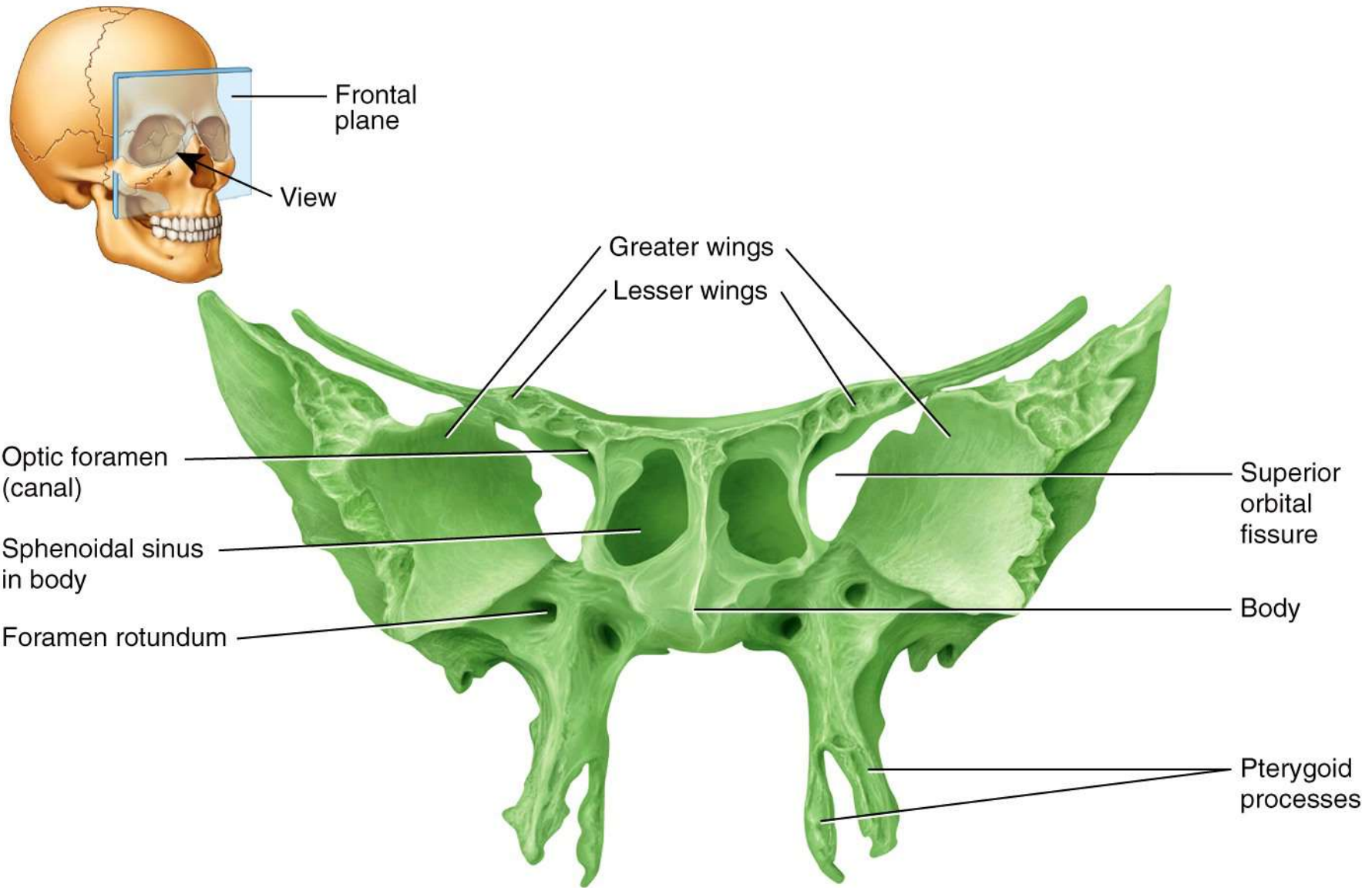
View



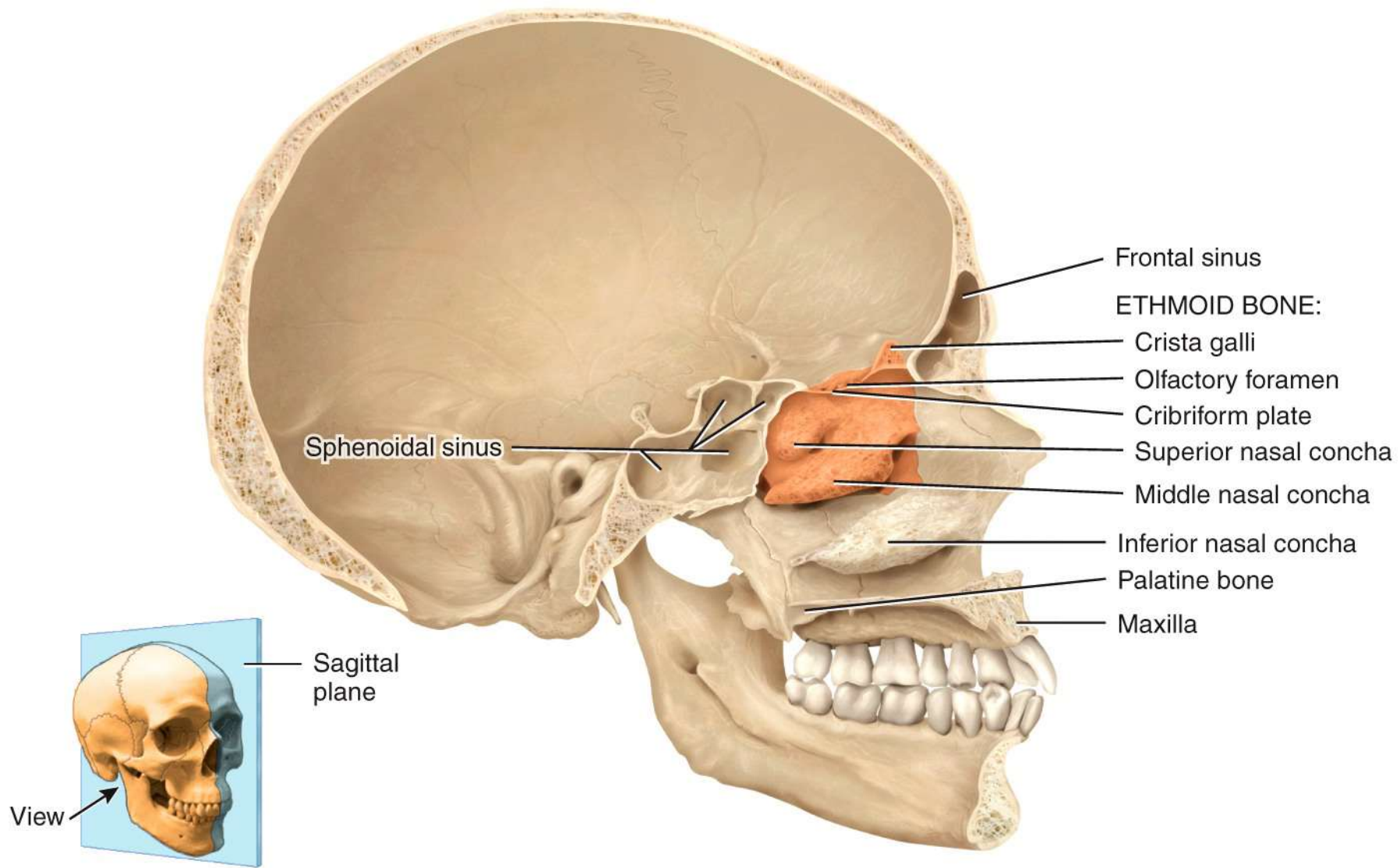
Inferior view



(a) Superior view of sphenoid bone in floor of cranium

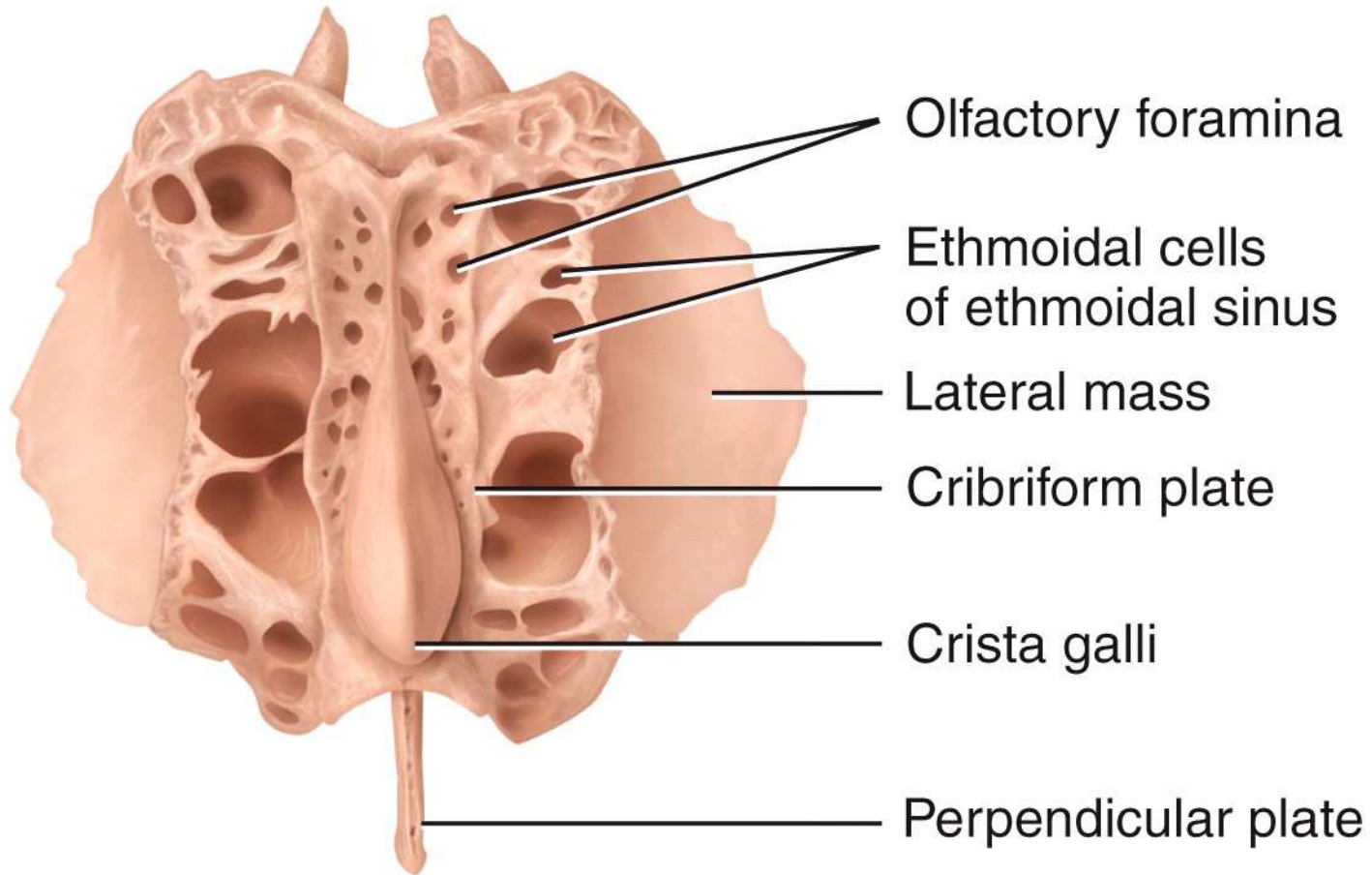


(b) Anterior view of sphenoid bone



(a) Medial view of sagittal section

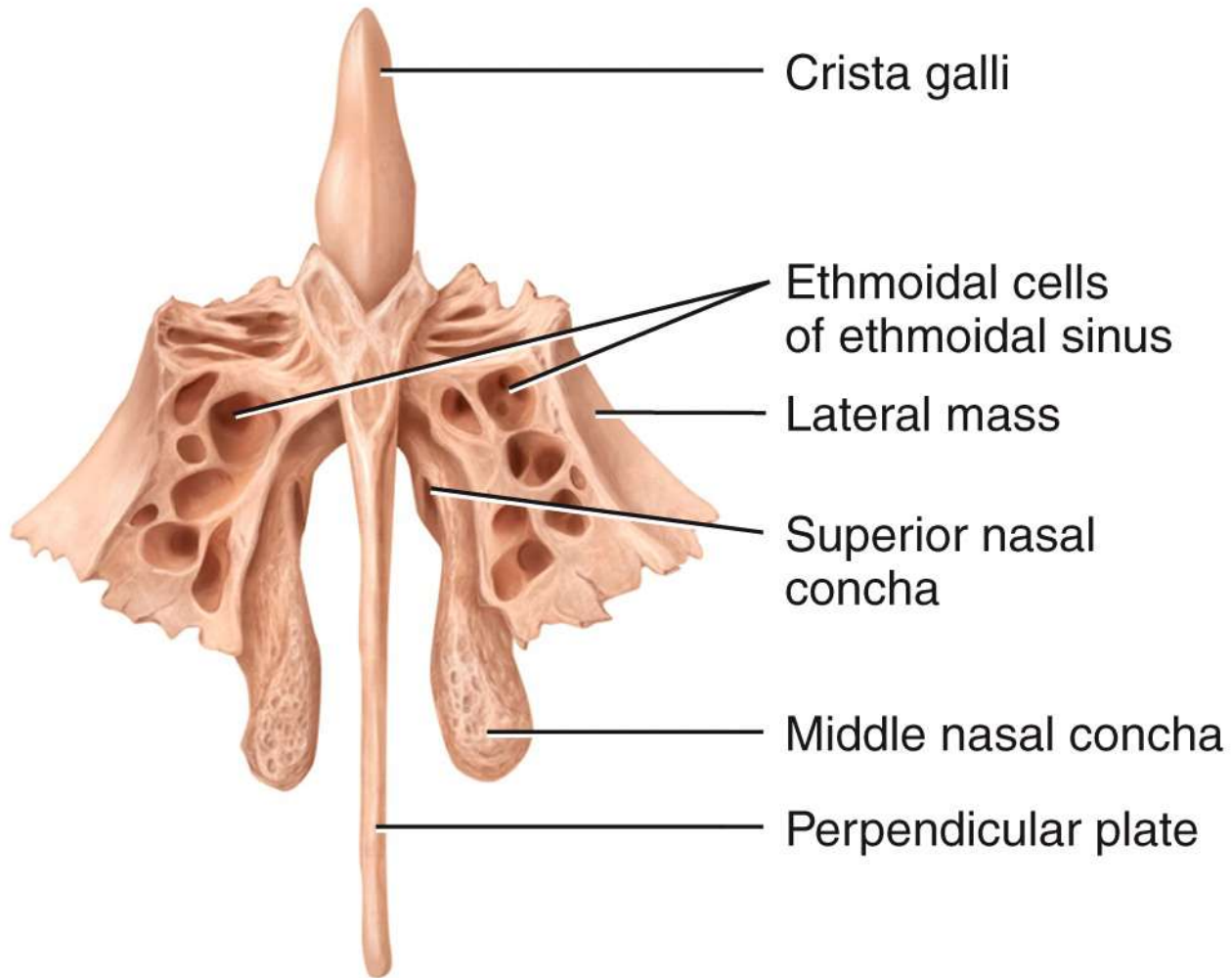
POSTERIOR



ANTERIOR

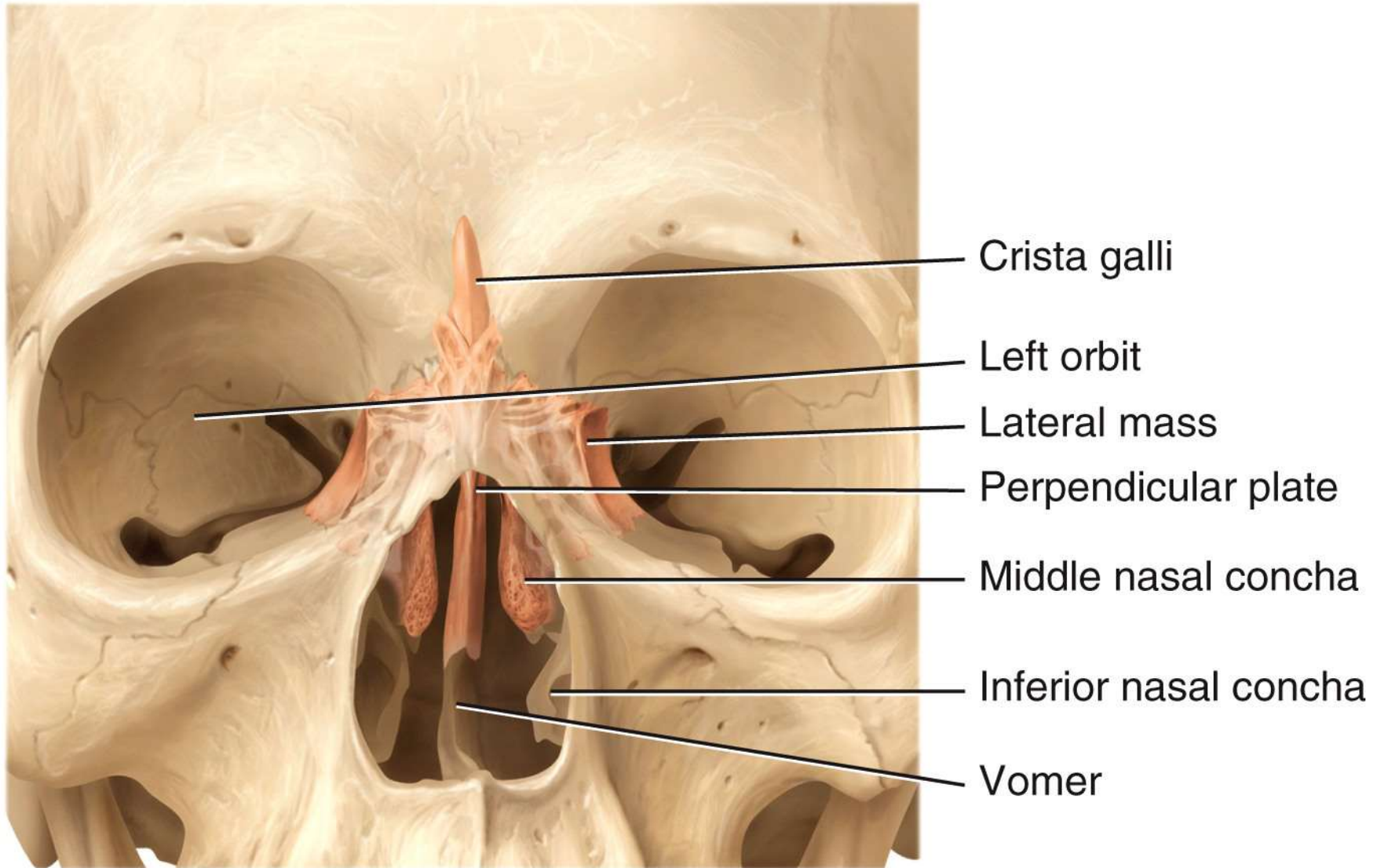
(b) Superior view

SUPERIOR

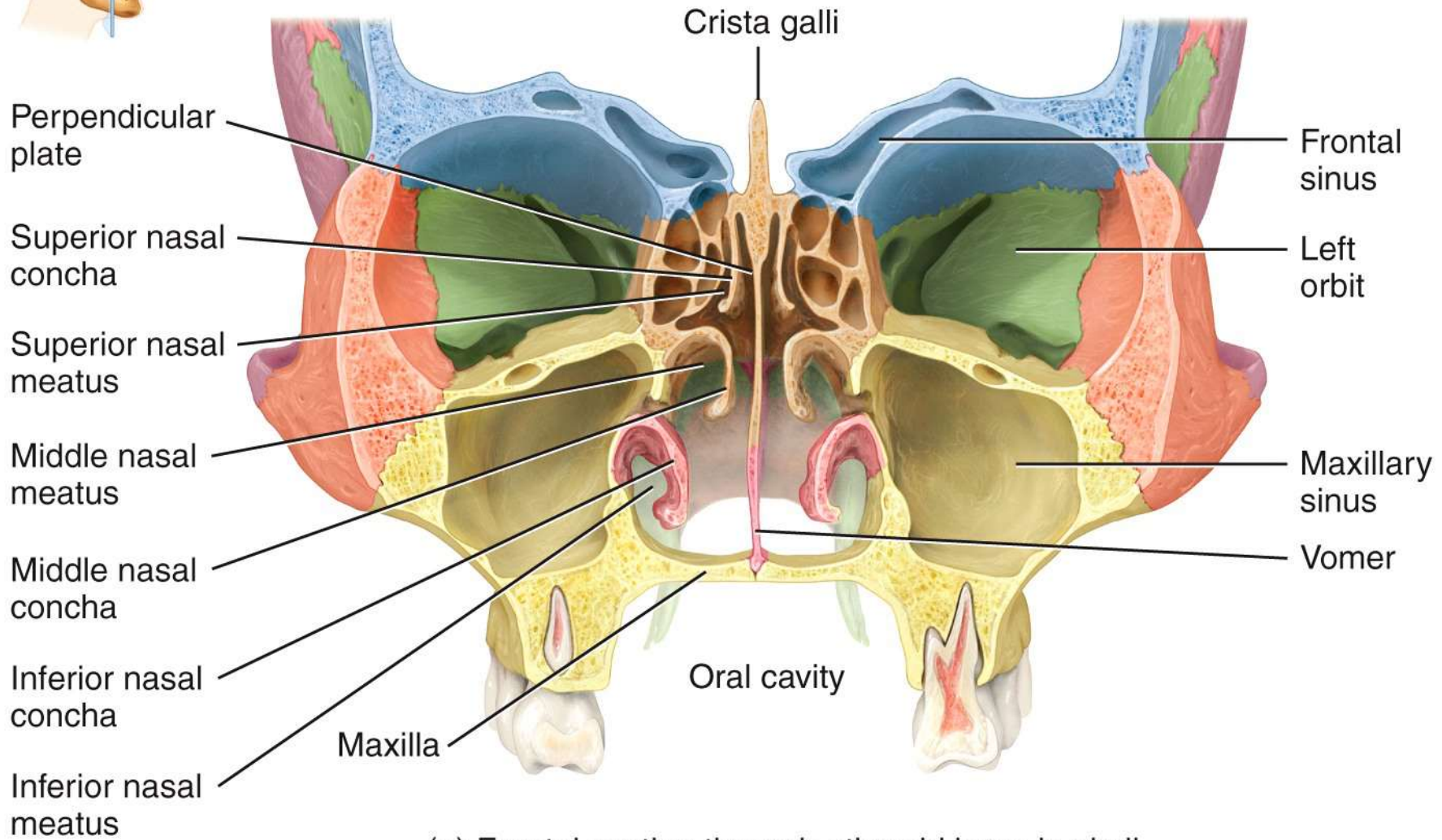
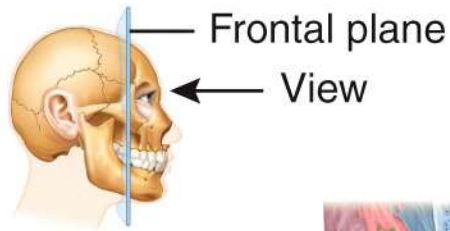


INFERIOR

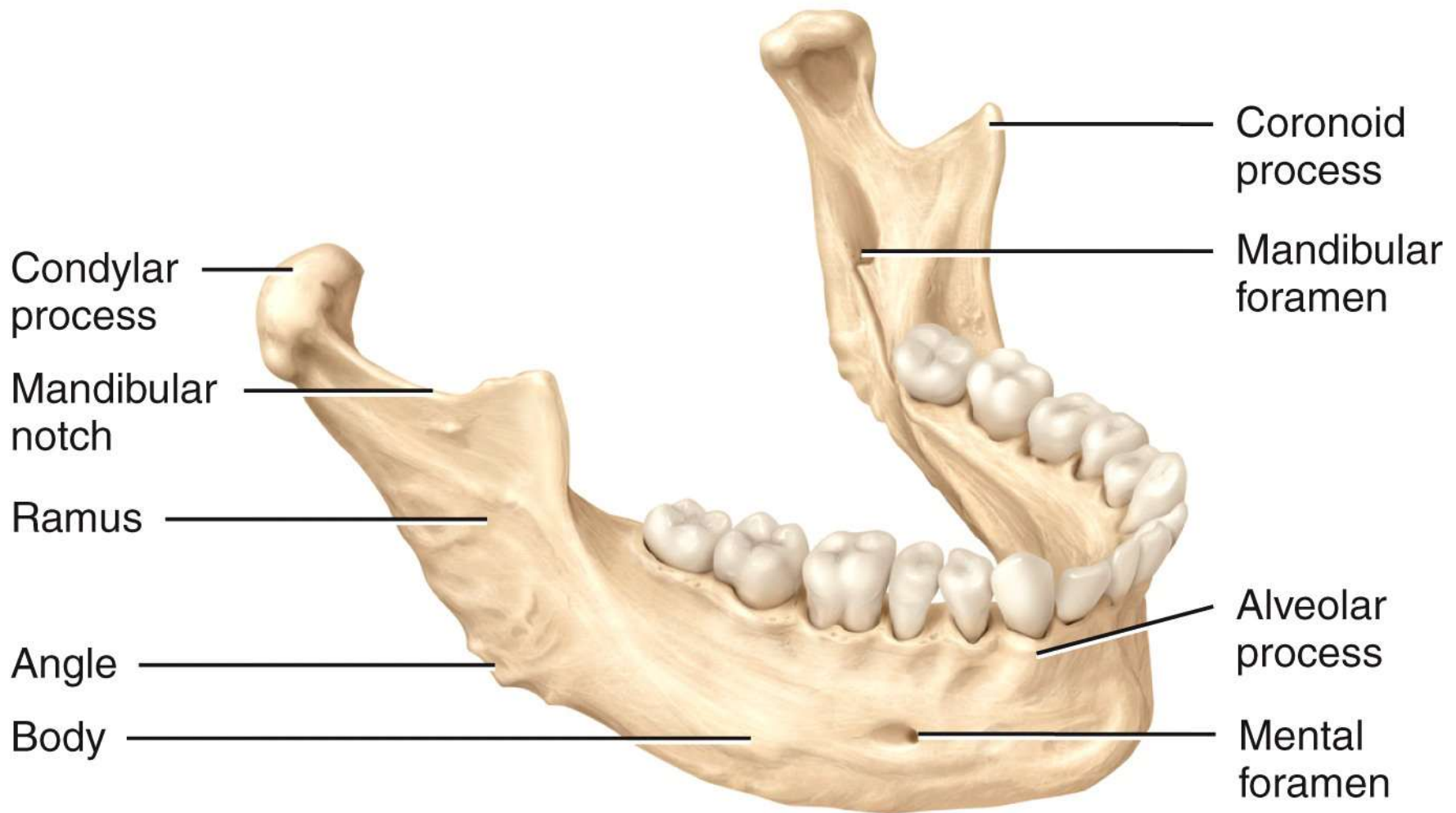
(c) Anterior view



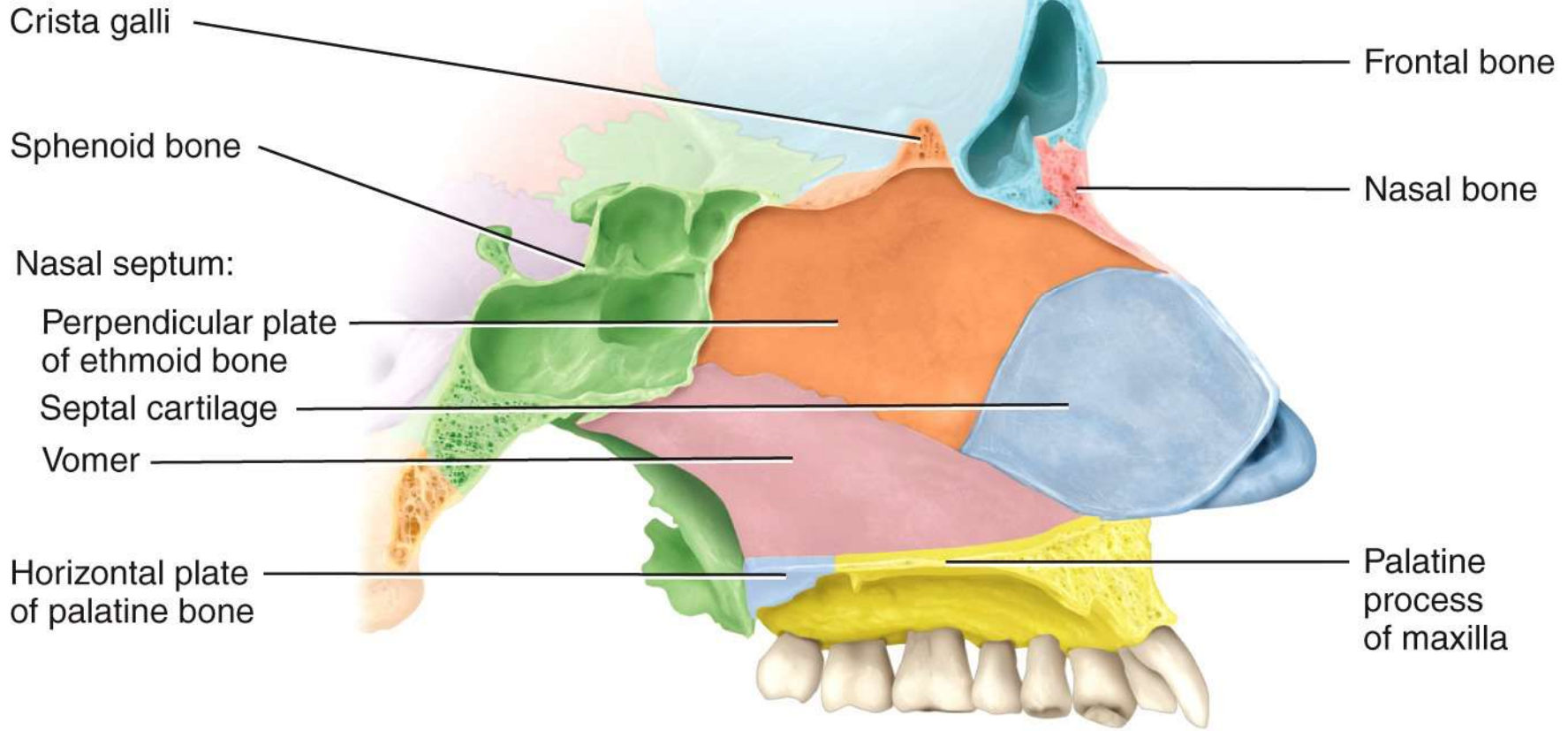
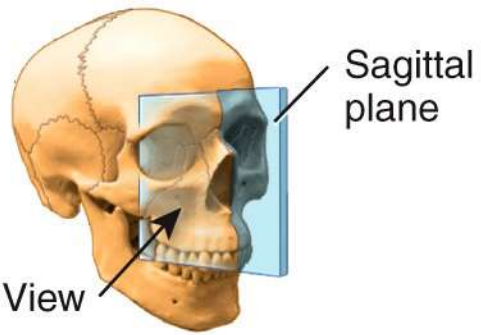
(d) Anterior view of position of ethmoid bone in skull
(projected to the surface)



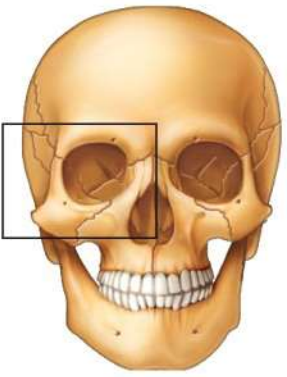
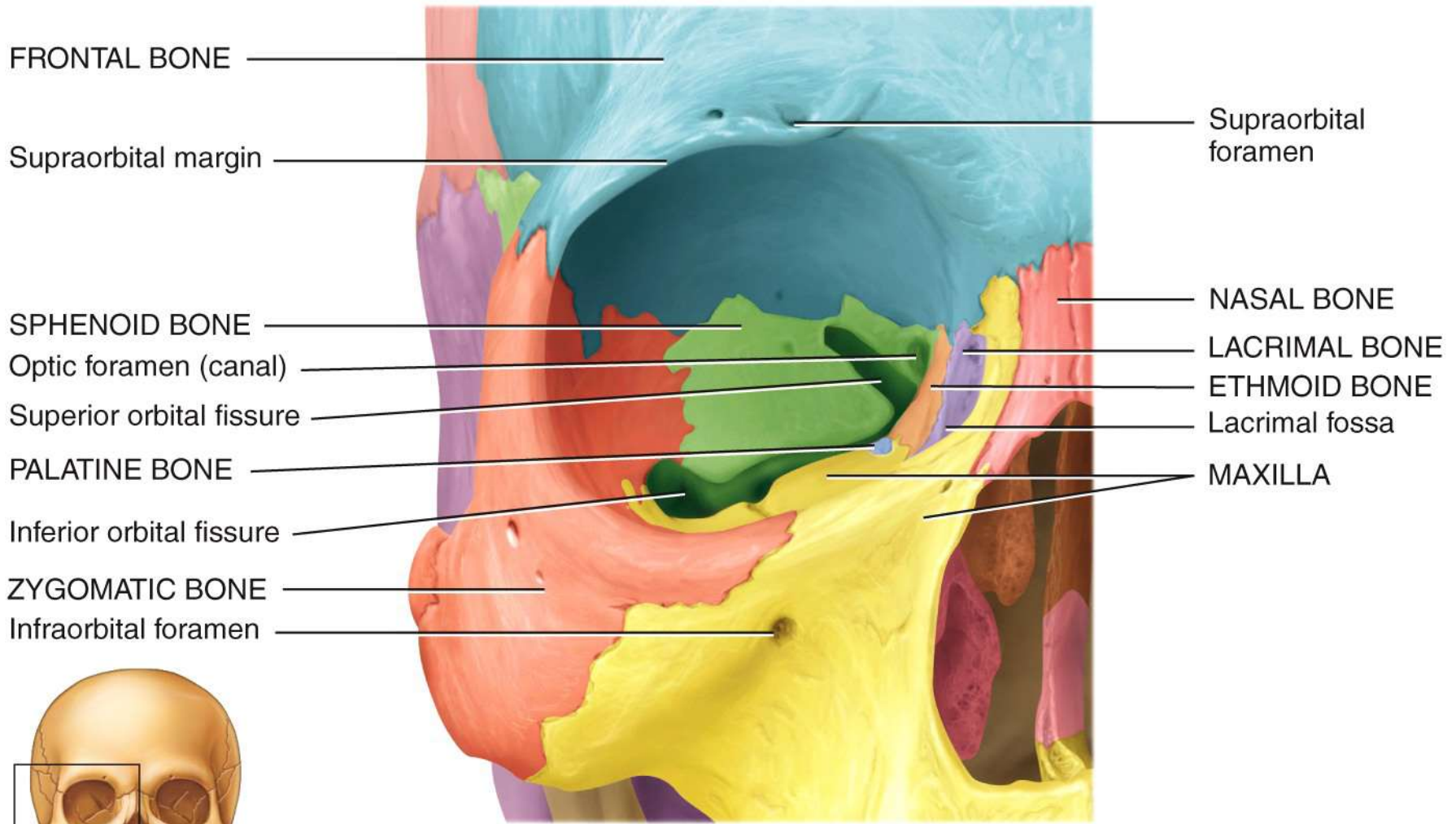
(e) Frontal section through ethmoid bone in skull



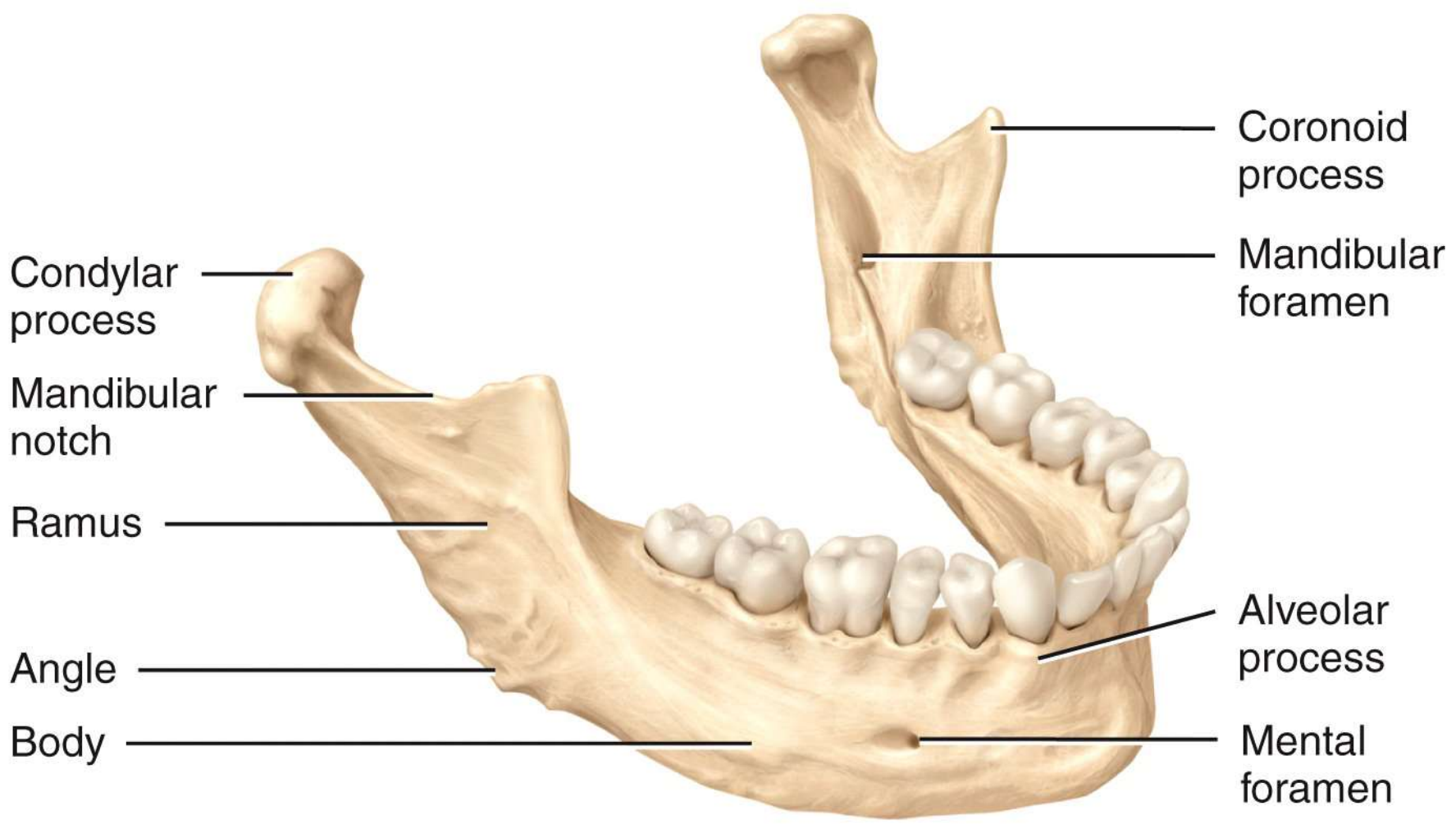
Right lateral view



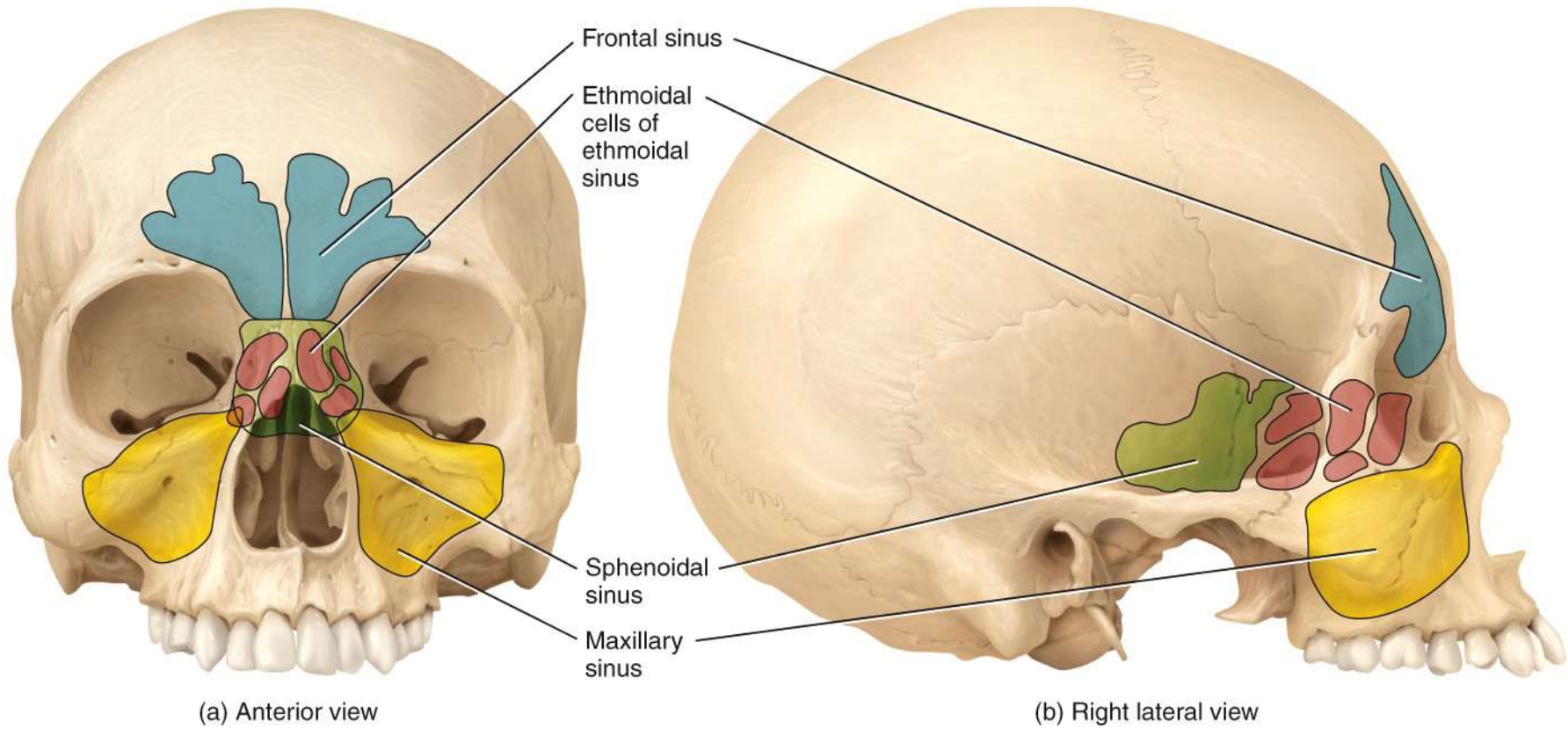
Sagittal section

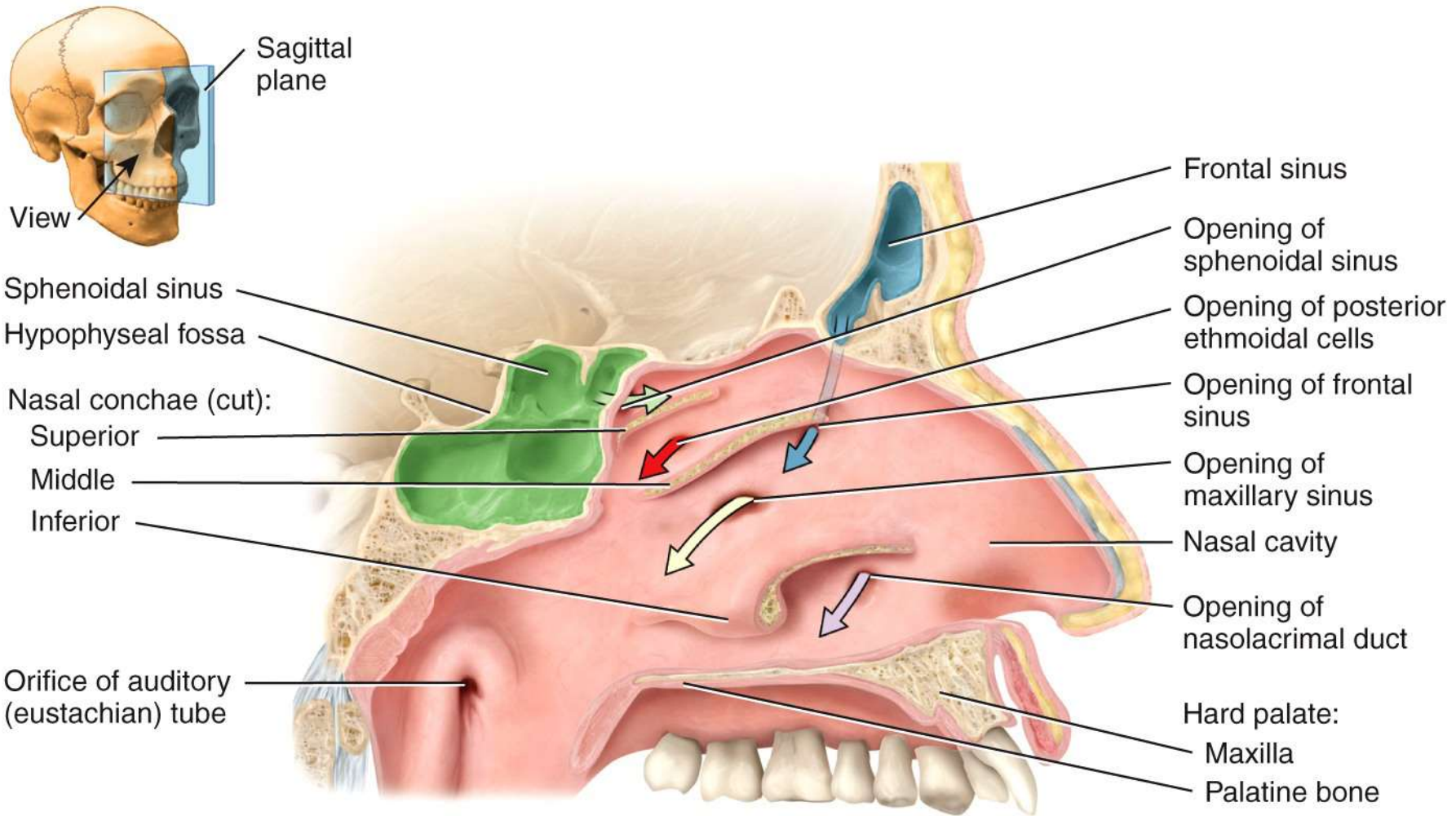


Anterior view showing the bones of the right orbit

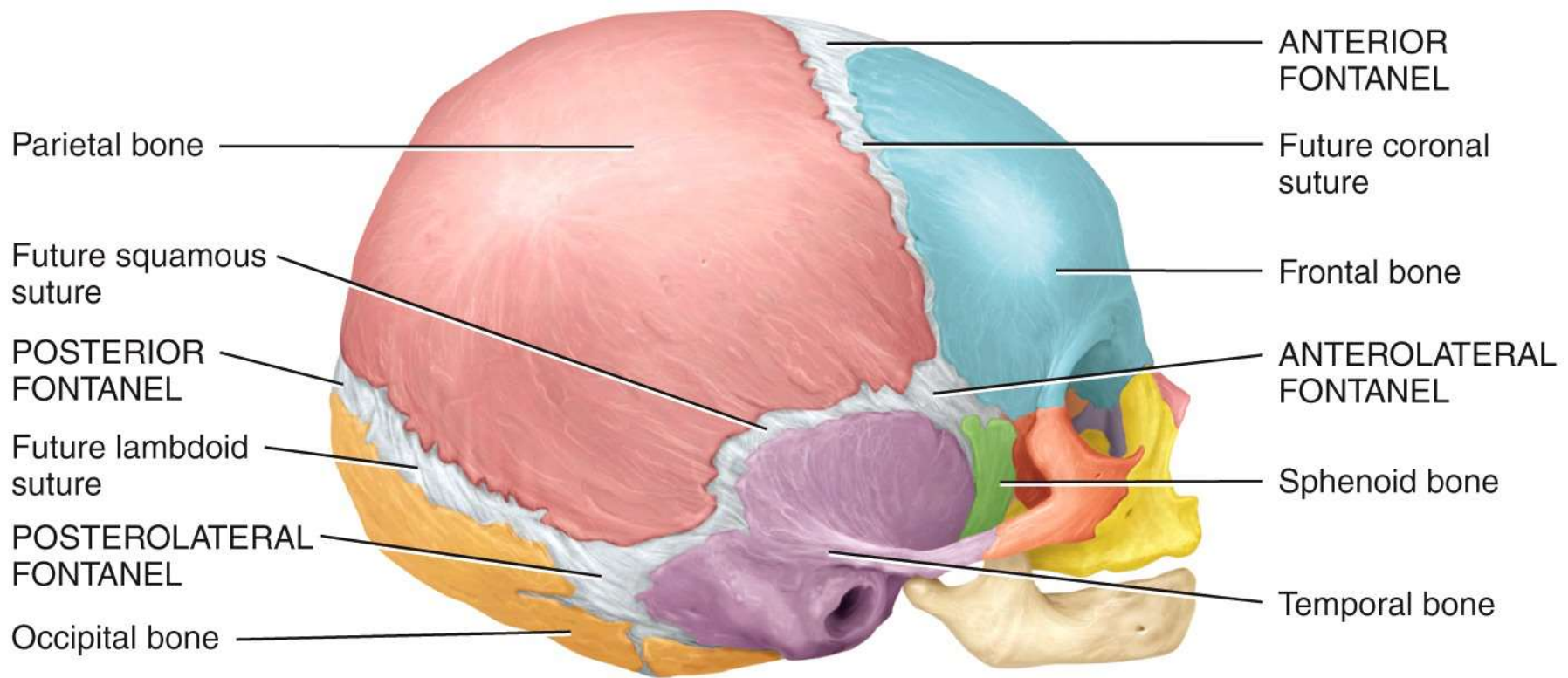


Right lateral view

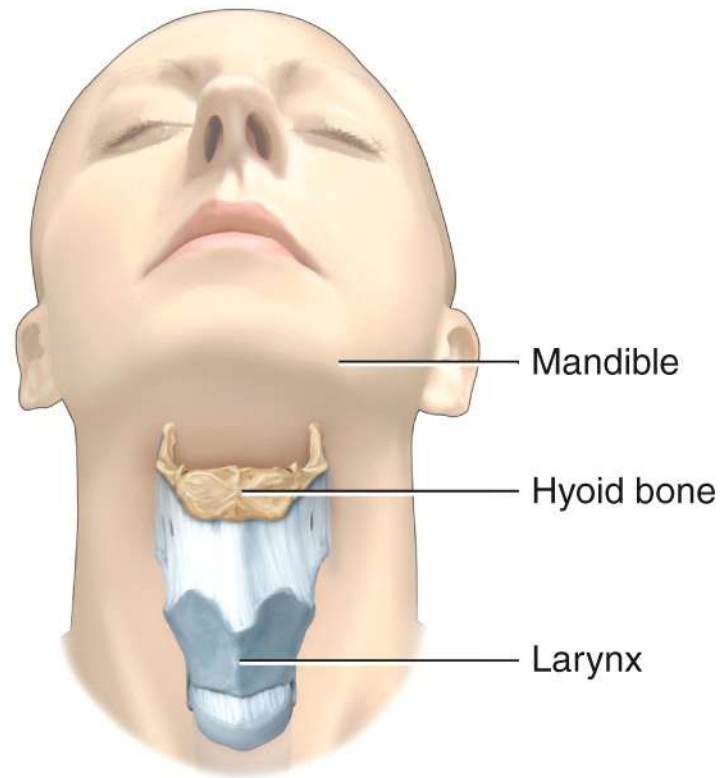




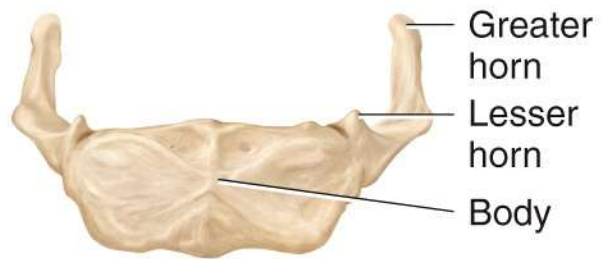
(c) Sagittal section



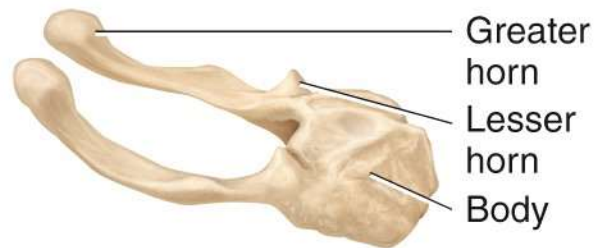
Right lateral view



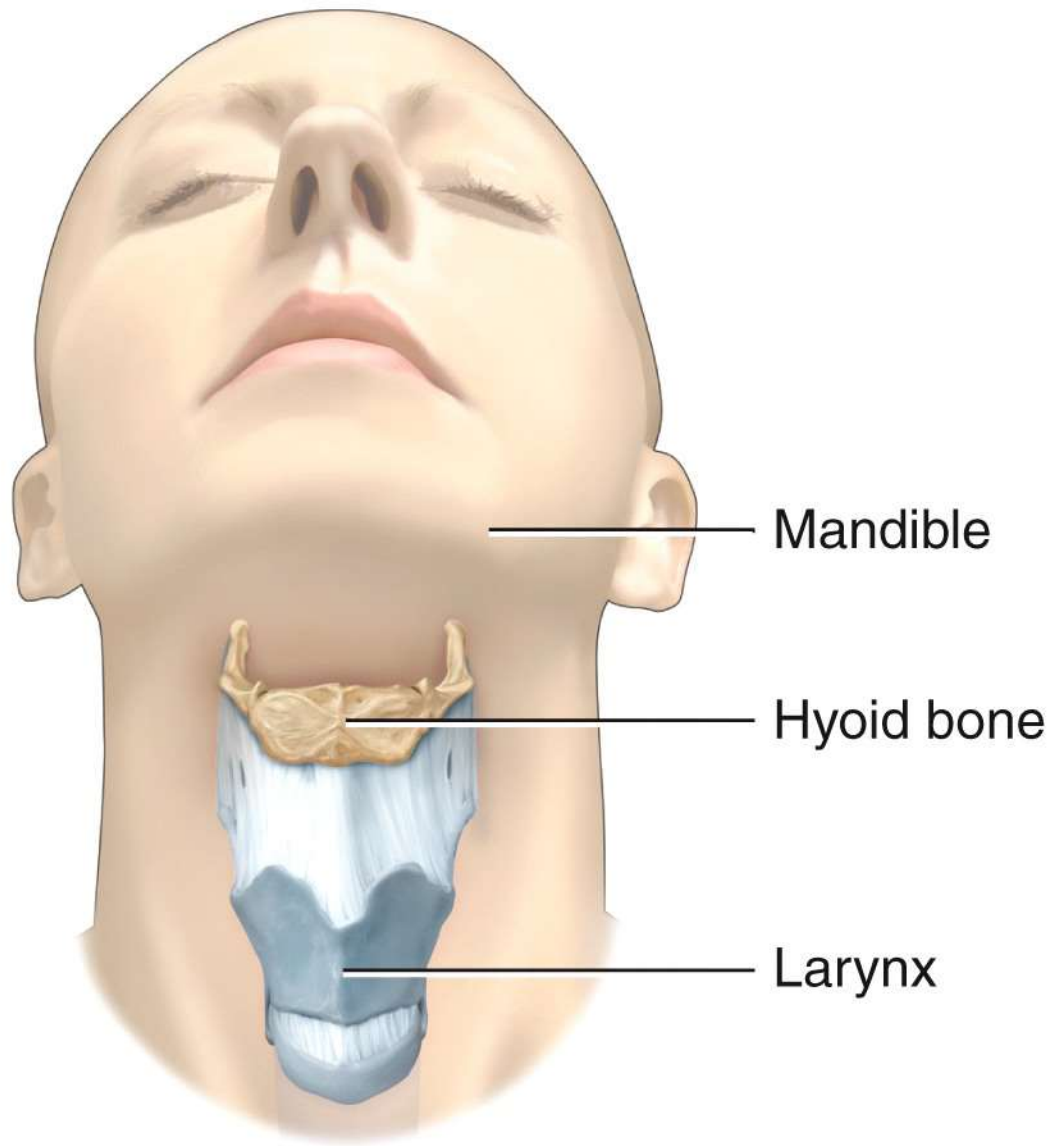
(a) Position of hyoid bone



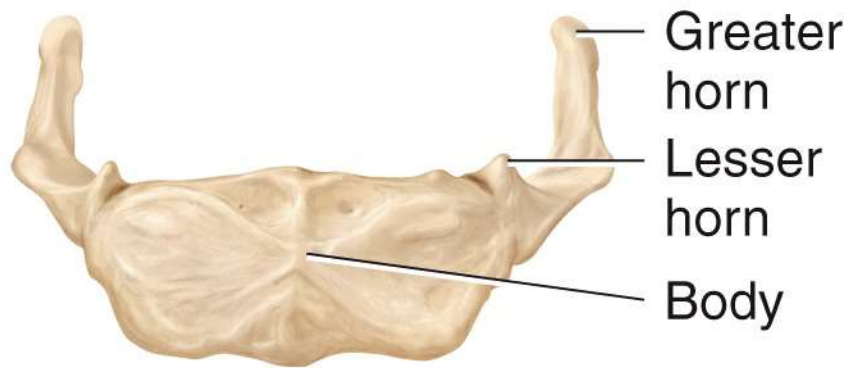
(b) Anterior view



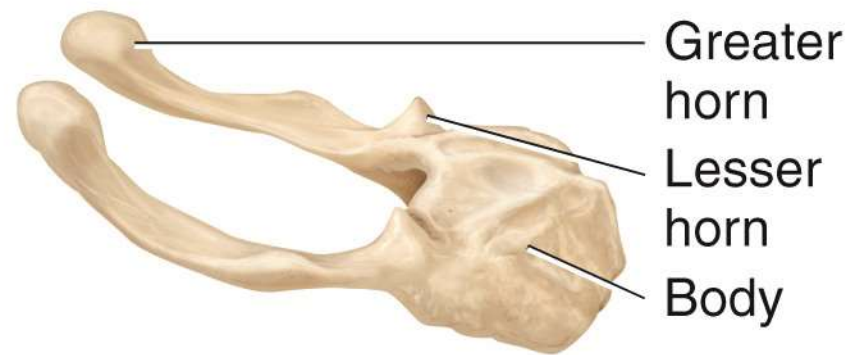
(c) Right lateral view



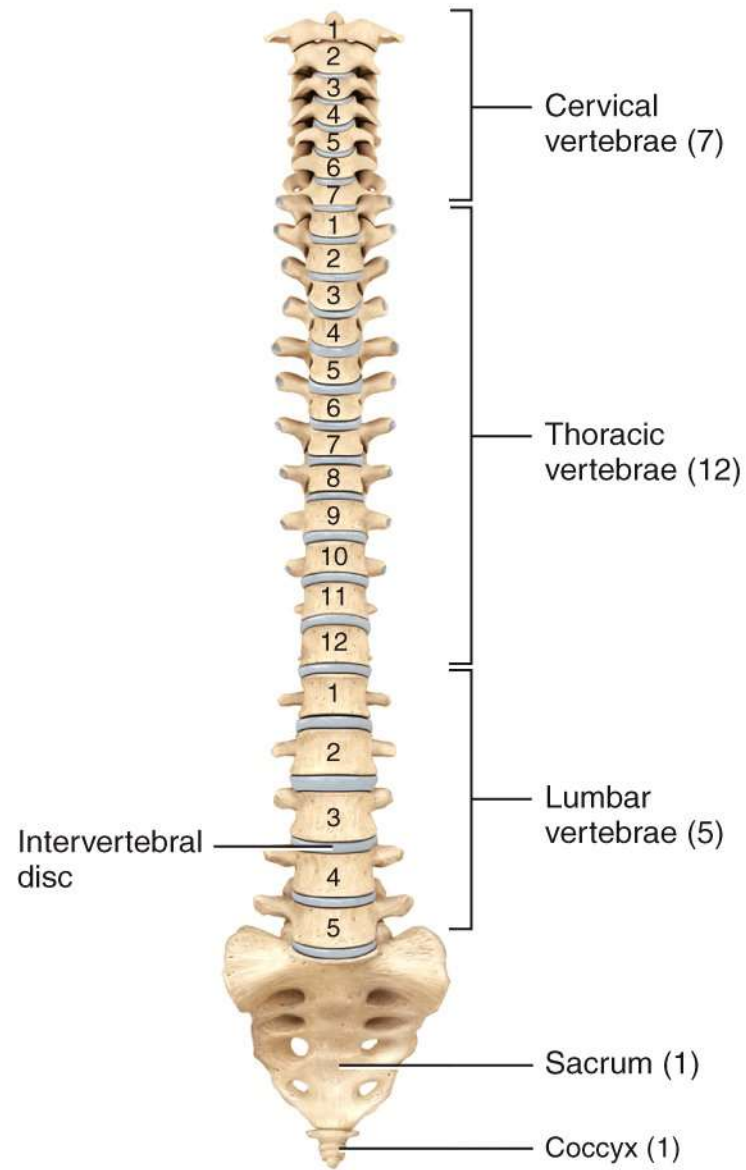
(a) Position of hyoid bone



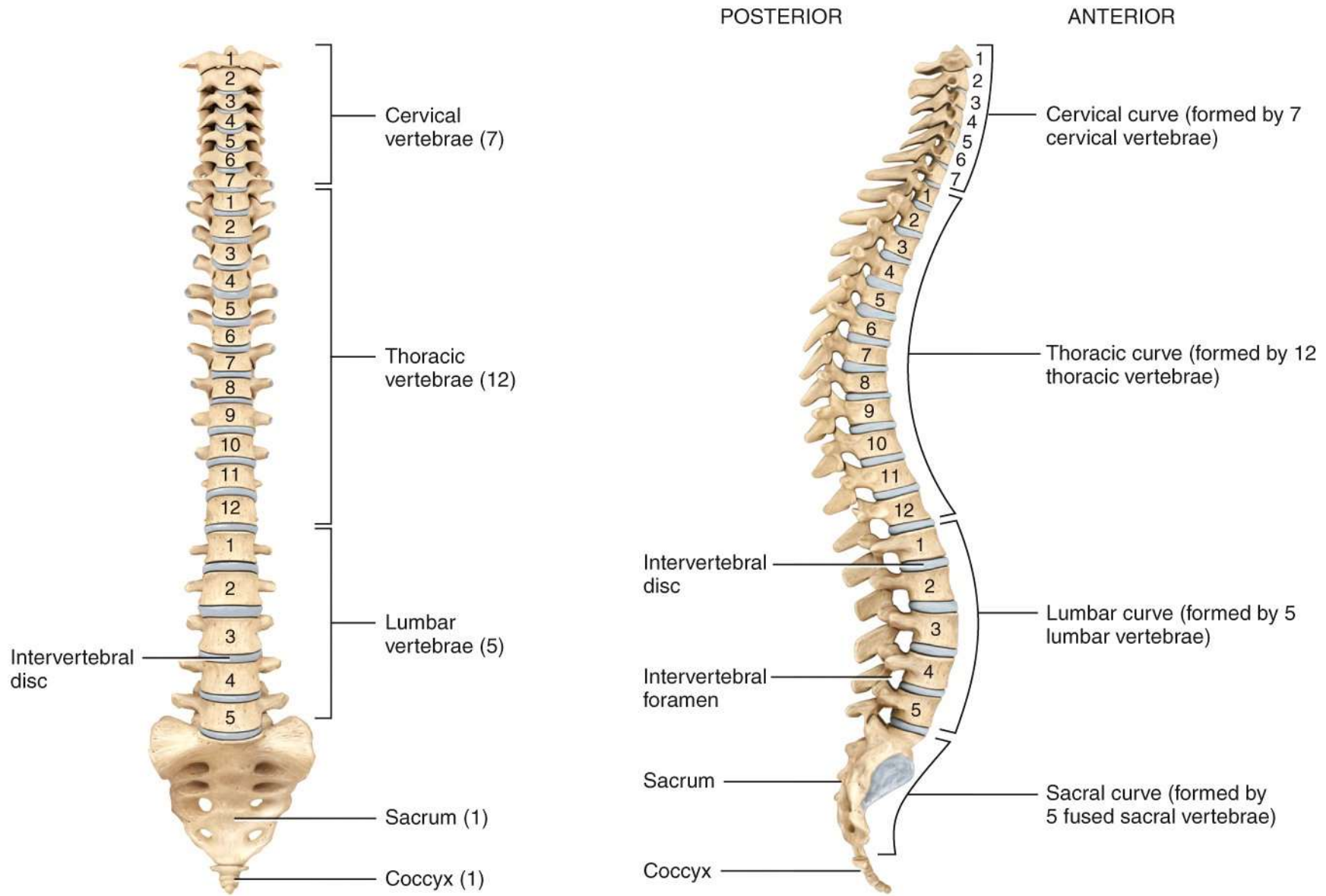
(b) Anterior view



(c) Right lateral view

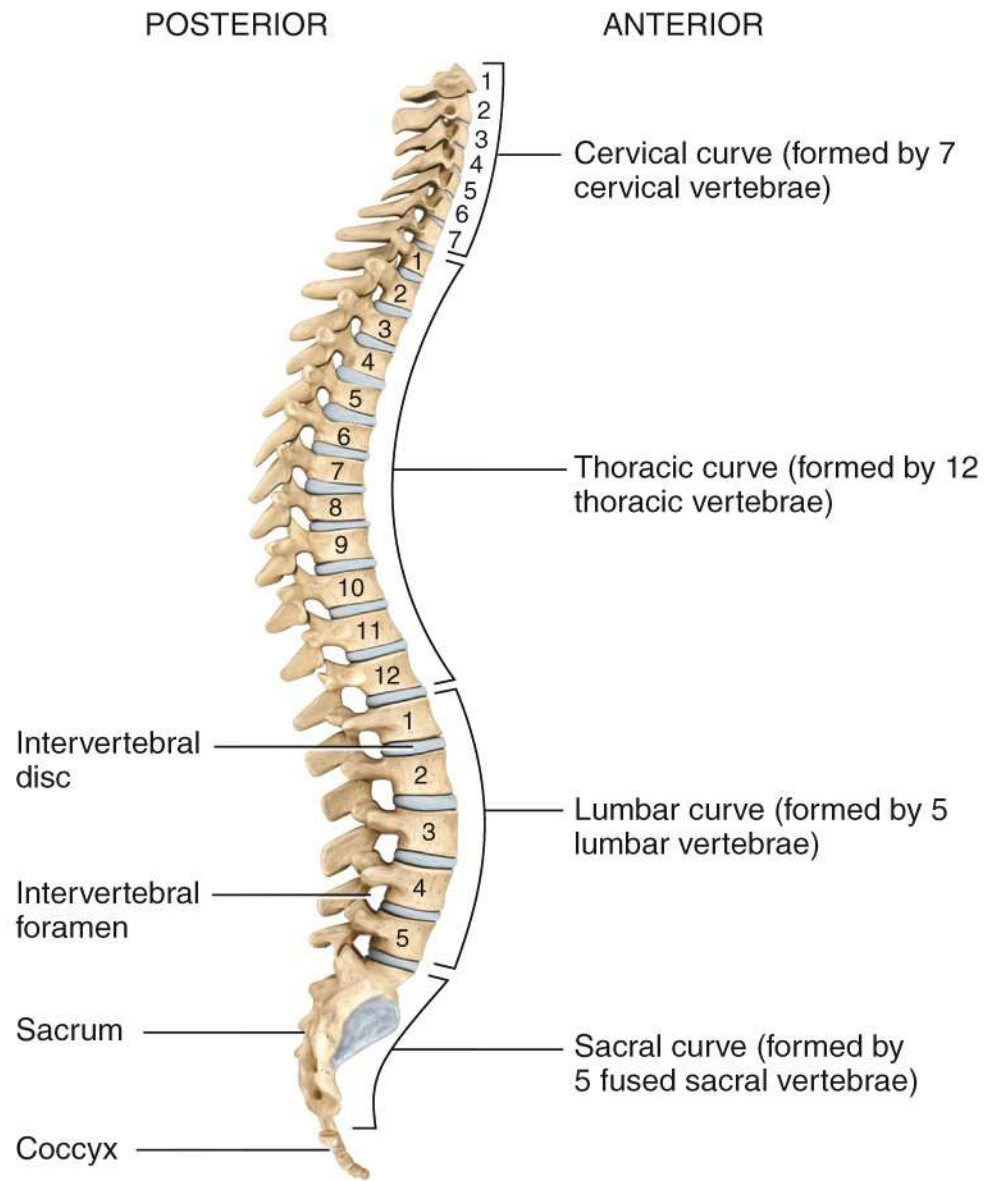


(a) Anterior view showing regions of the vertebral column

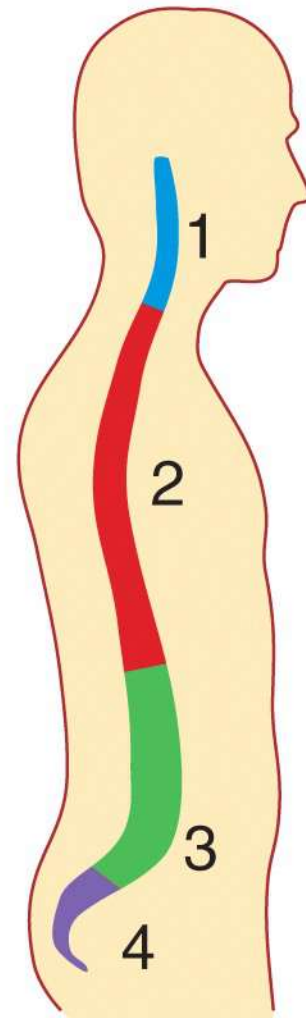
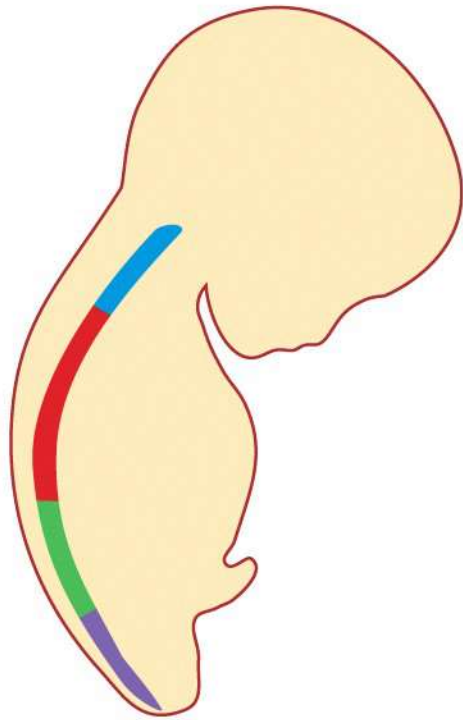


(a) Anterior view showing regions of the vertebral column

(b) Right lateral view showing four normal curves

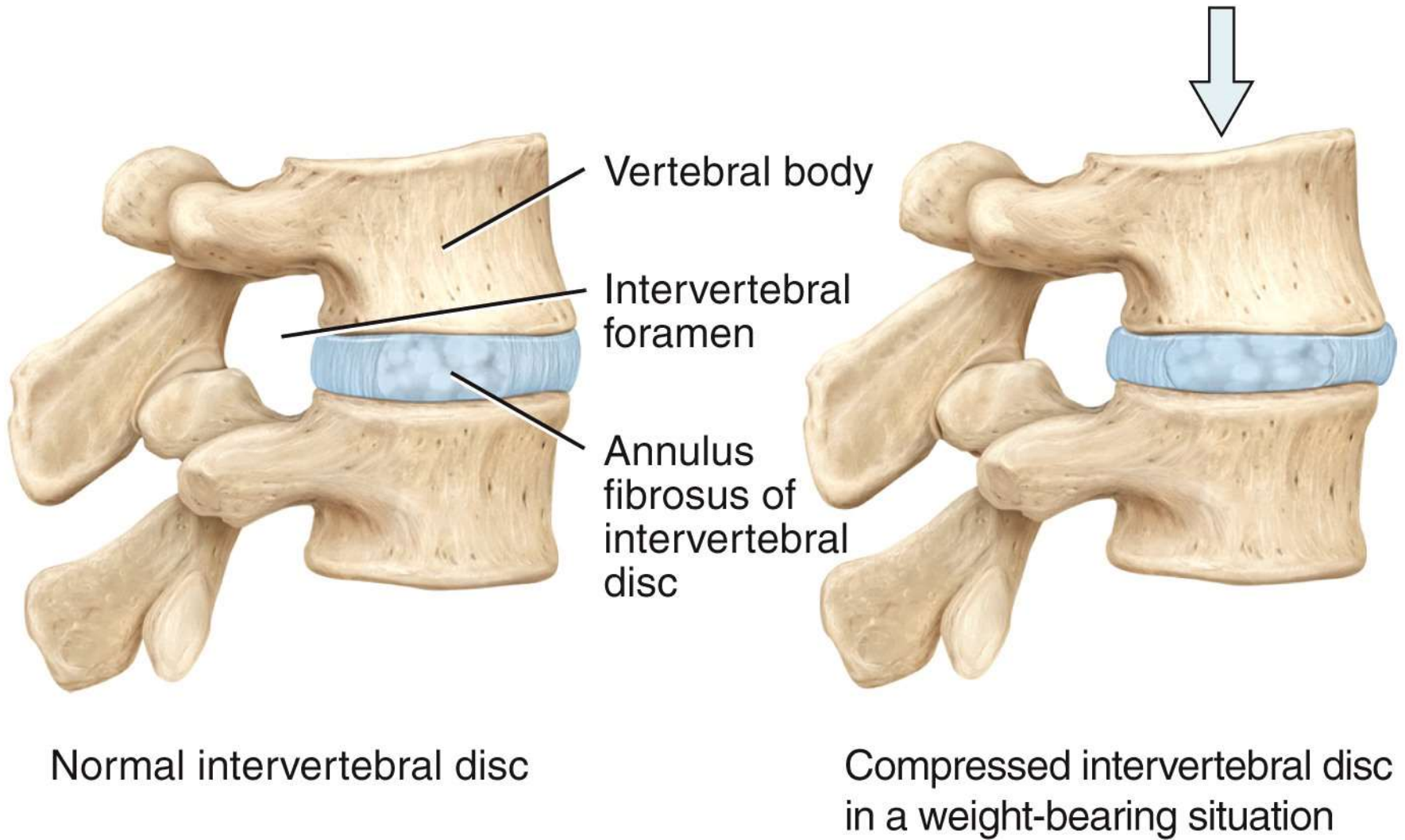


(b) Right lateral view showing four normal curves



Single curve in fetus Four curves in adult

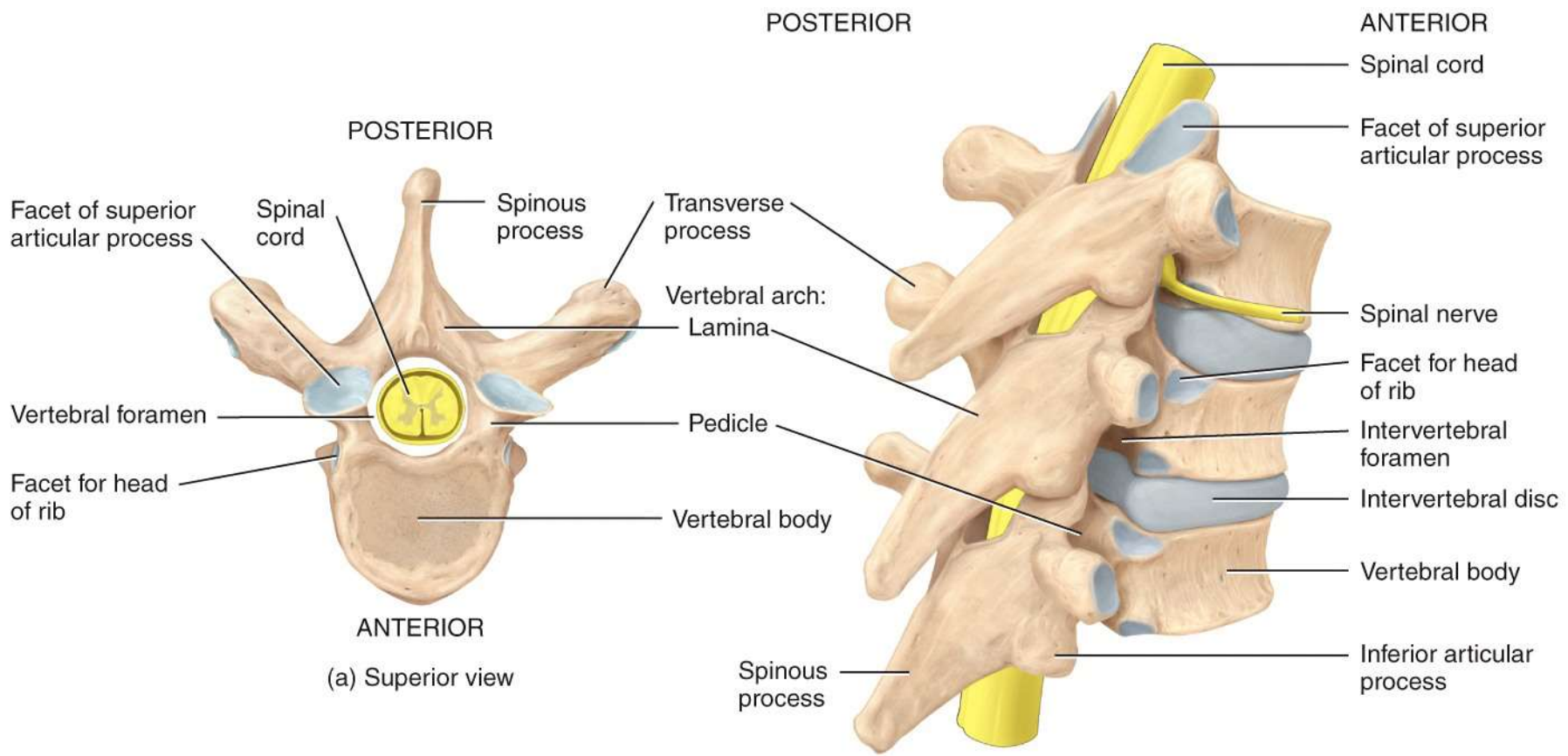
(c) Fetal and adult curves



Normal intervertebral disc

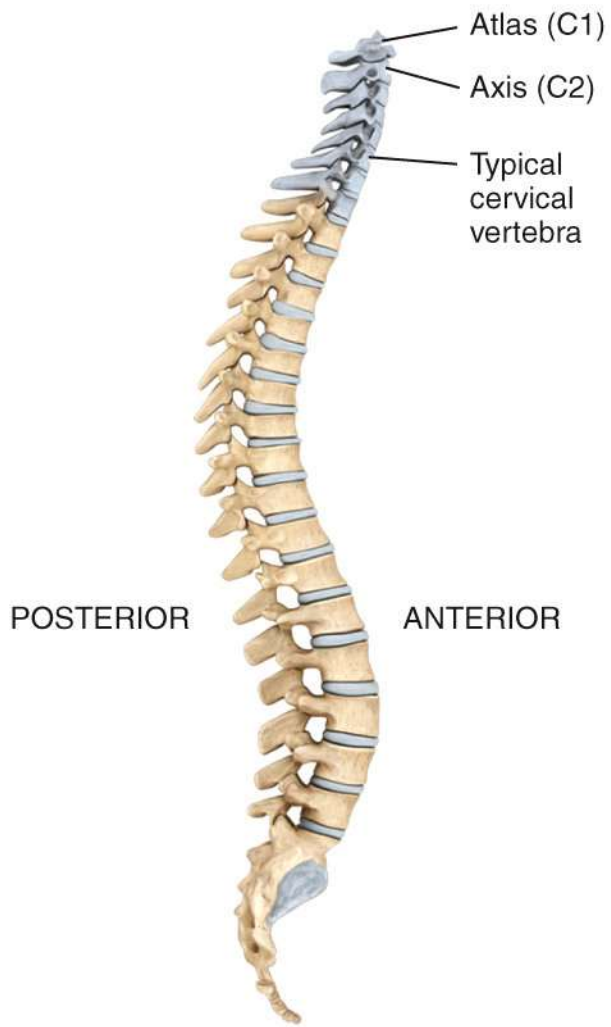
Compressed intervertebral disc
in a weight-bearing situation

(d) Intervertebral disc

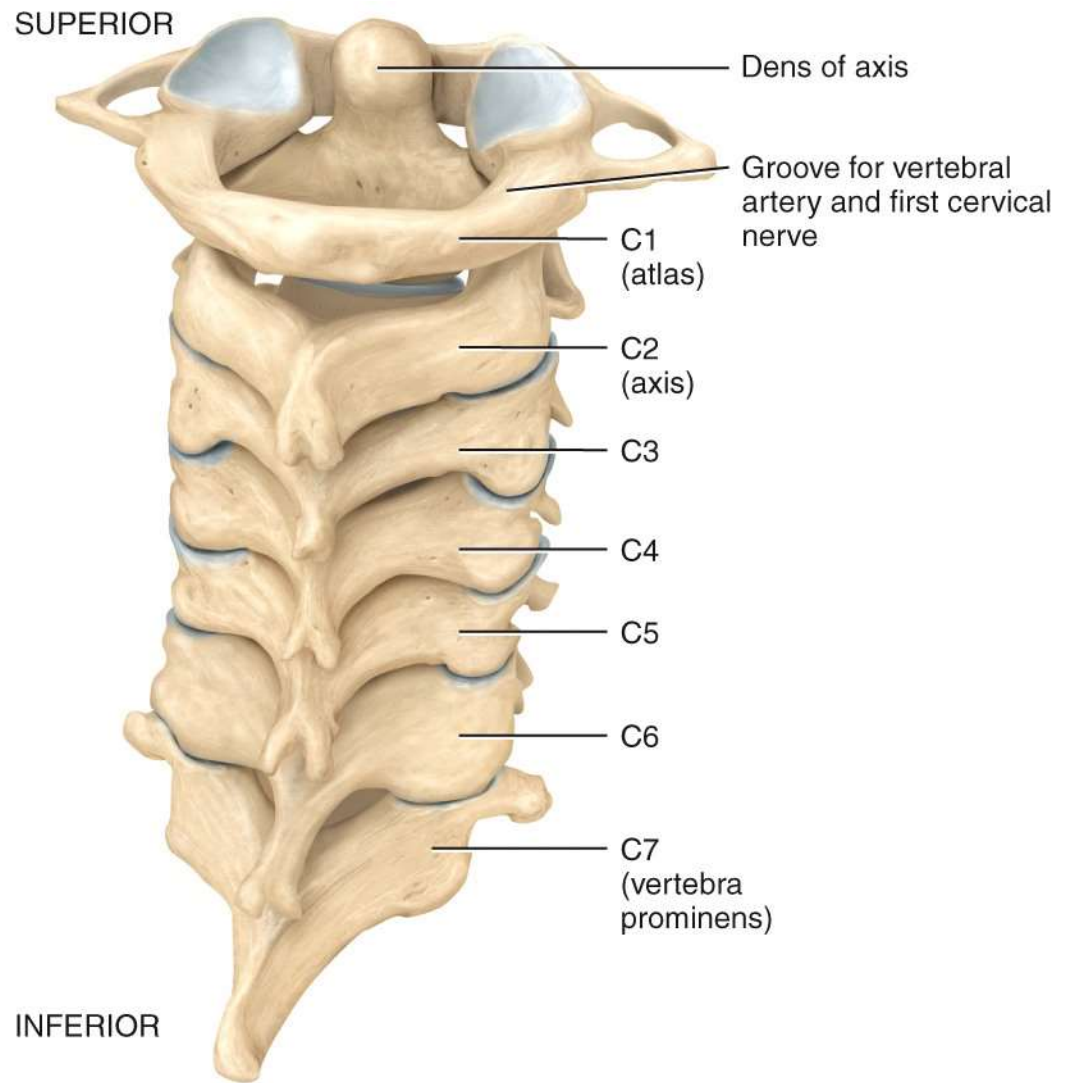


(a) Superior view

(b) Right posterolateral view of articulated vertebrae



Location of cervical vertebrae



(a) Posterior view of articulated cervical vertebrae

POSTERIOR

Posterior arch

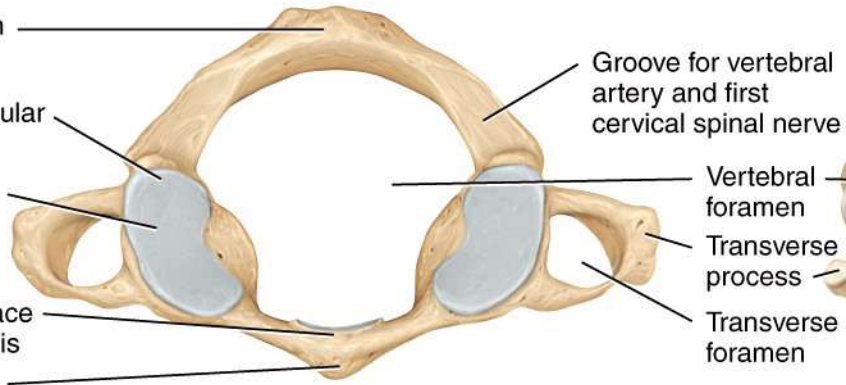
Superior articular facet

Lateral mass

Articular surface for dens of axis

Anterior arch

ANTERIOR



(b) Superior view of atlas (C1)

Groove for vertebral artery and first cervical spinal nerve

Vertebral foramen

Transverse process

Transverse foramen

Lamina

POSTERIOR

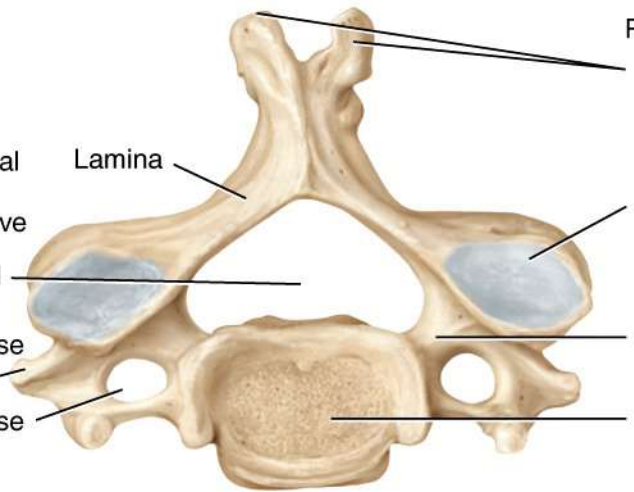
Bifid spinous process

Superior articular facet

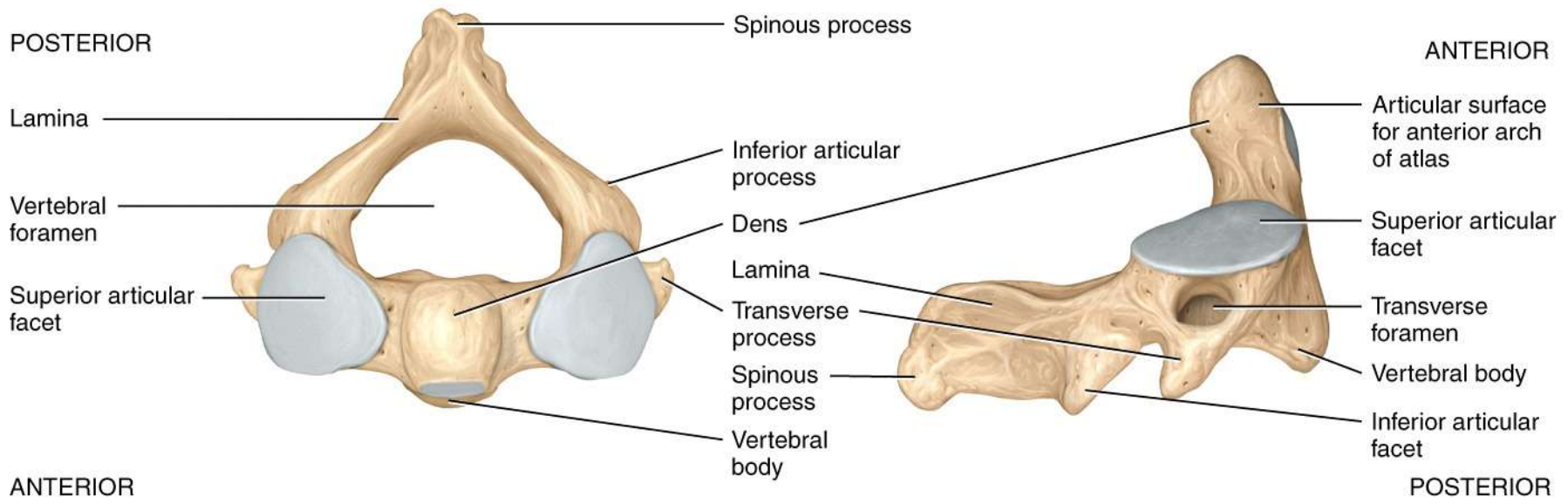
Pedicle

Vertebral body

ANTERIOR

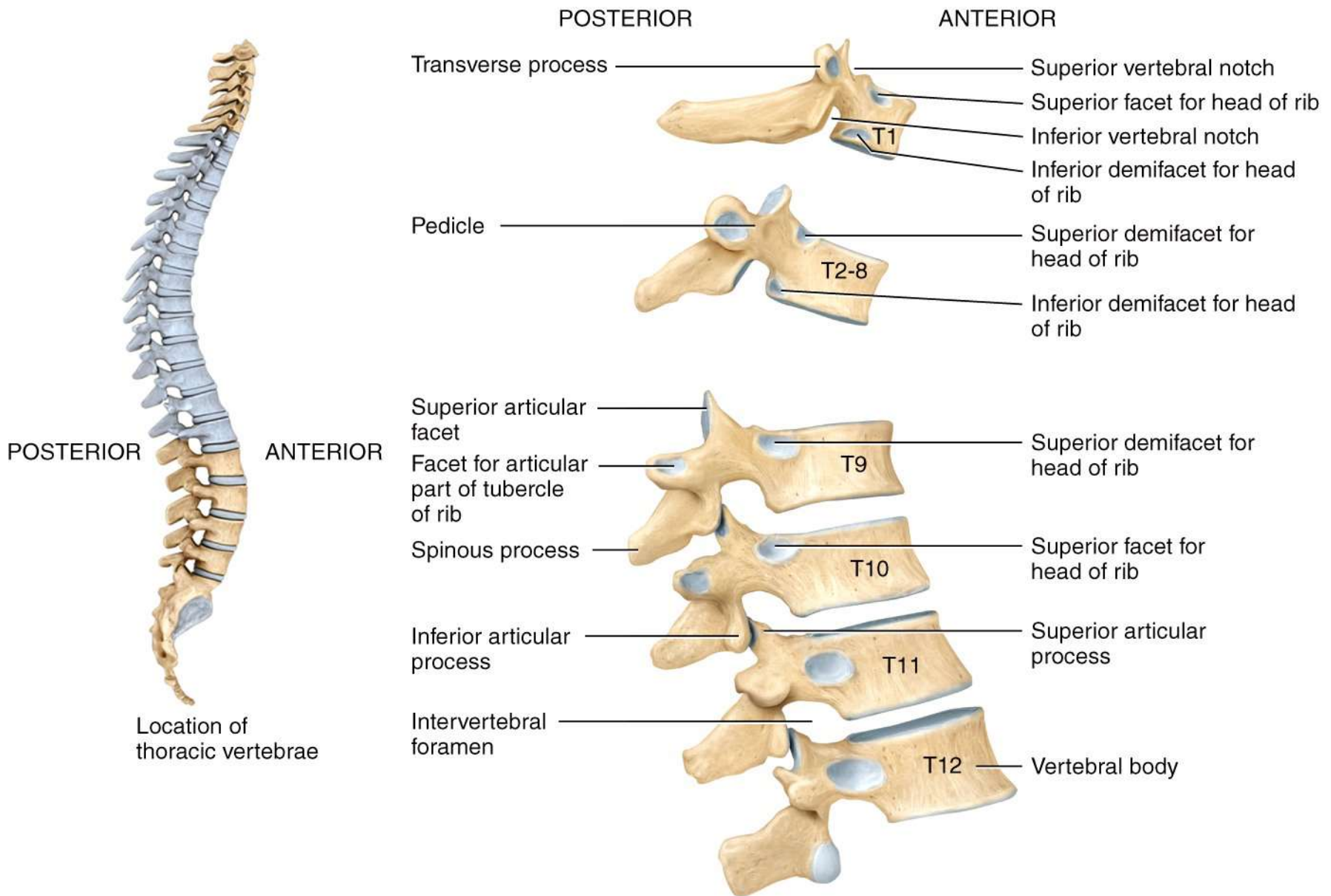


(c) Superior view of a typical cervical vertebra

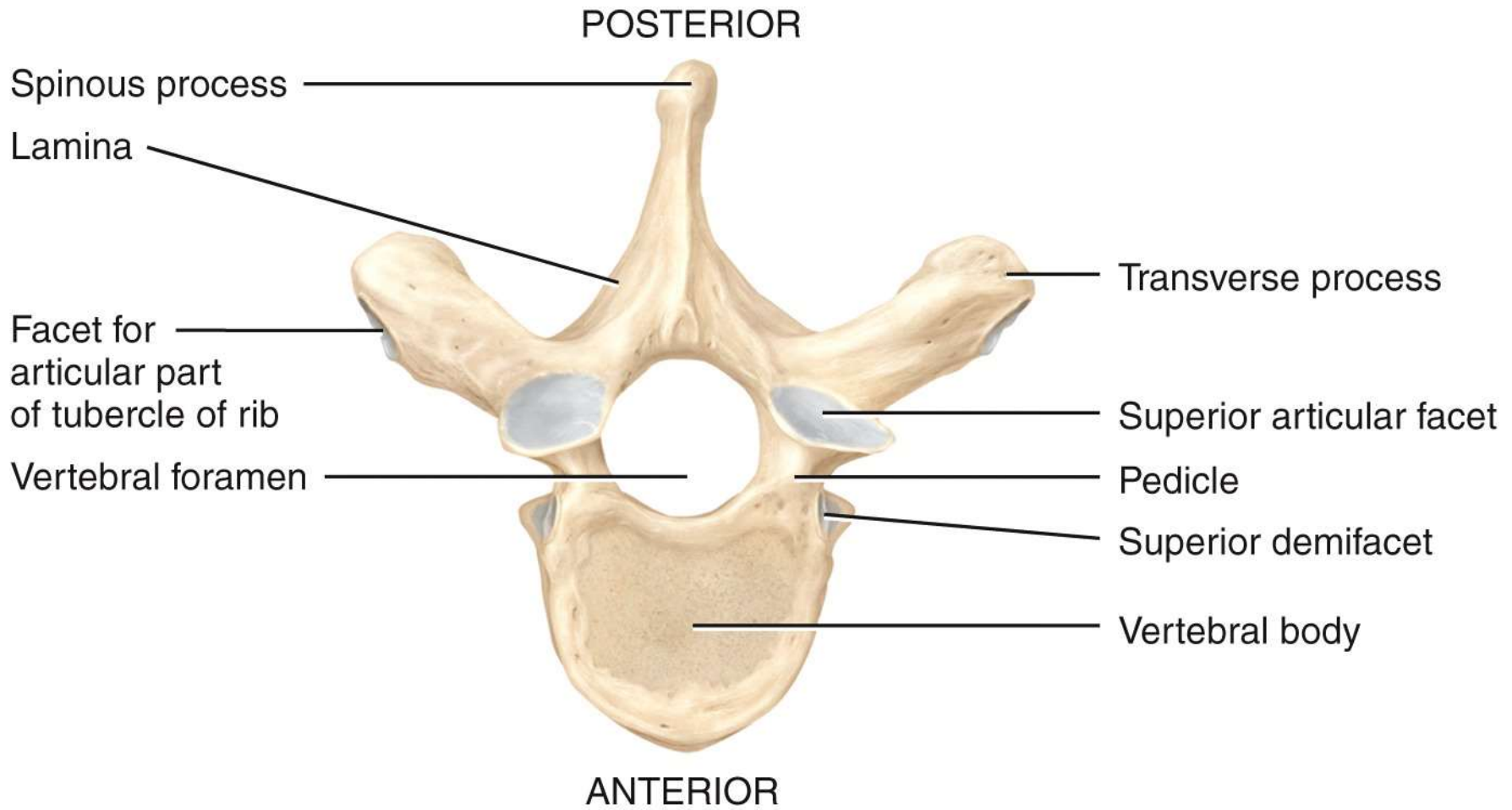


(d) Superior view of axis (C2)

(e) Right lateral view of axis (C2)



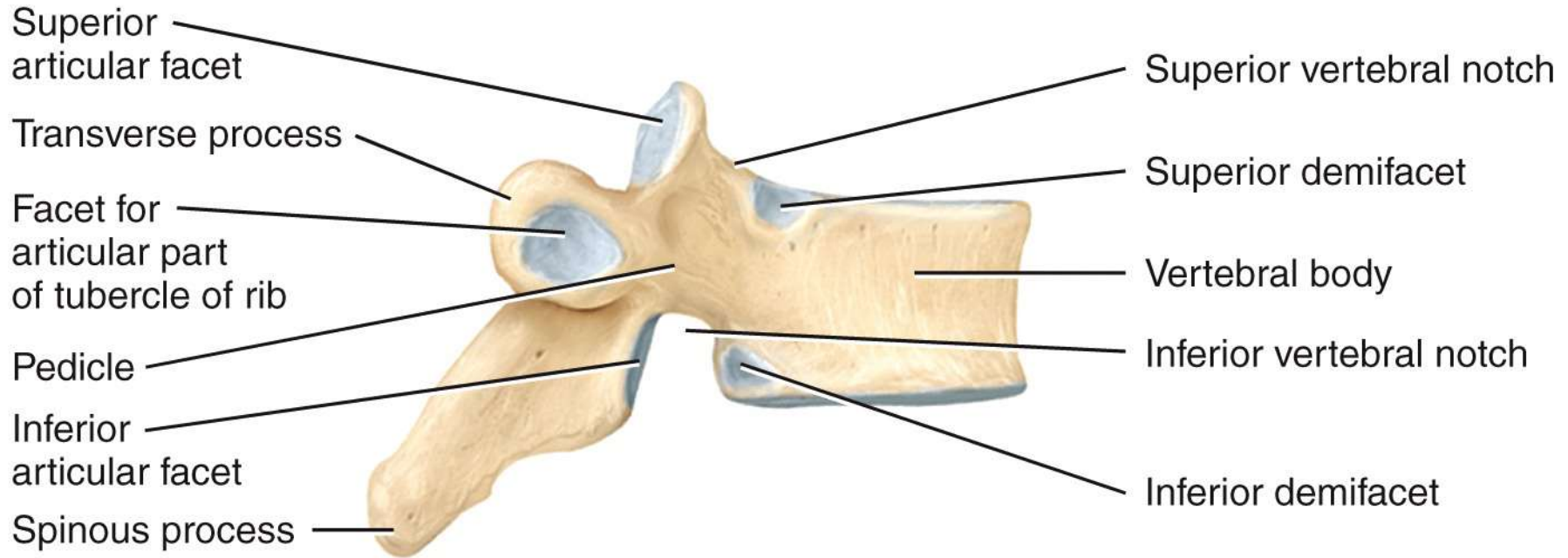
(a) Right lateral view of several articulated thoracic vertebrae



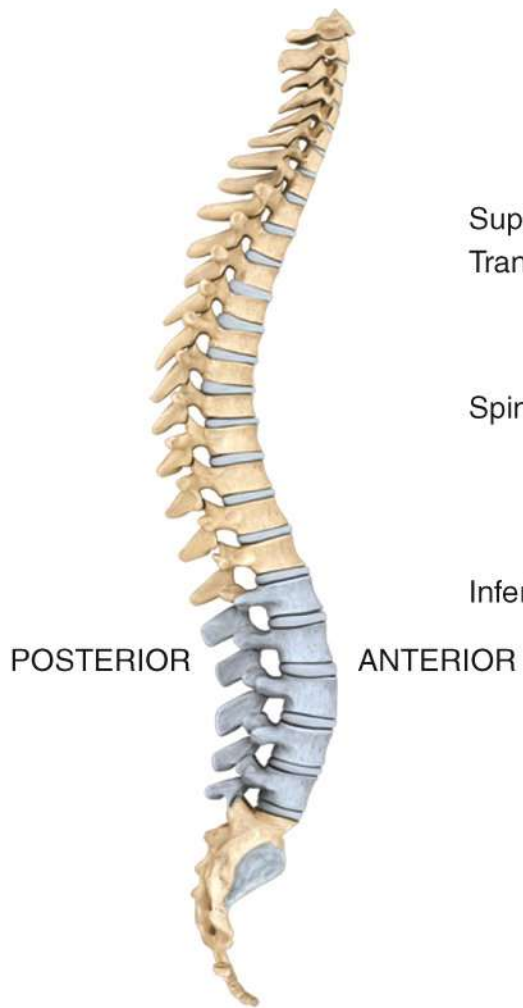(b) Superior view

POSTERIOR

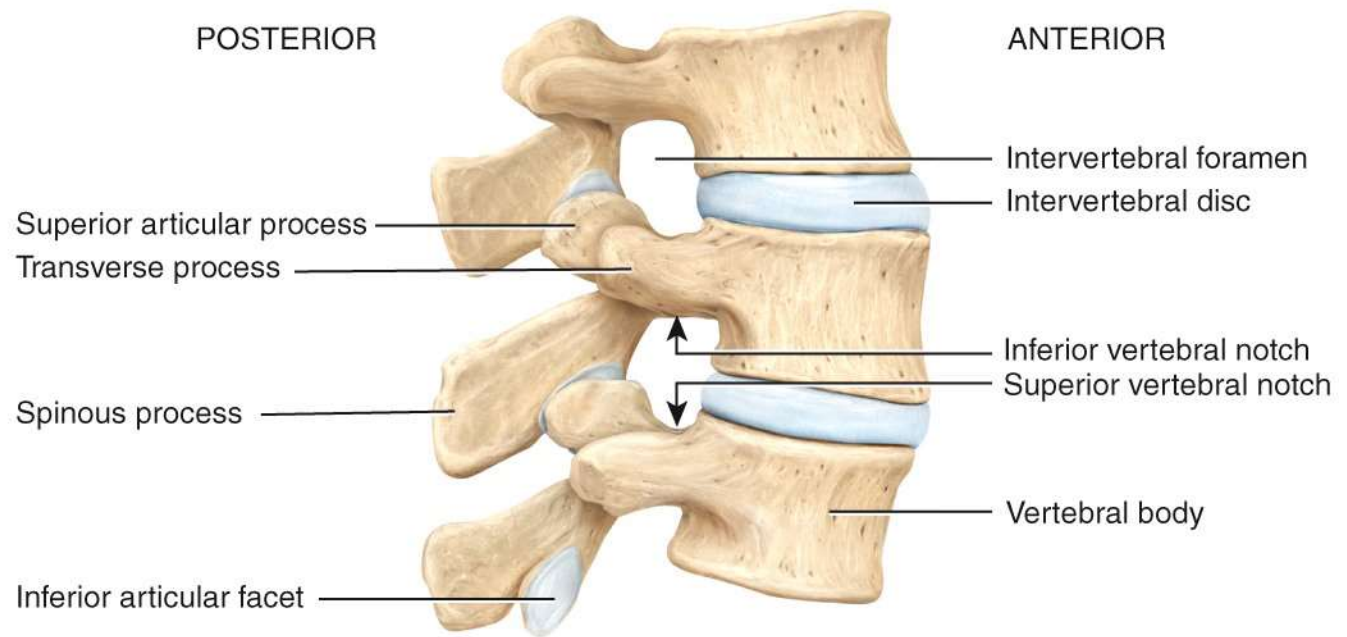
ANTERIOR



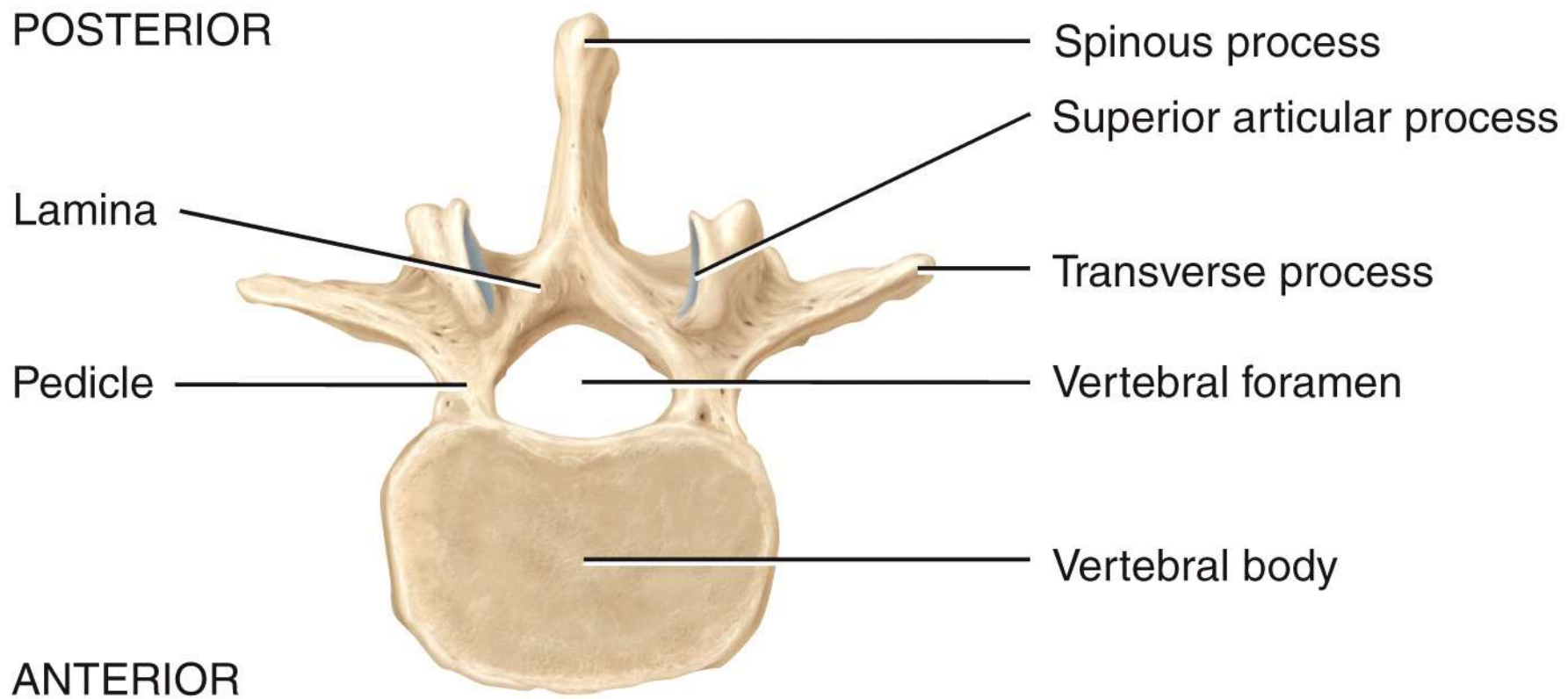
(c) Right lateral view



Location of lumbar vertebrae



(a) Right lateral view of articulated lumbar vertebrae



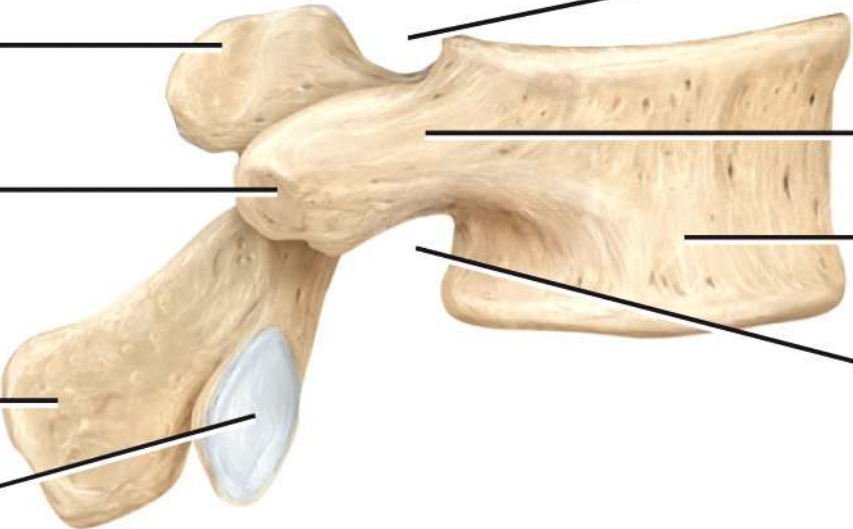
(b) Superior view

POSTERIOR

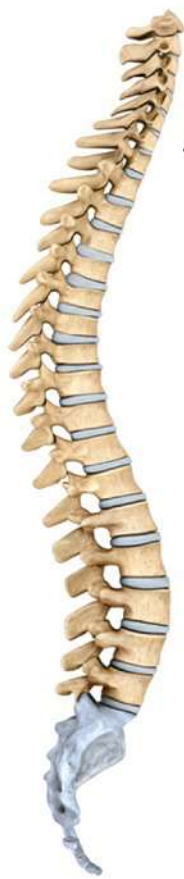ANTERIOR

Superior articular process
Transverse process
Spinous process
Inferior articular facet

Superior vertebral notch
Pedicle
Vertebral body
Inferior vertebral notch

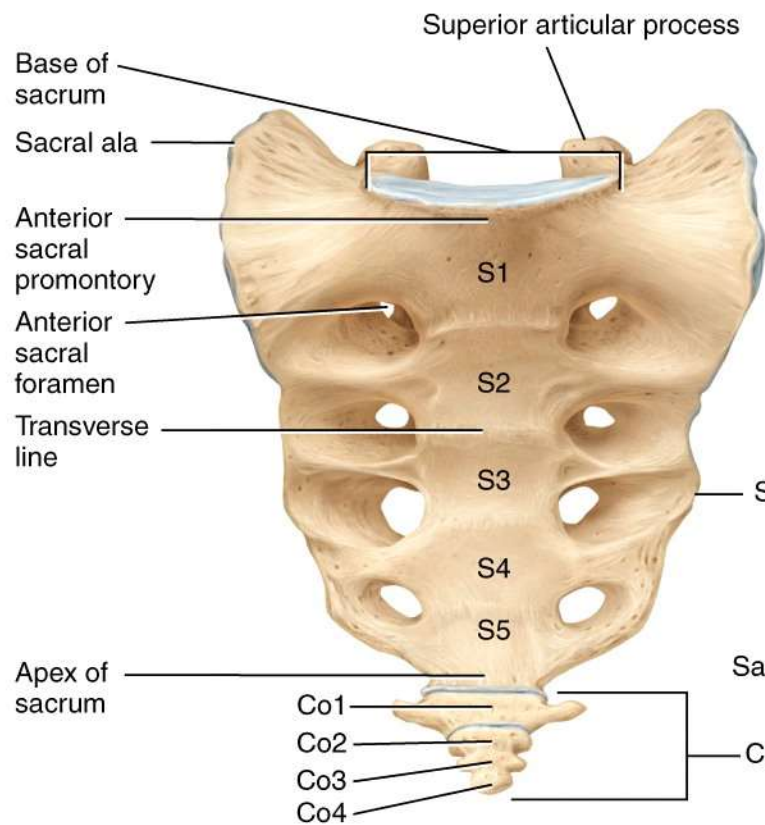


(c) Right lateral view

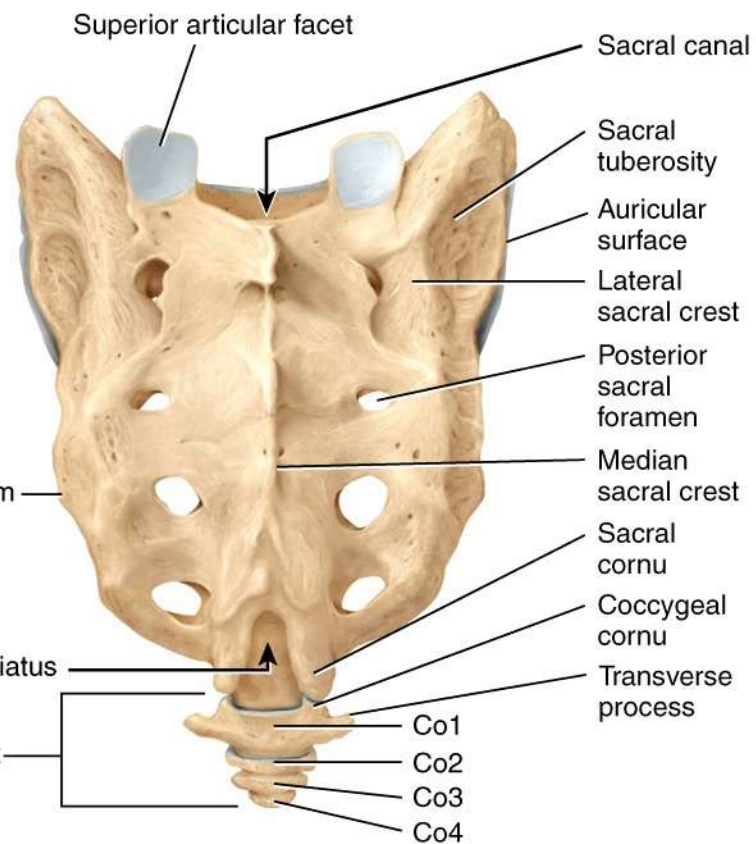


Location of sacrum and coccyx

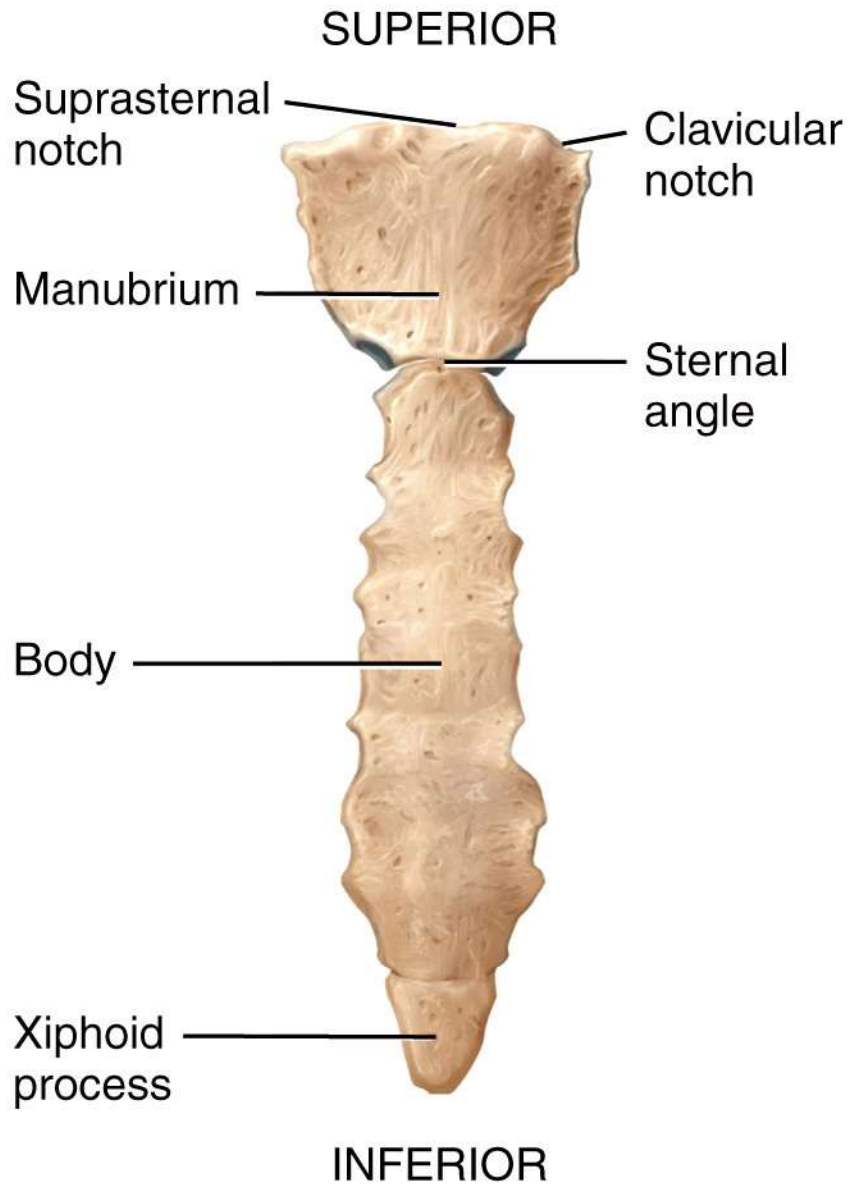
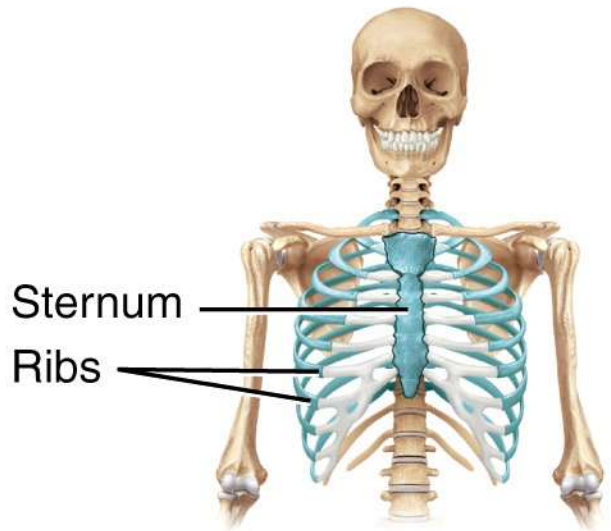
ANTERIOR



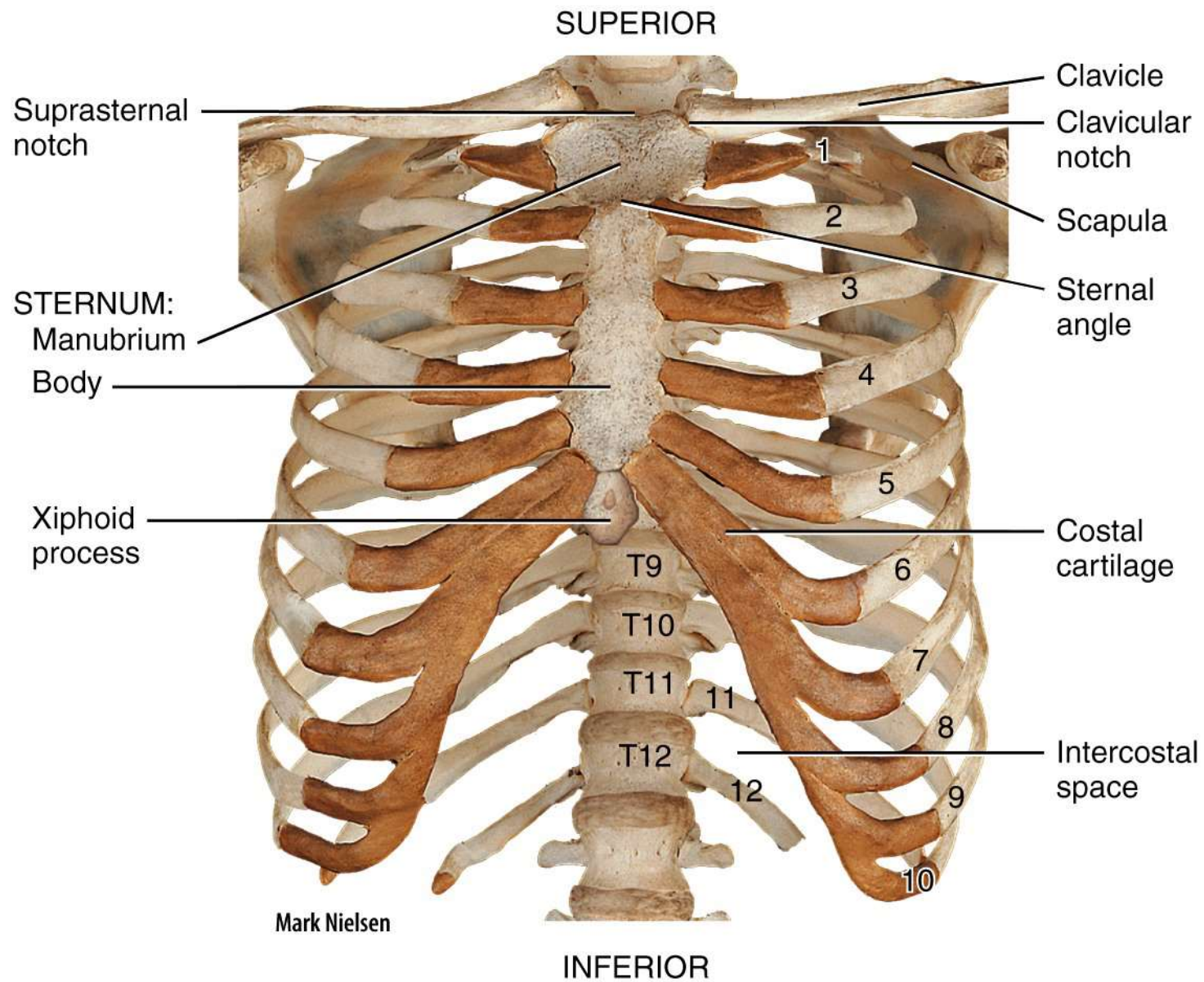
(a) Anterior view



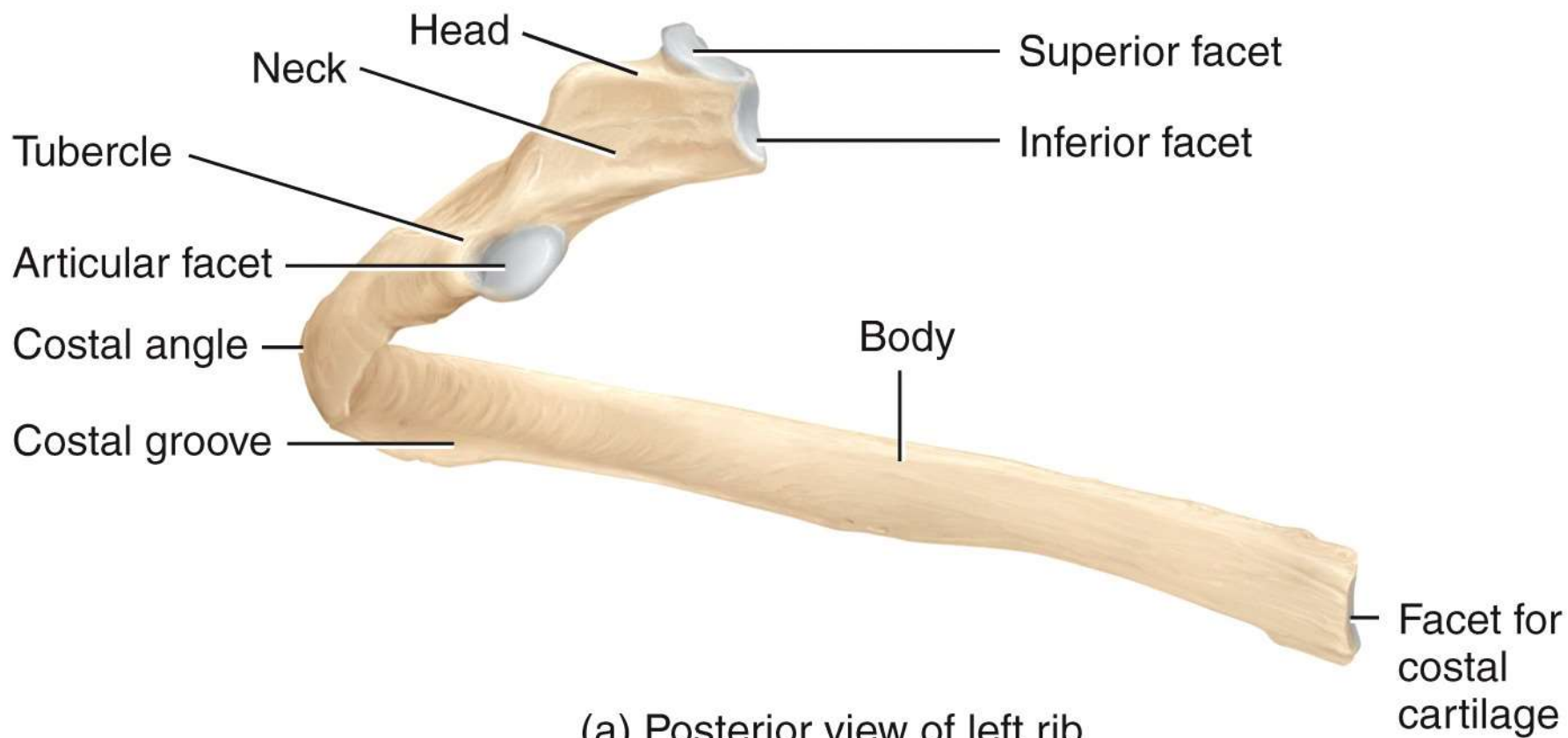
(b) Posterior view

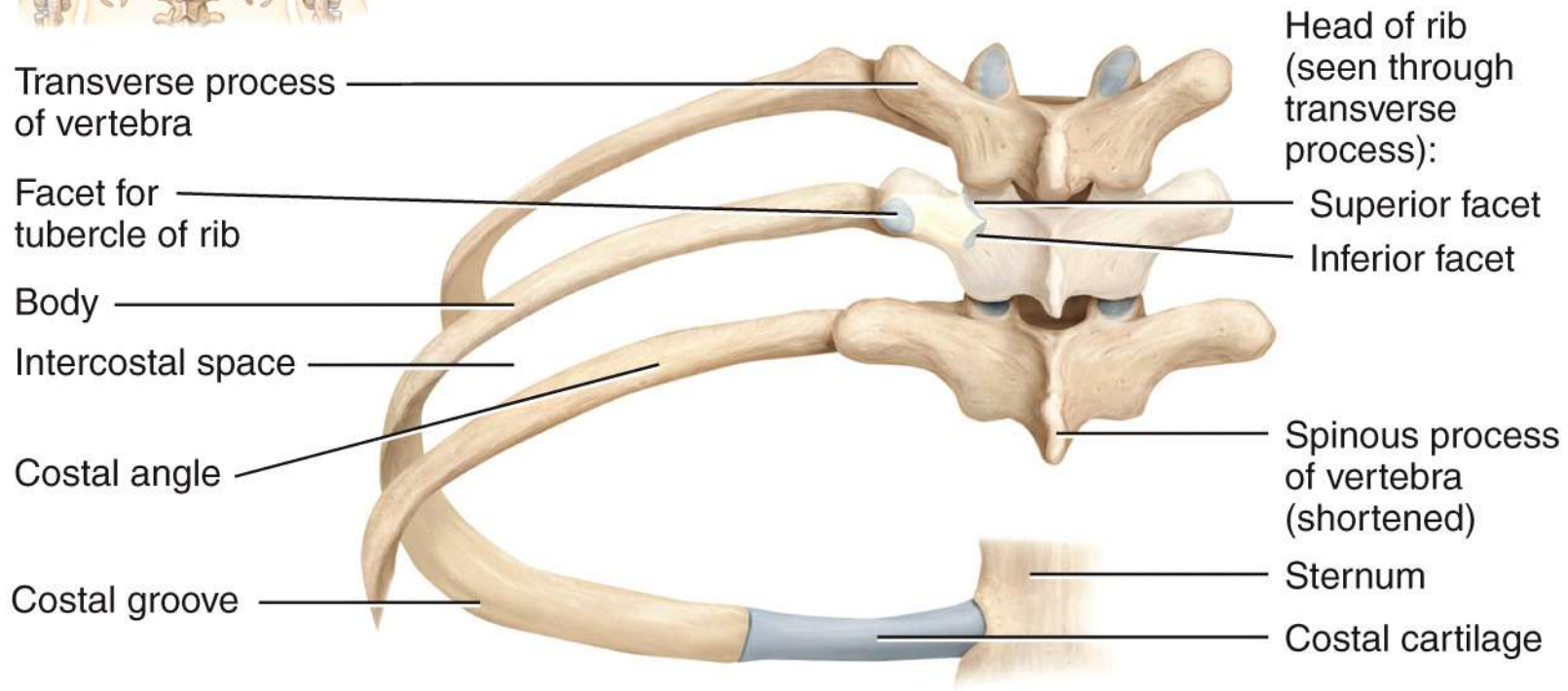
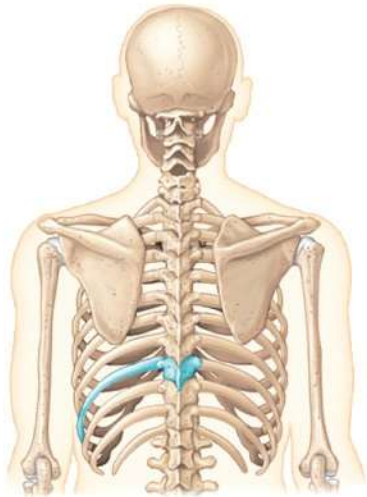


(a) Anterior view of sternum

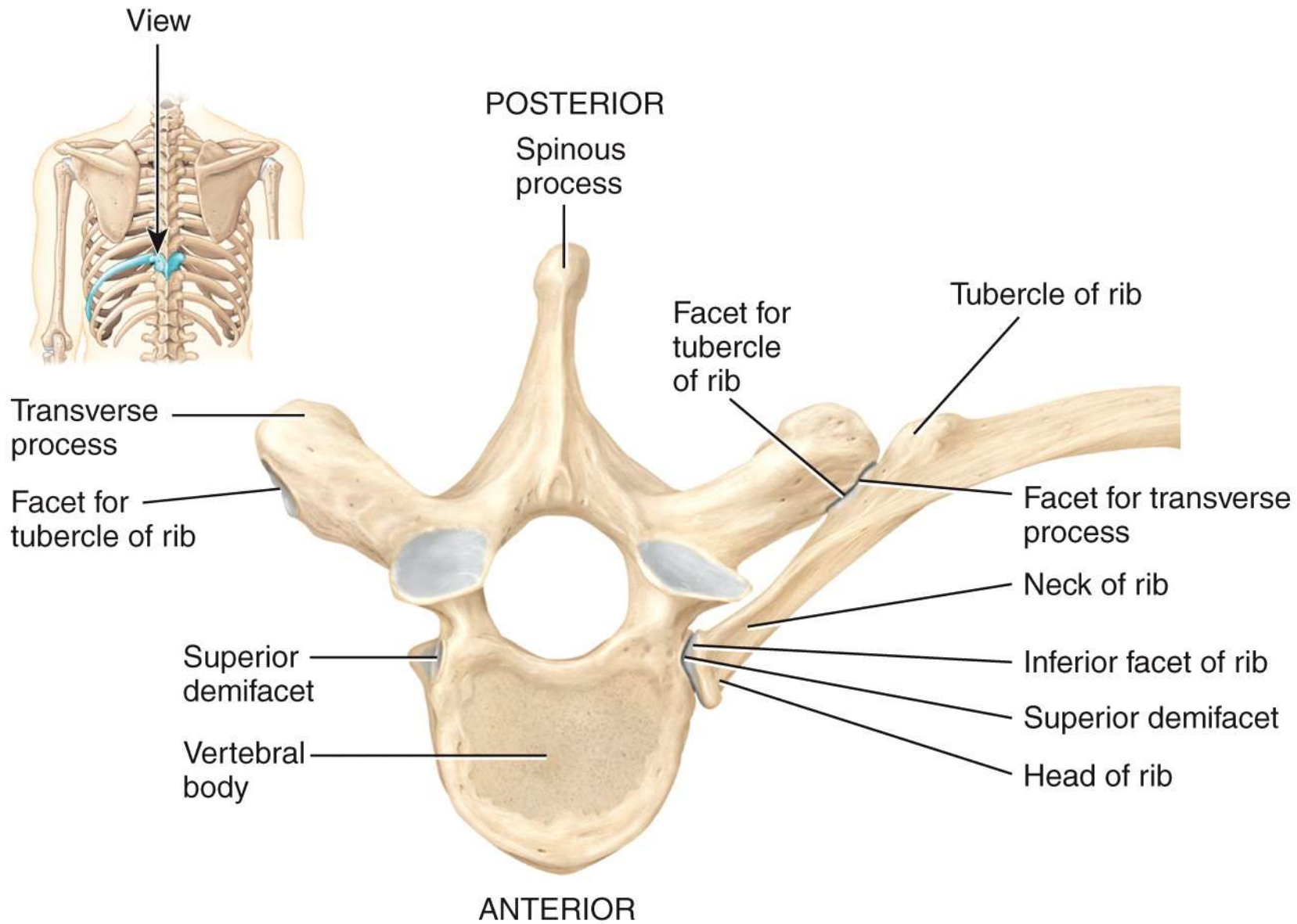


(b) Anterior view of skeleton of thorax



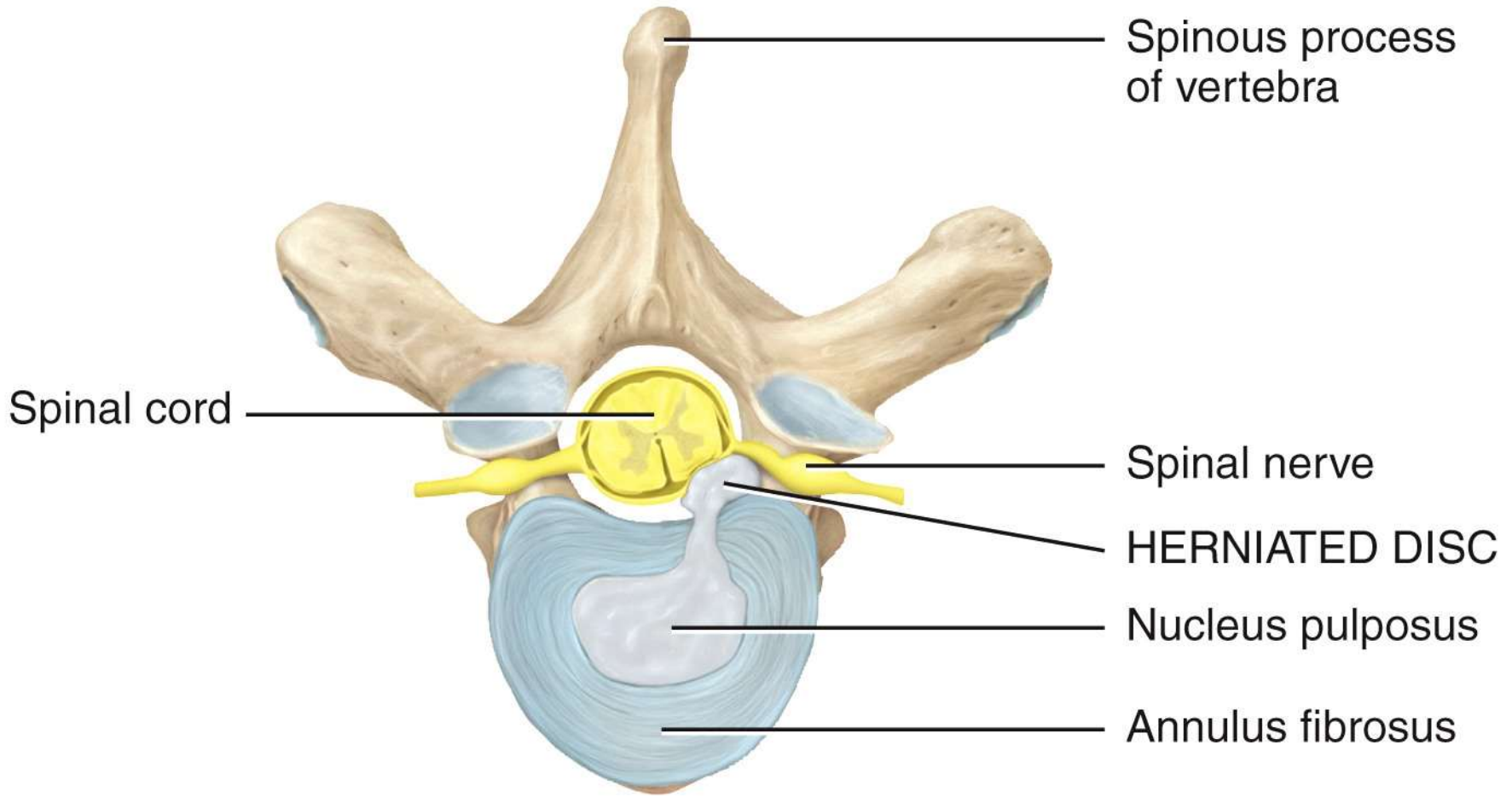


(b) Posterior view of left ribs articulated with thoracic vertebrae and sternum



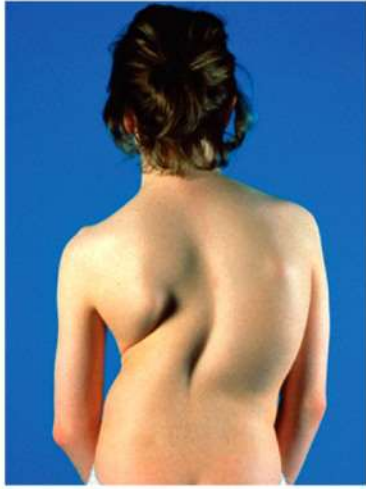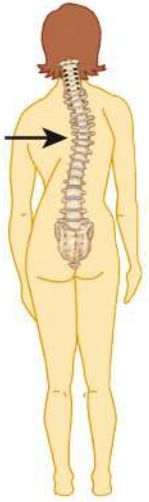(c) Superior view of left rib articulated with thoracic vertebra

POSTERIOR



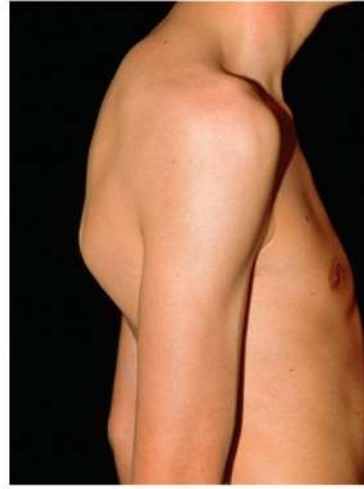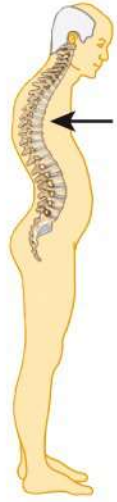ANTERIOR

Superior view



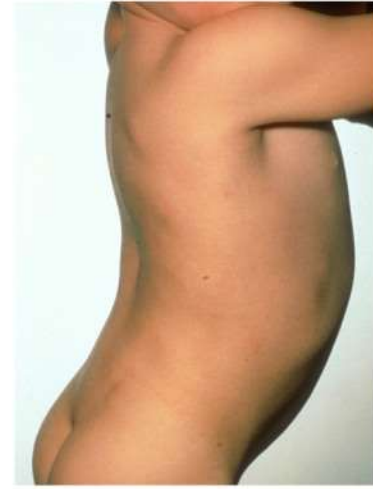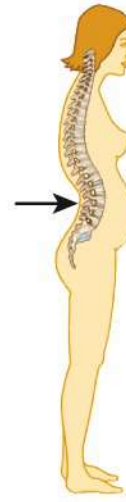Princess Margaret Rose Orthopaedic
Hospital/Photo Researchers, Inc.

(a) Scoliosis



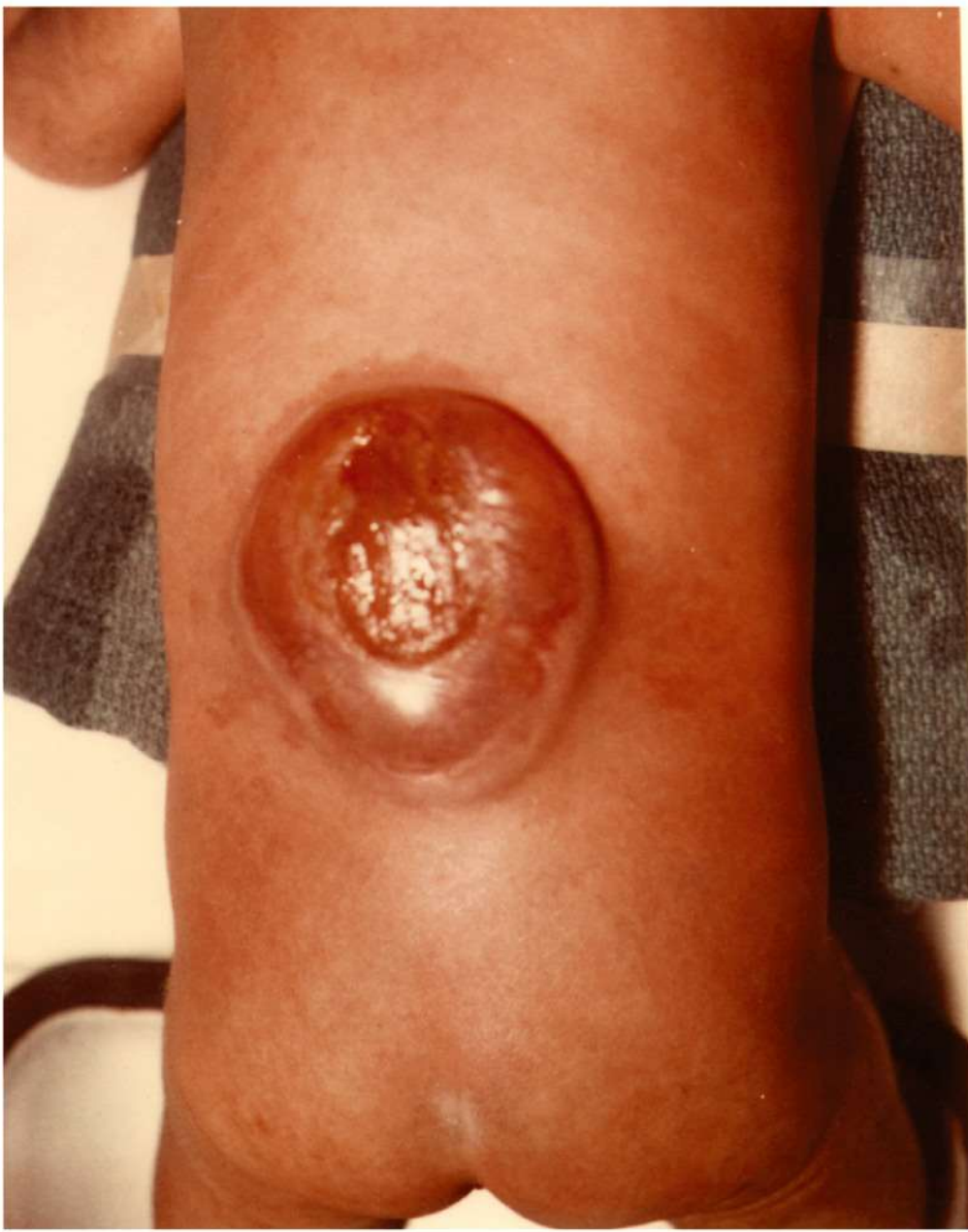Dr. P. Marazzi/Photo Researchers, Inc.

(b) Kyphosis



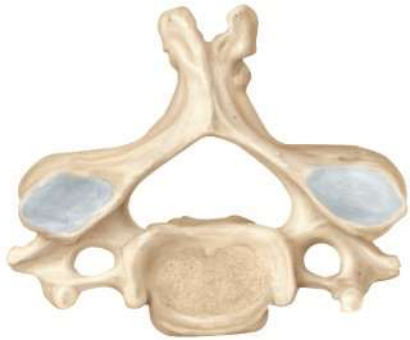Custom Medical Stock Photo, Inc.

(c) Lordosis

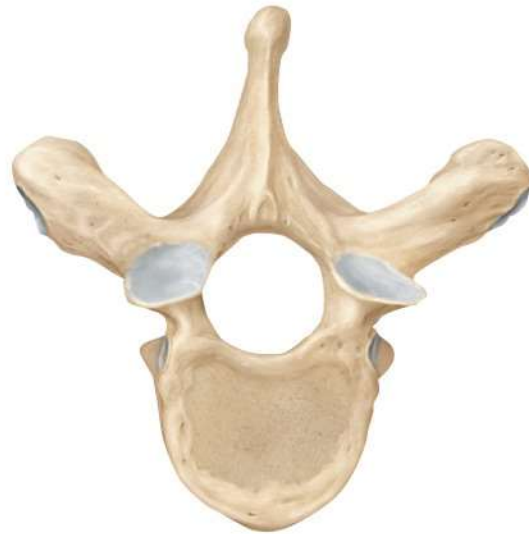

Center for Disease Control/Project Masters, Inc

Cervical



Thoracic



Lumbar

