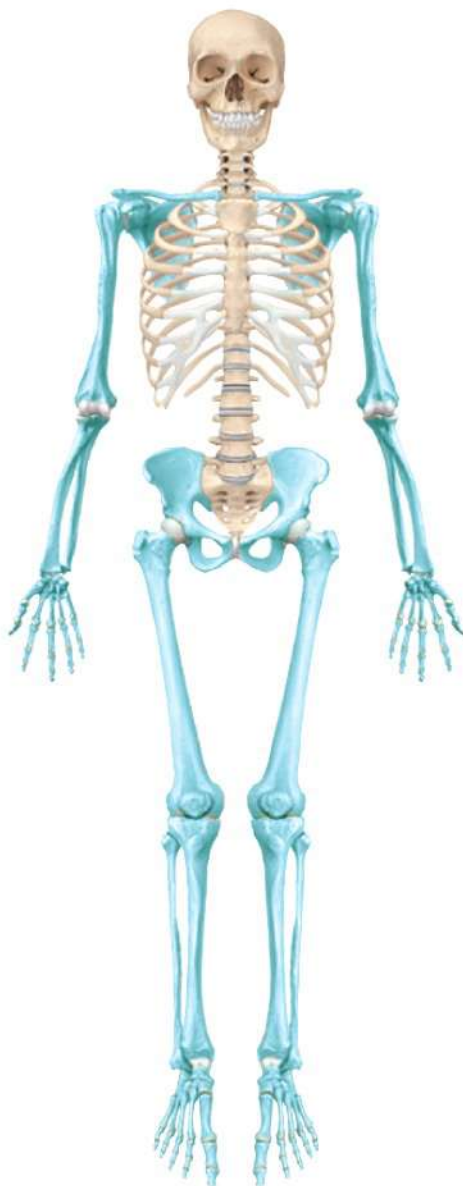

C7

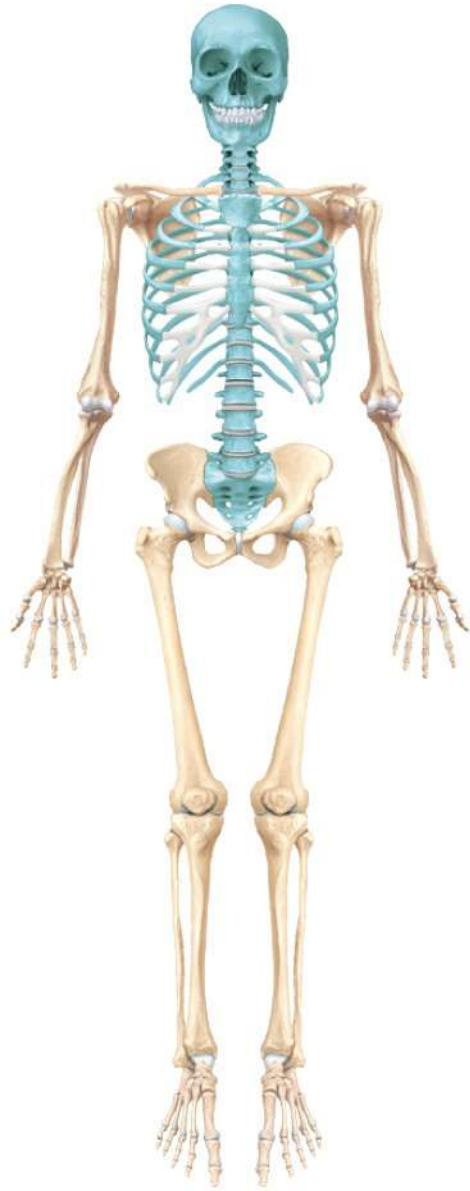The Axial Skeletal System

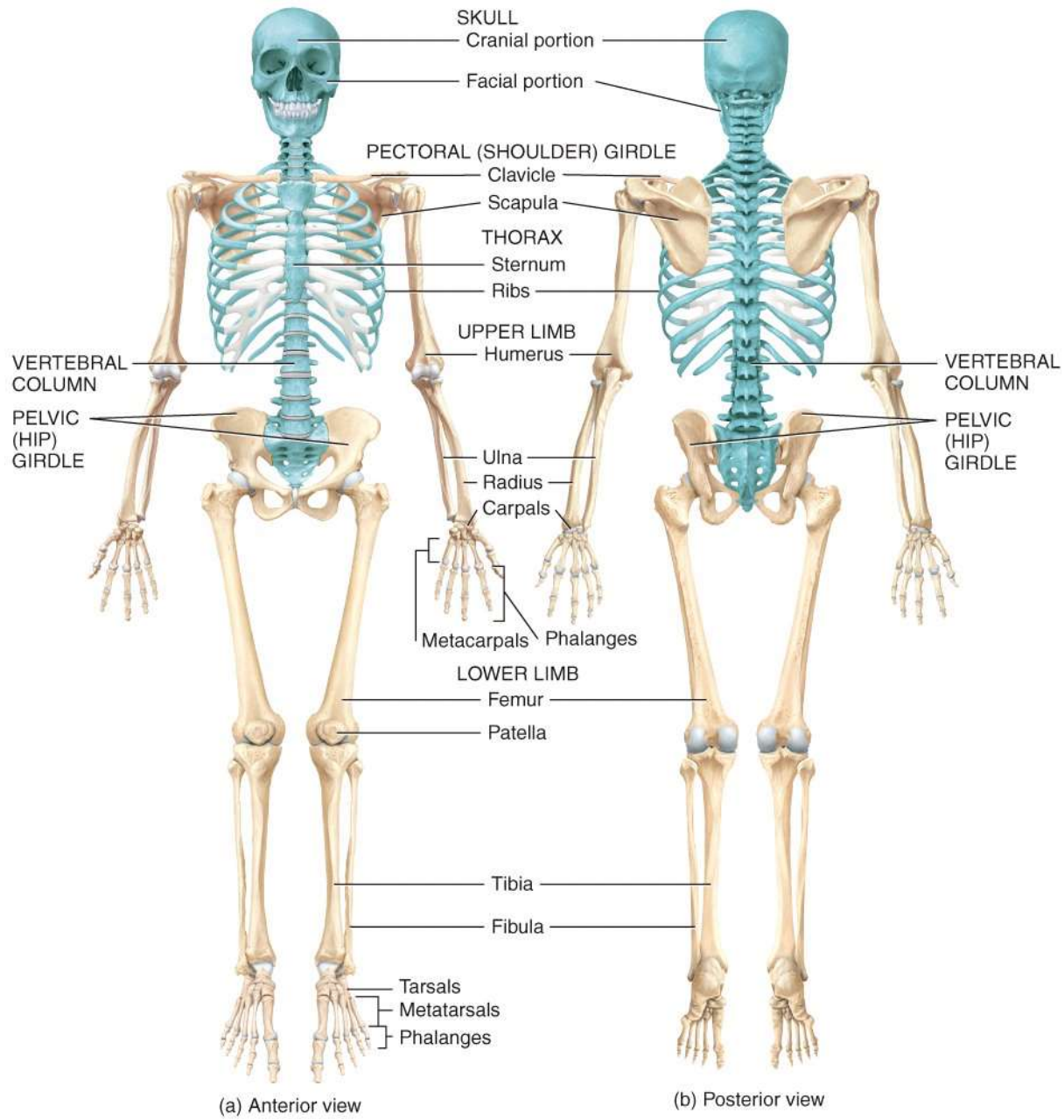
Images Only

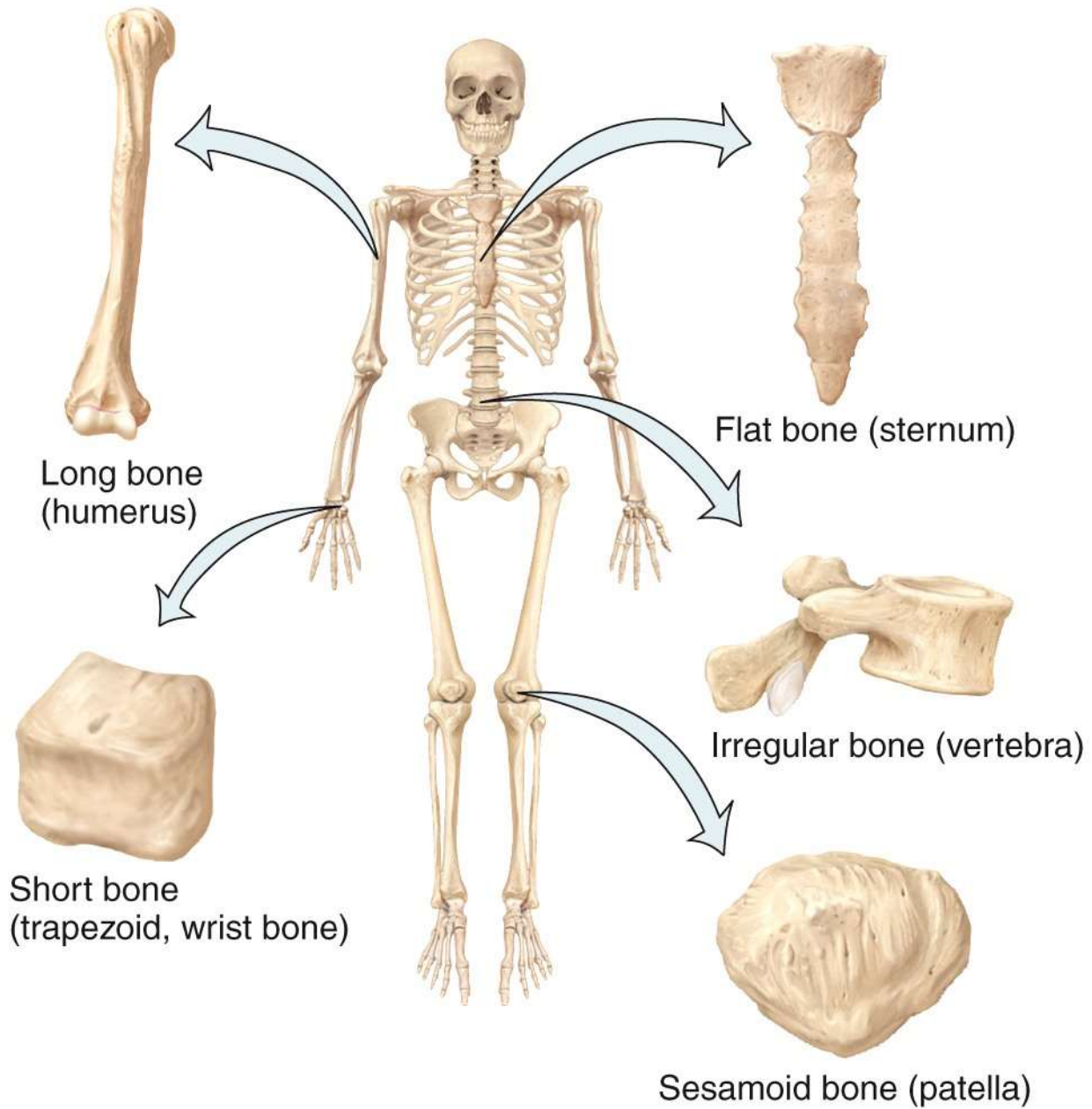
Appendicular skeleton



Axial skeleton







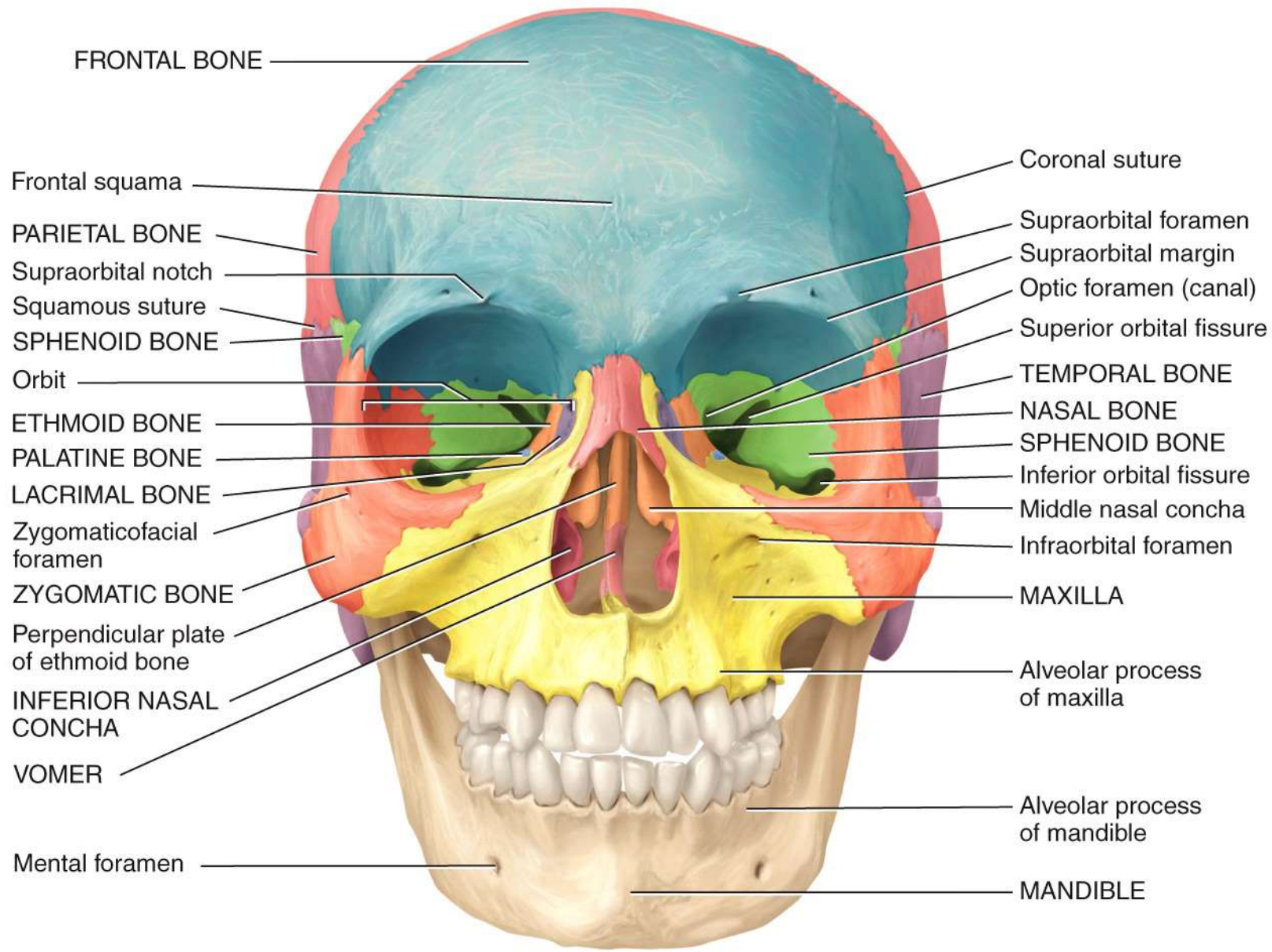
Long bone
(humerus)

Flat bone (sternum)

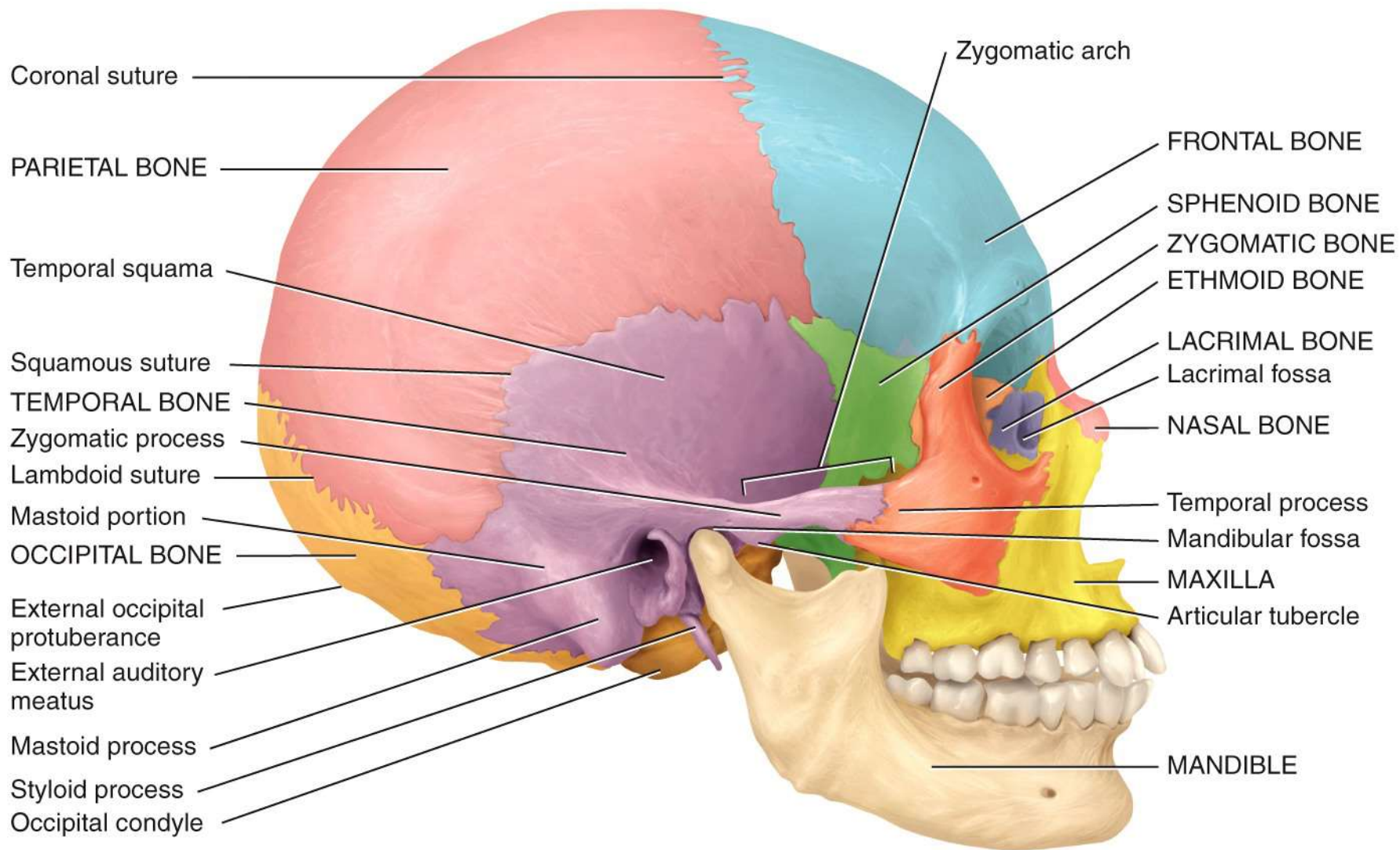
Short bone
(trapezoid, wrist bone)

Irregular bone (vertebra)

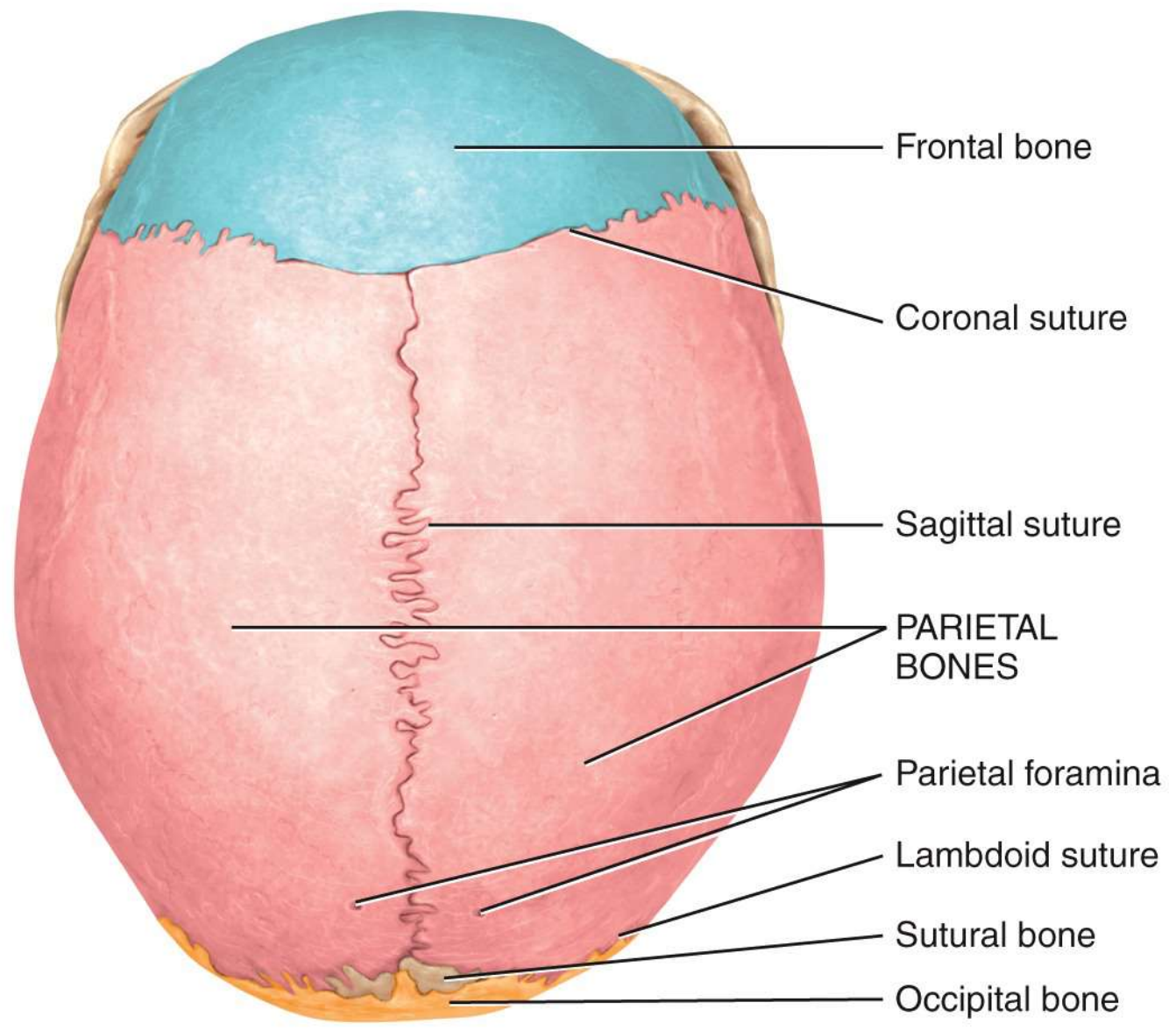
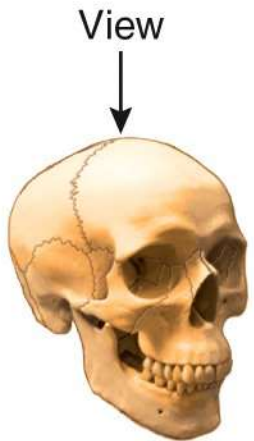
Sesamoid bone (patella)



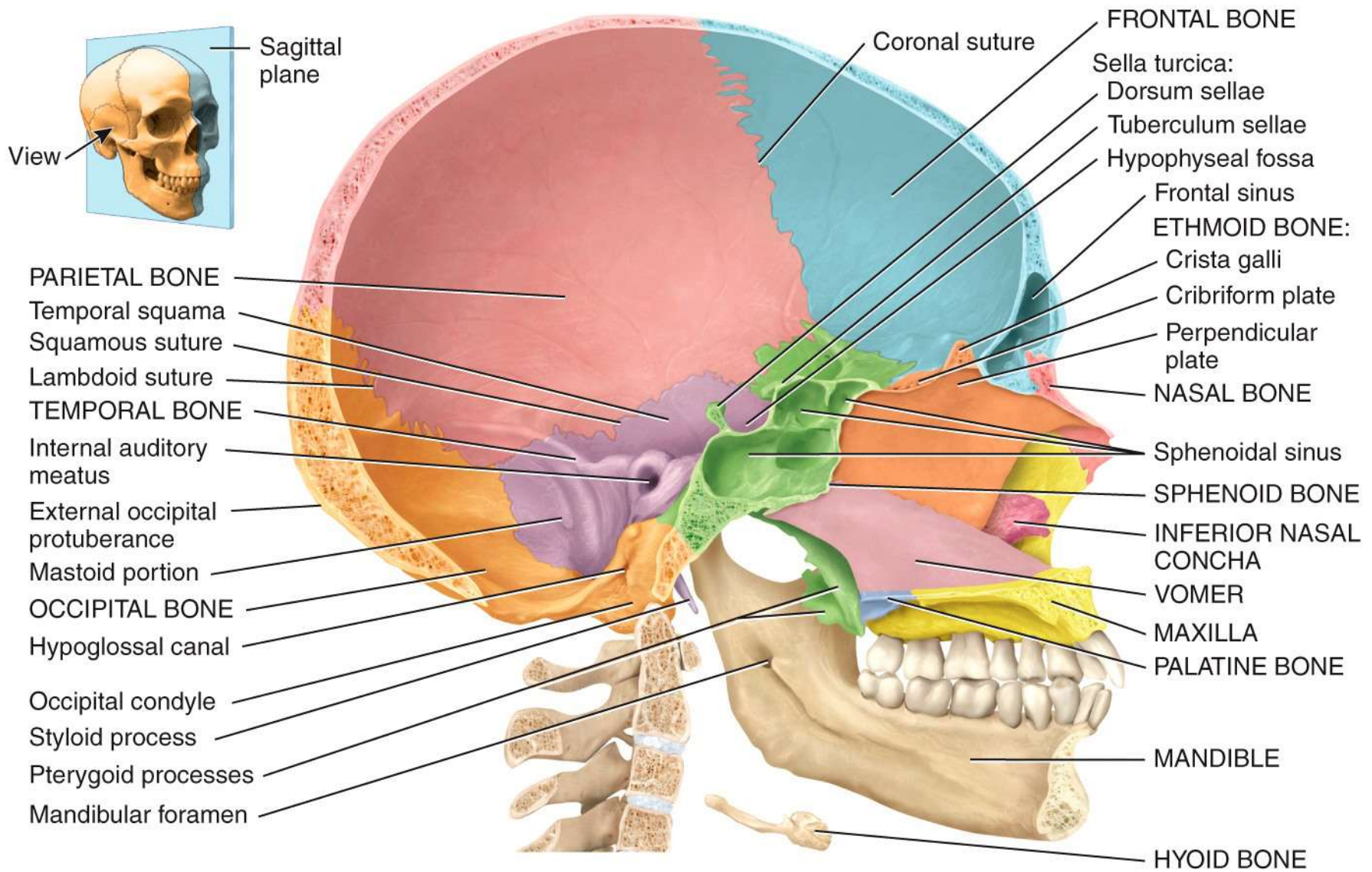
Anterior view



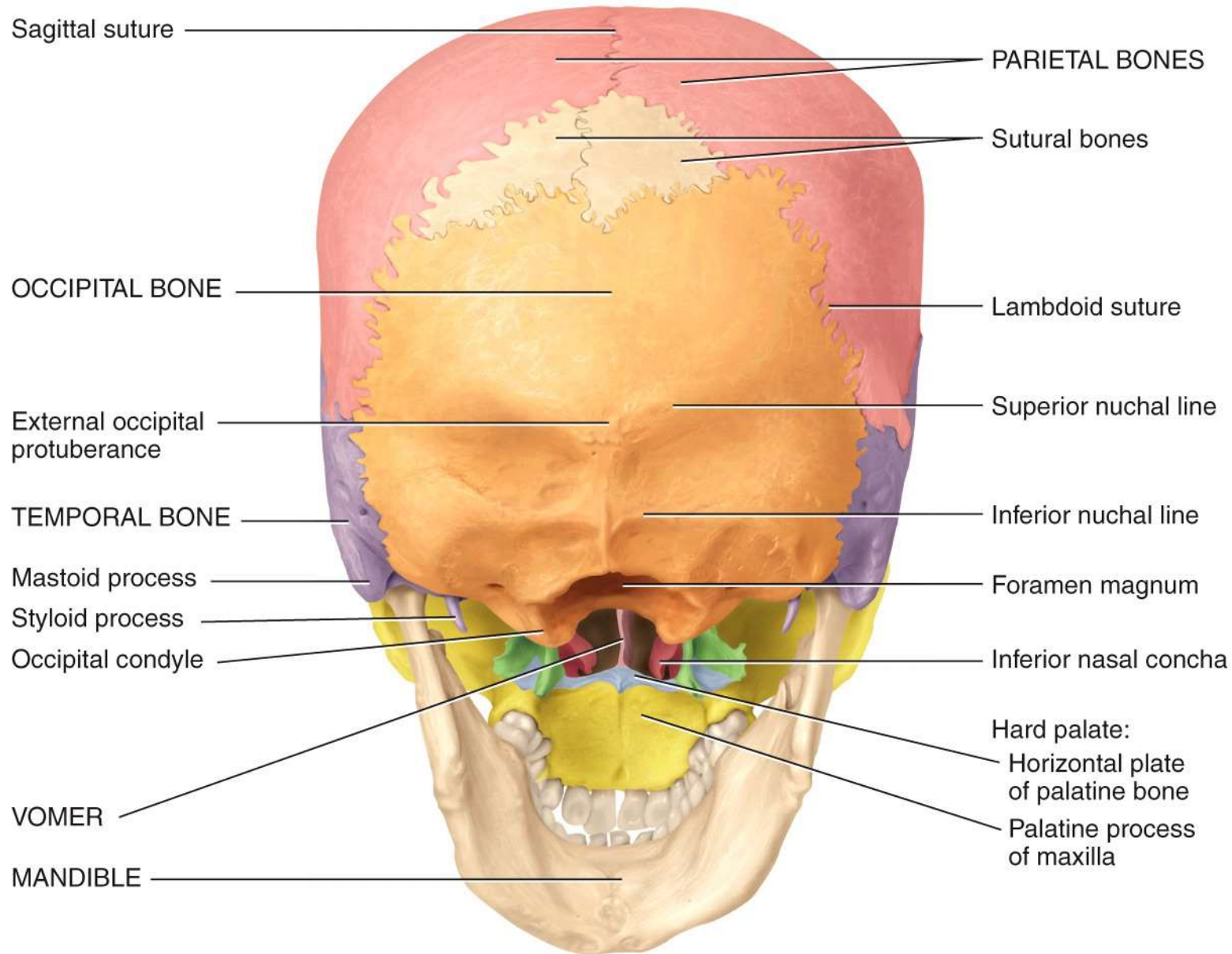
(a) Right lateral view



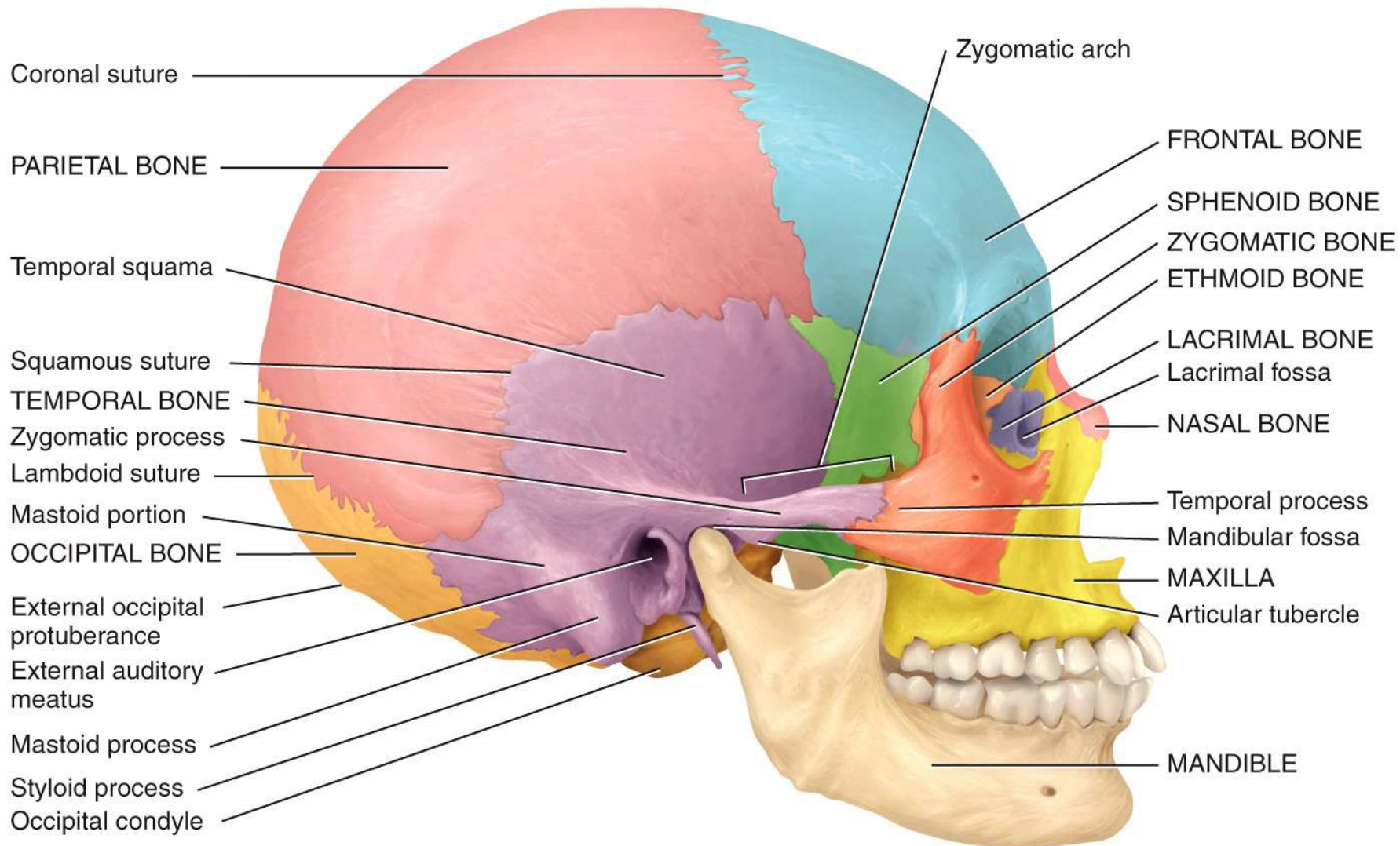
(b) Superior view



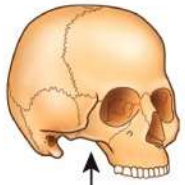
Medial view of sagittal section



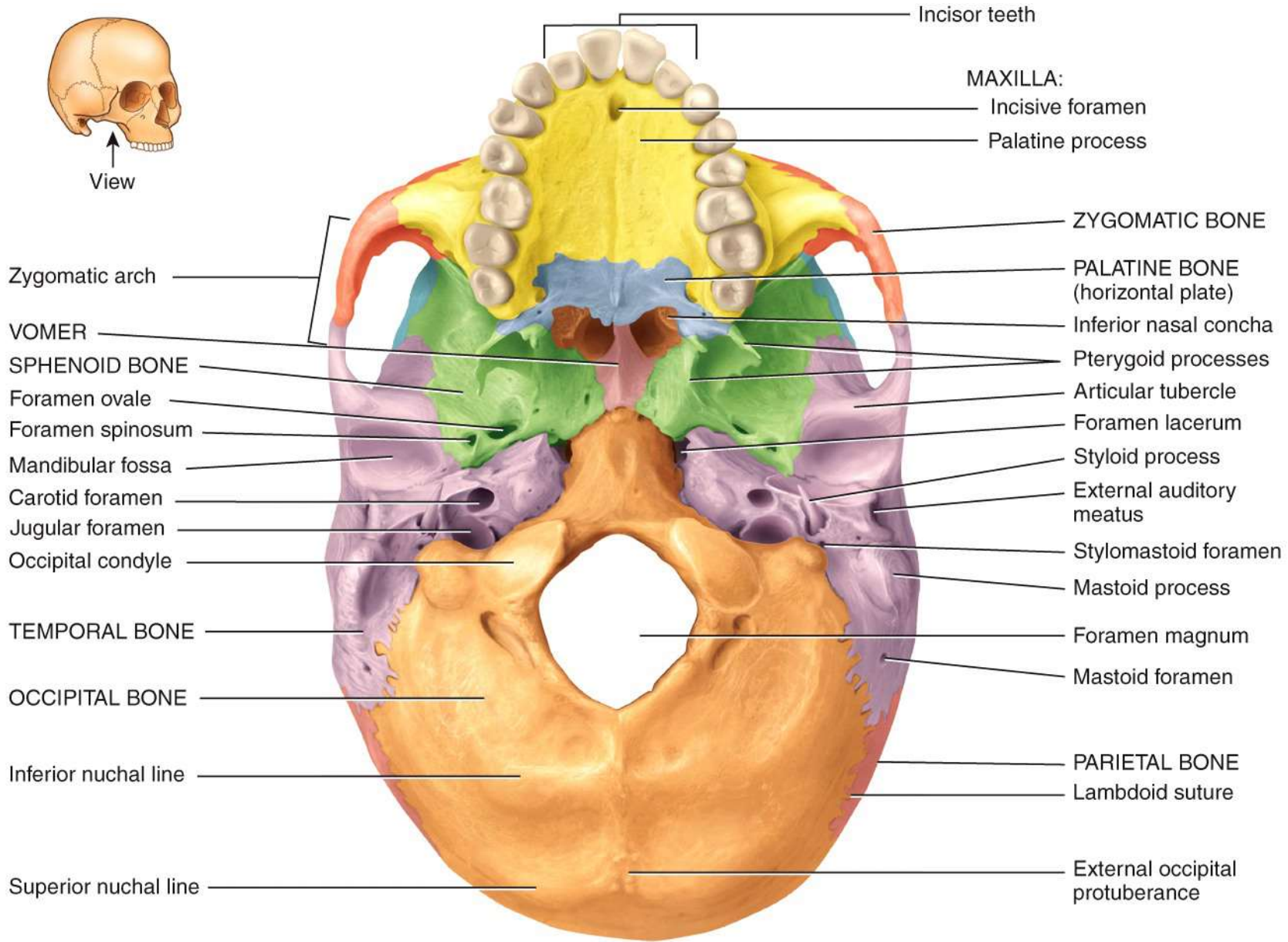
Posteroinferior view



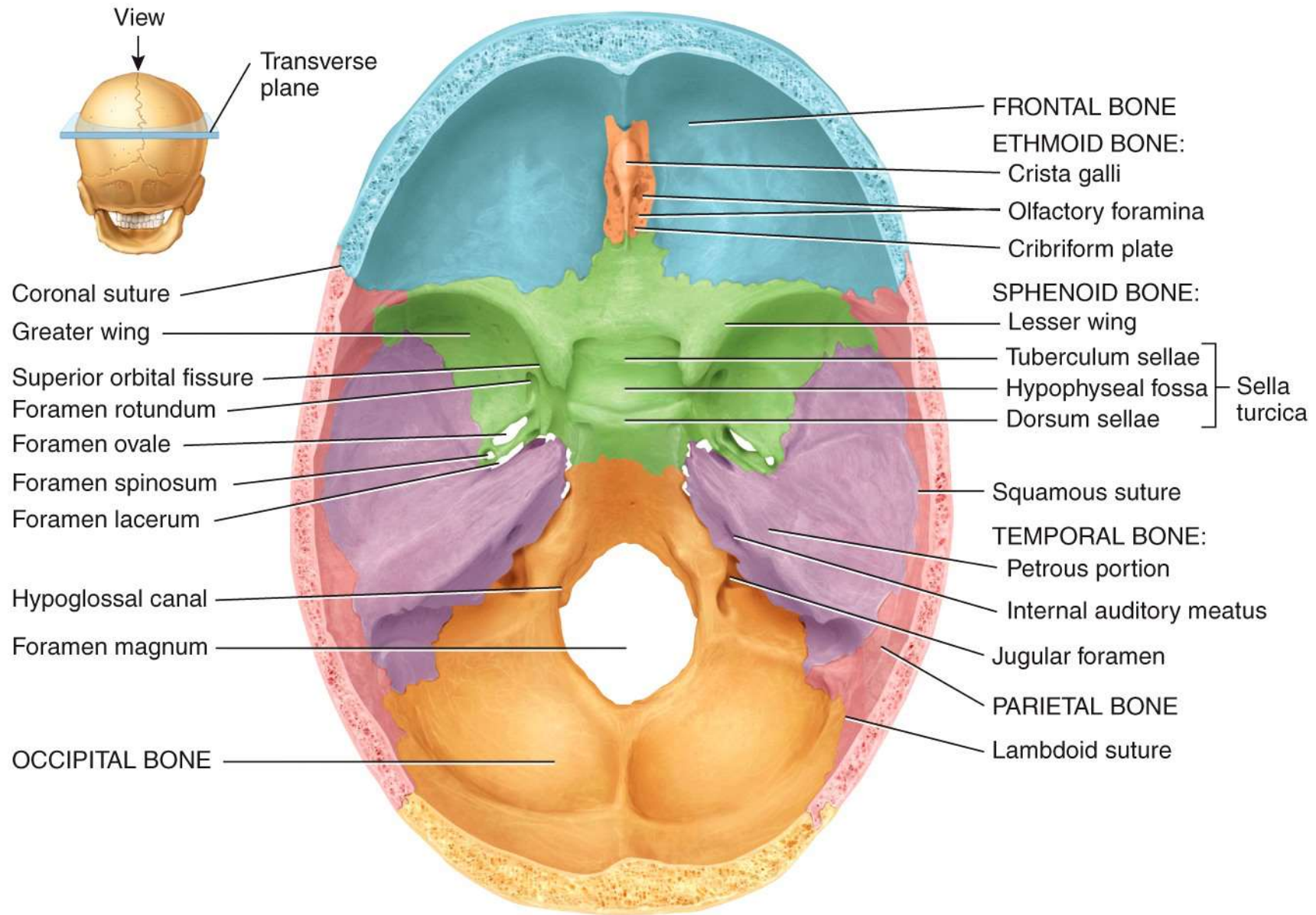
(a) Right lateral view



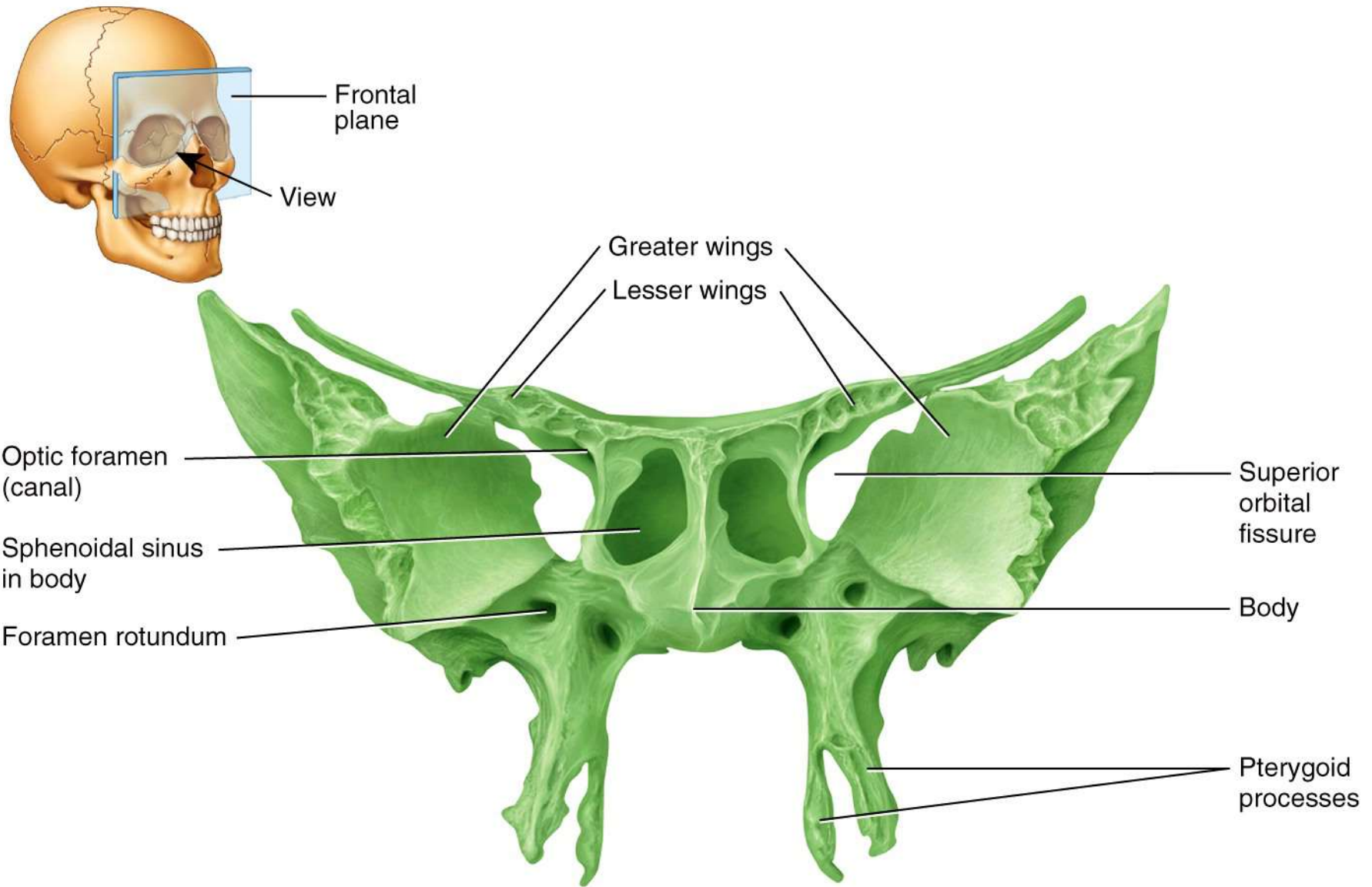
View



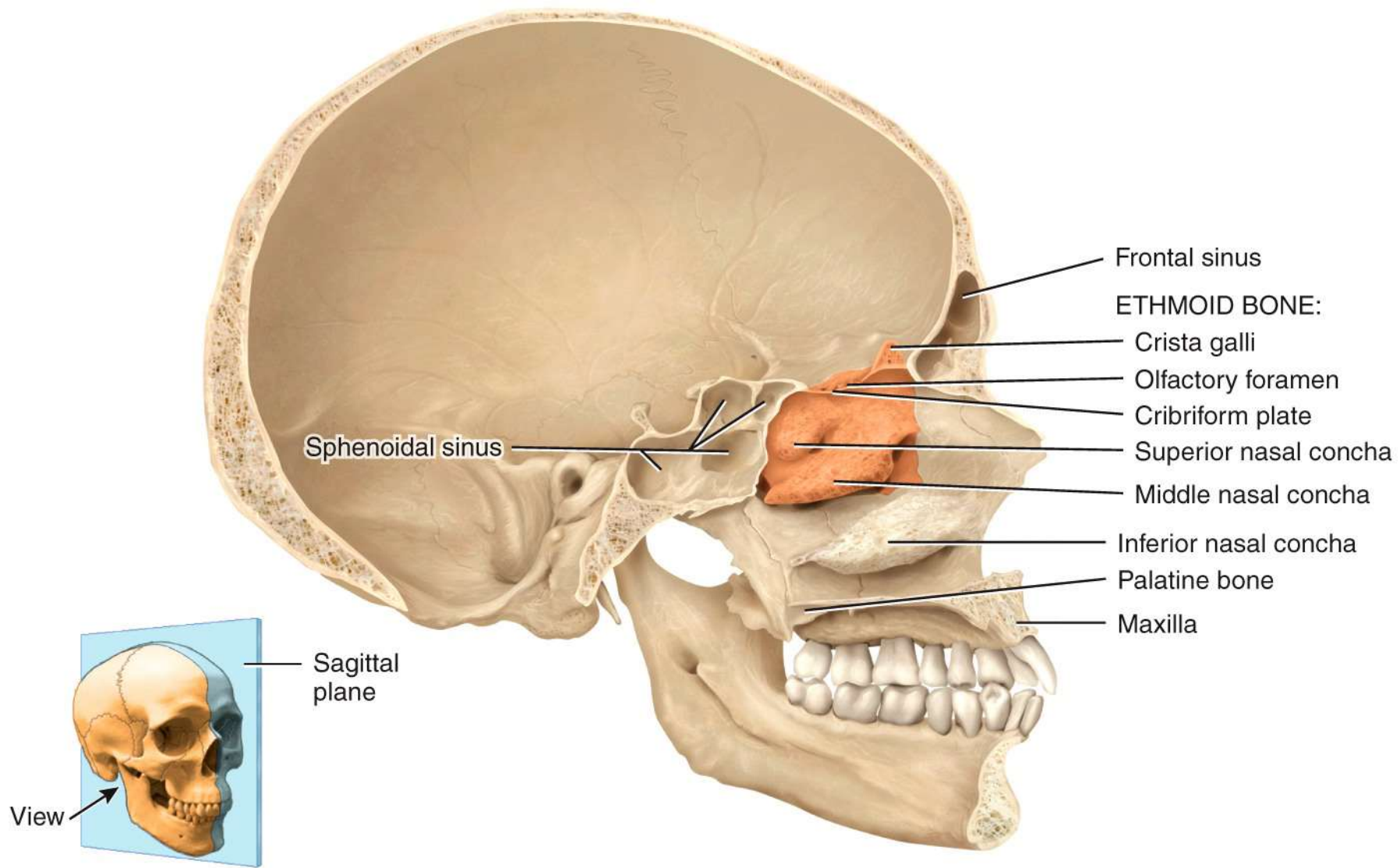
Inferior view



(a) Superior view of sphenoid bone in floor of cranium

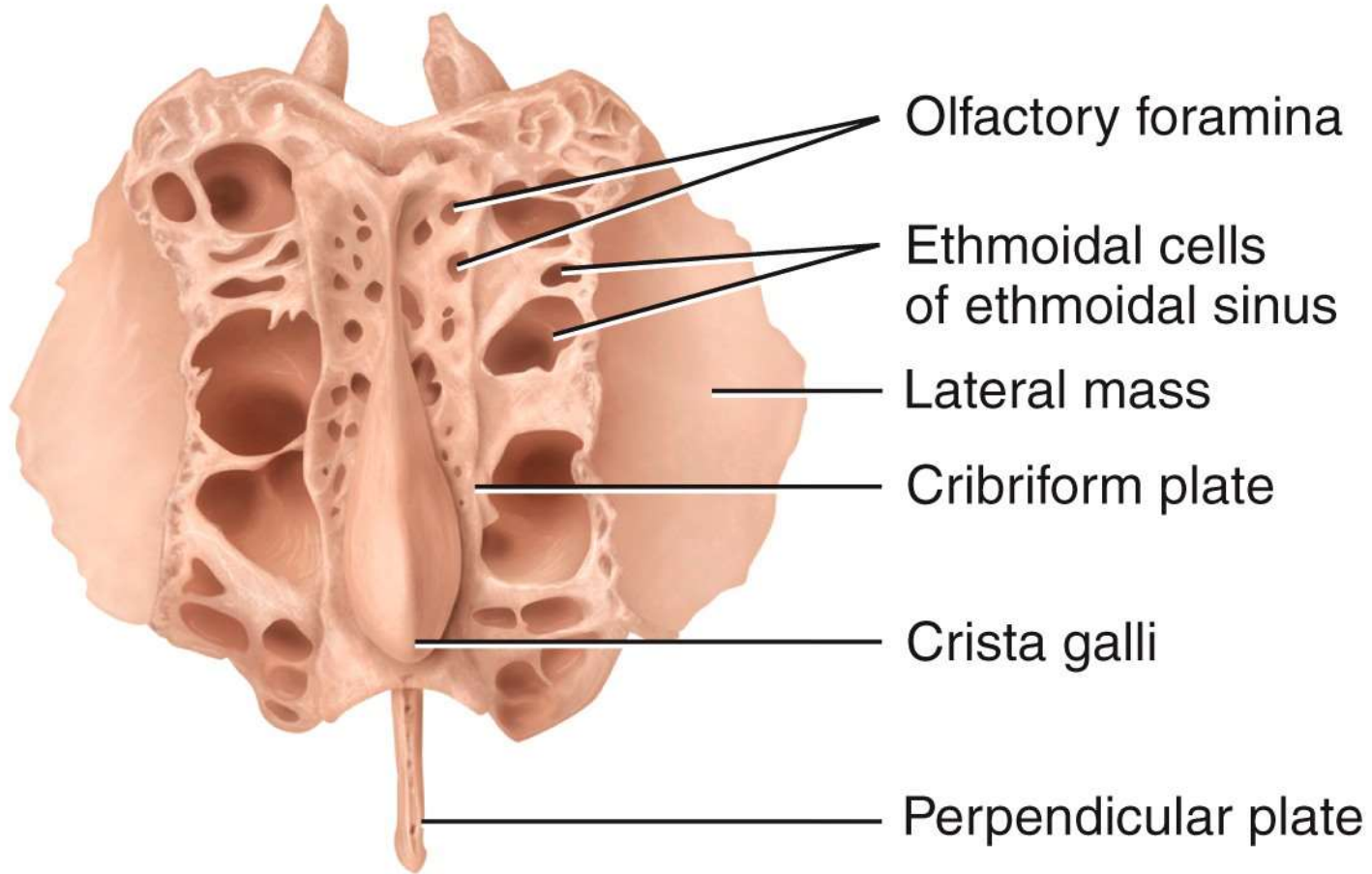


(b) Anterior view of sphenoid bone



(a) Medial view of sagittal section

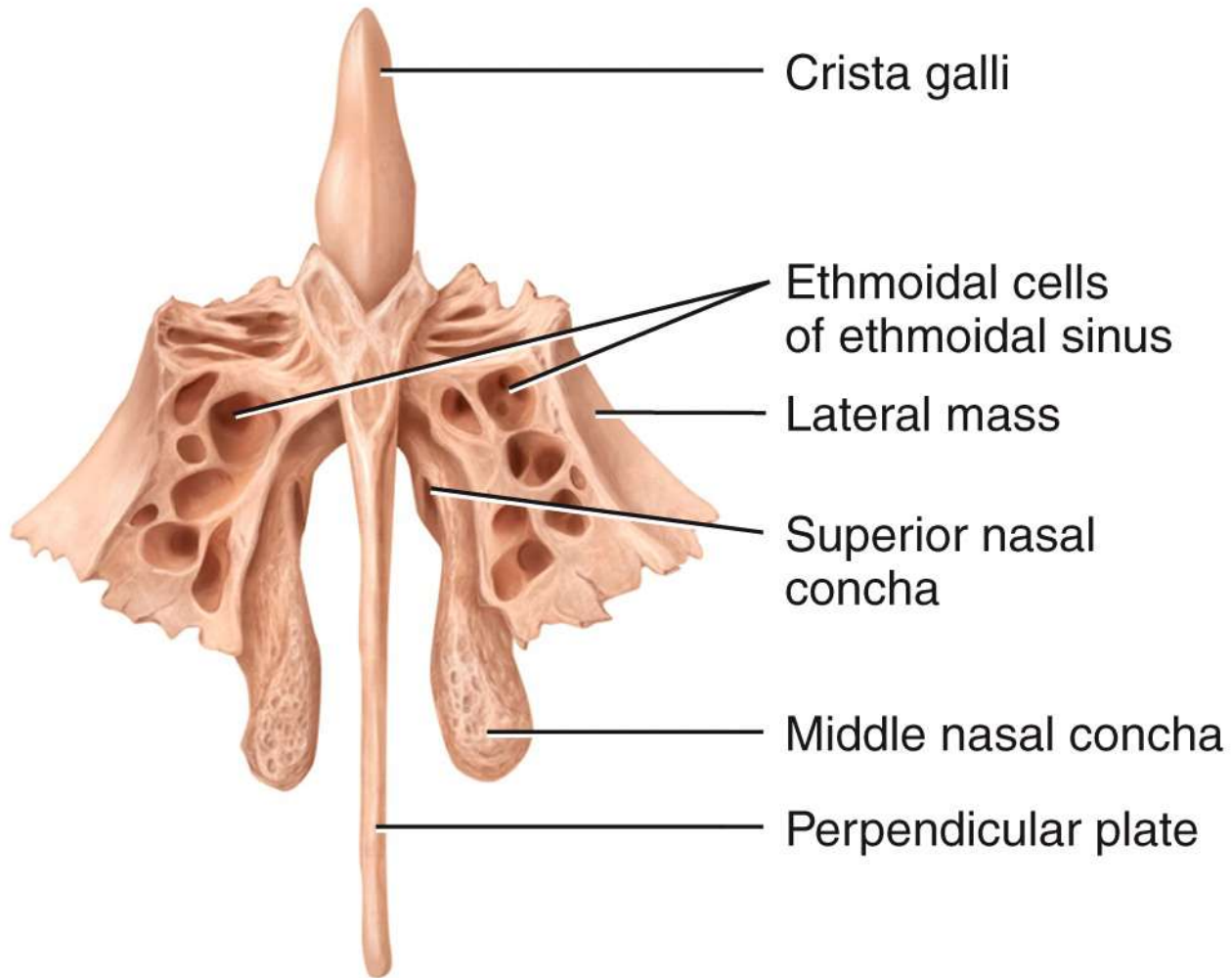
POSTERIOR



ANTERIOR

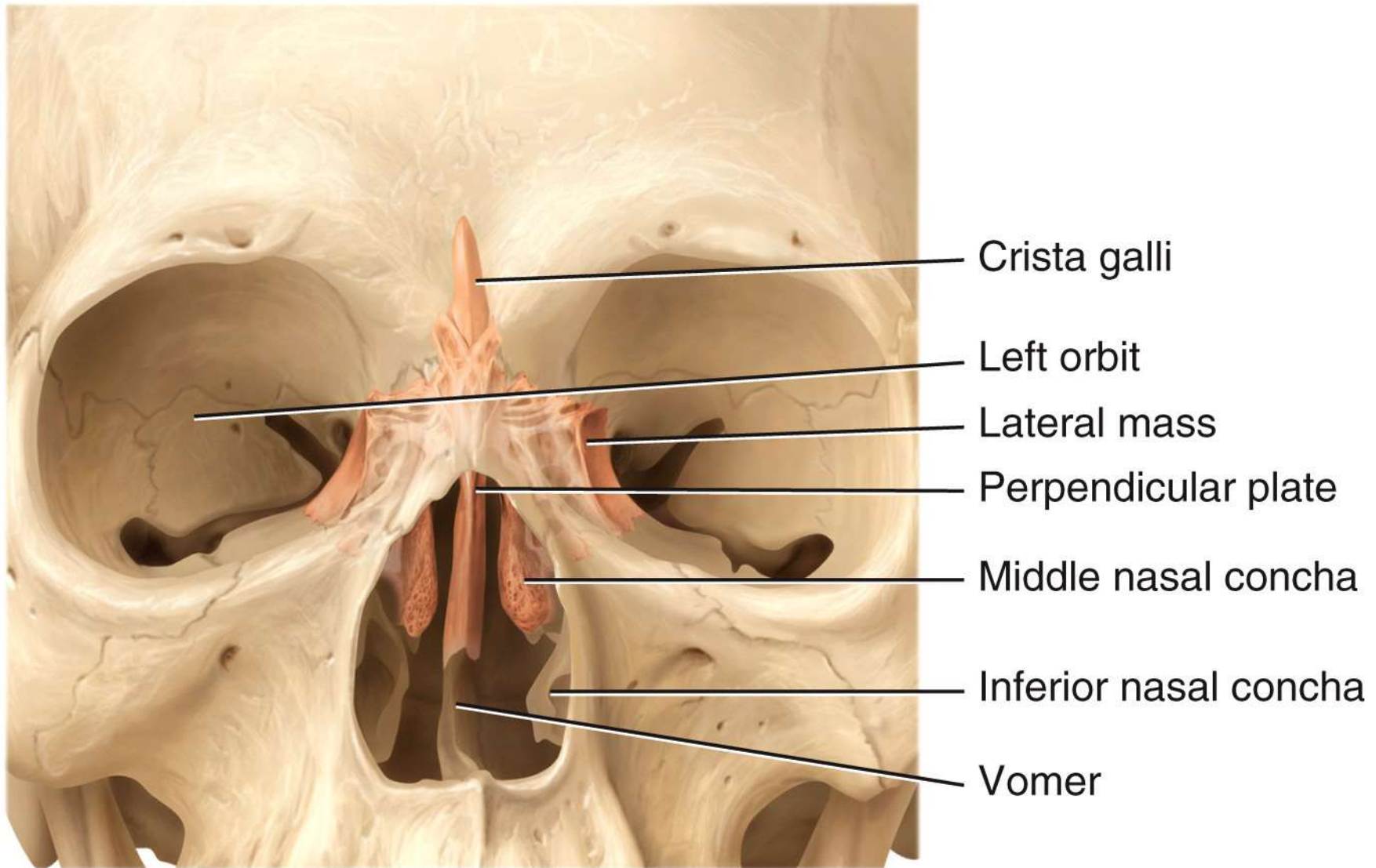
(b) Superior view

SUPERIOR

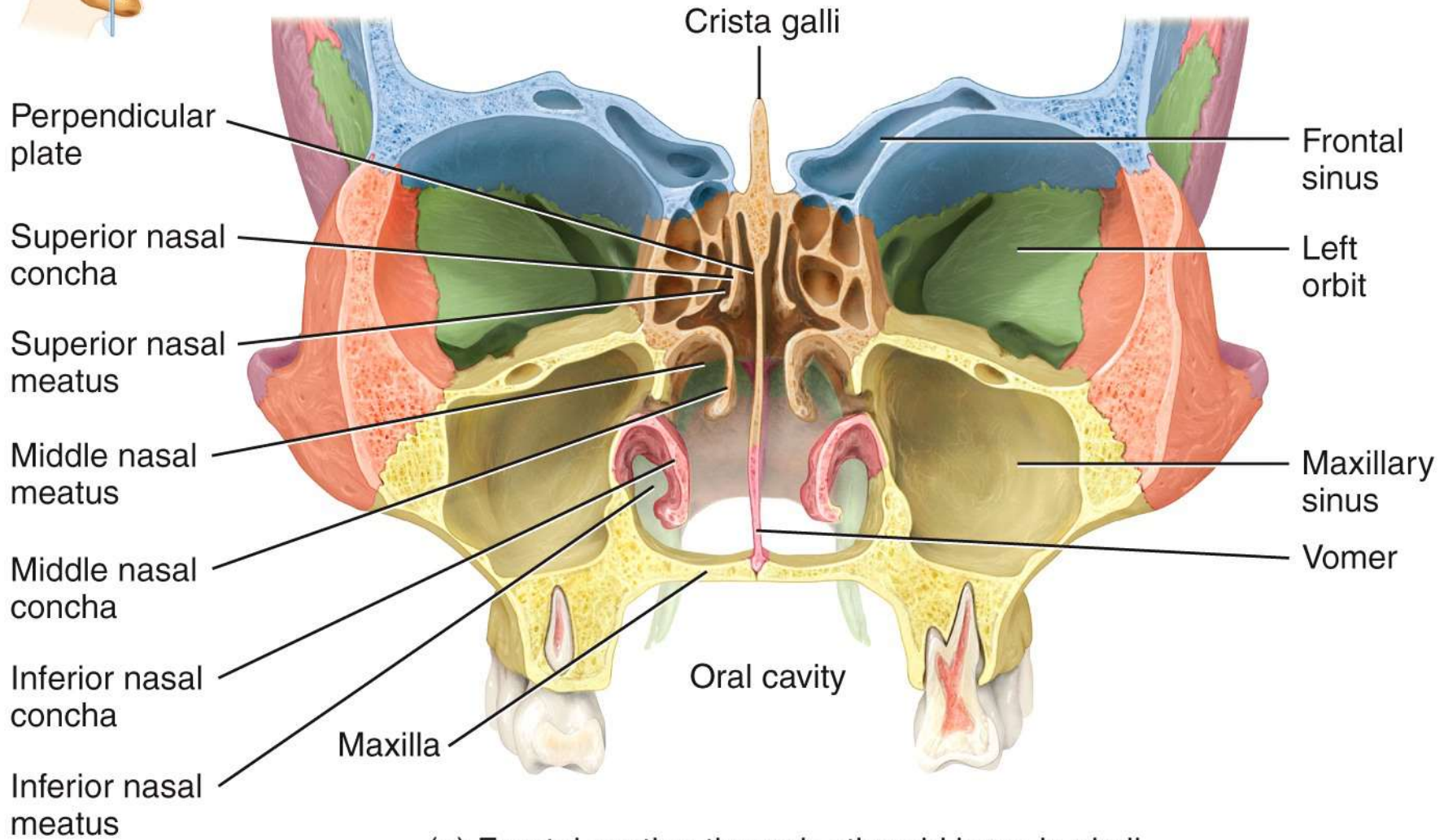
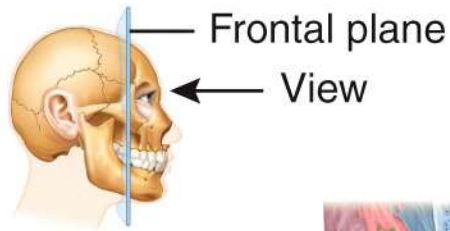


INFERIOR

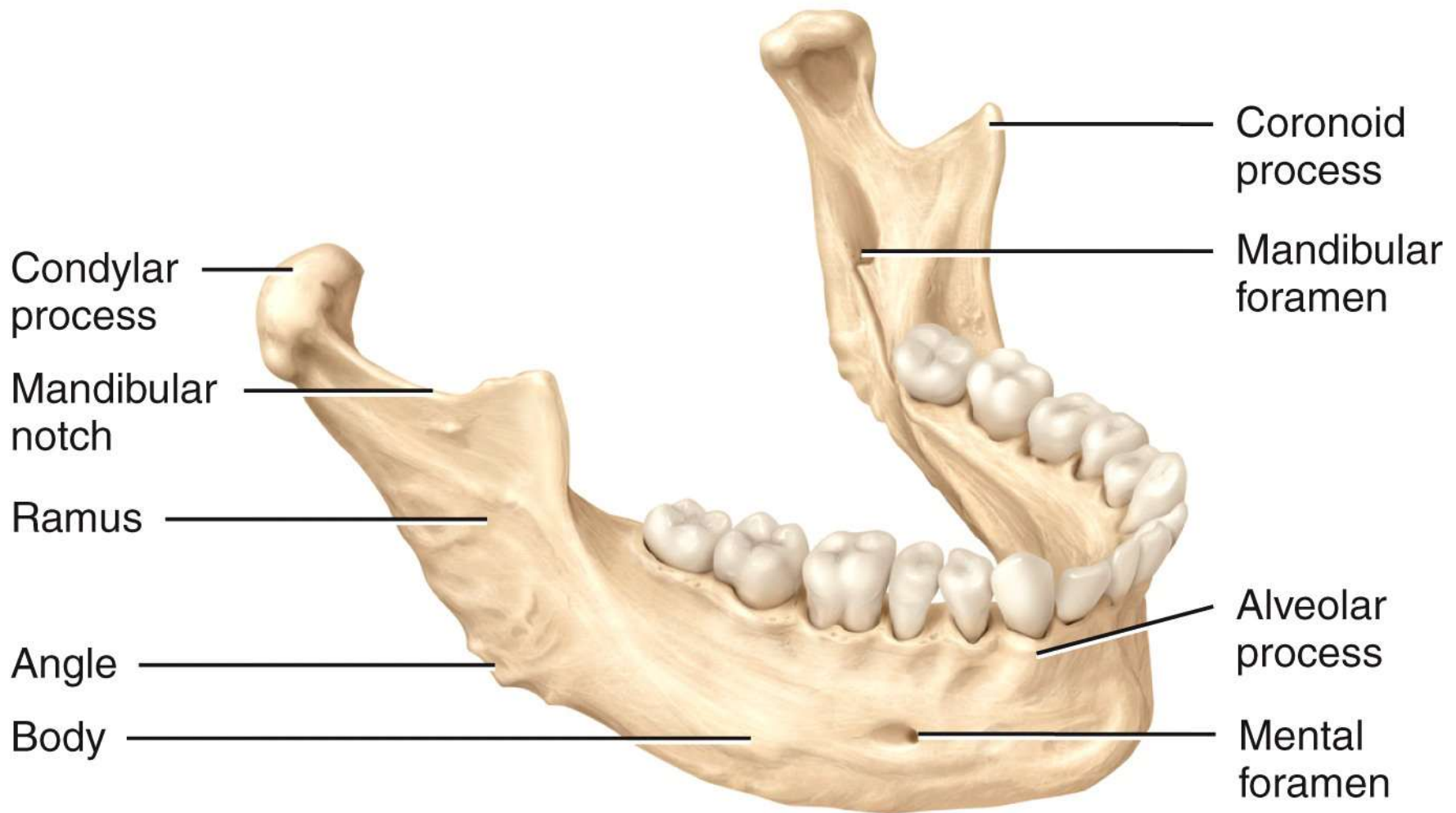
(c) Anterior view



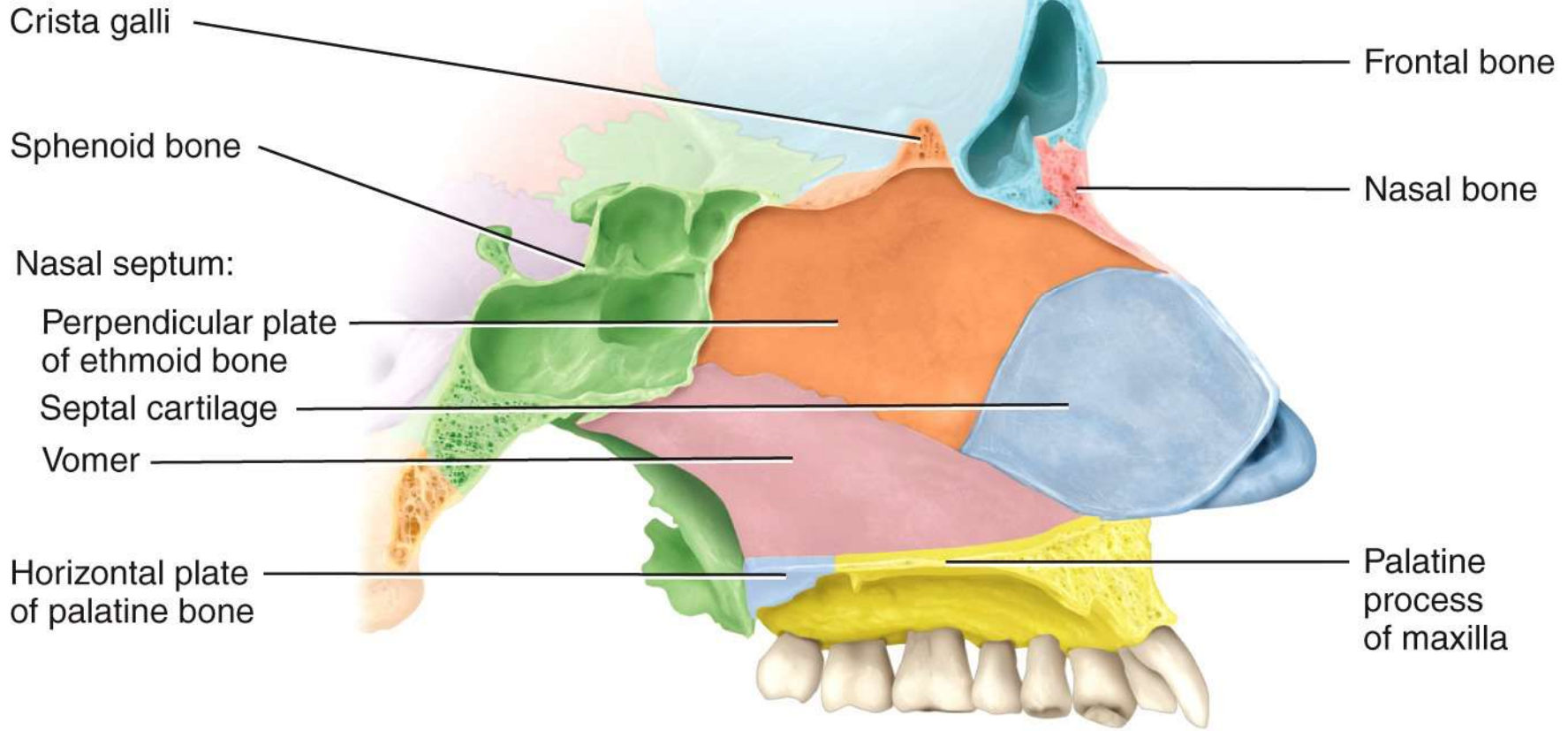
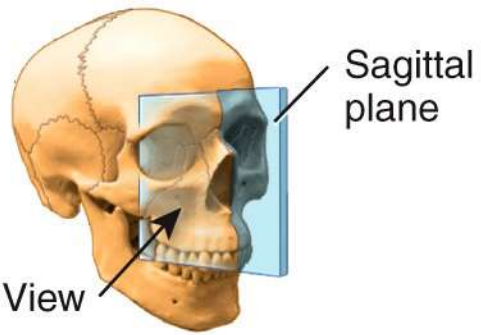
(d) Anterior view of position of ethmoid bone in skull
(projected to the surface)



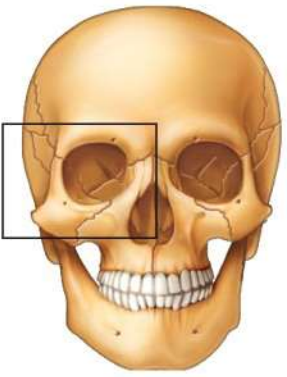
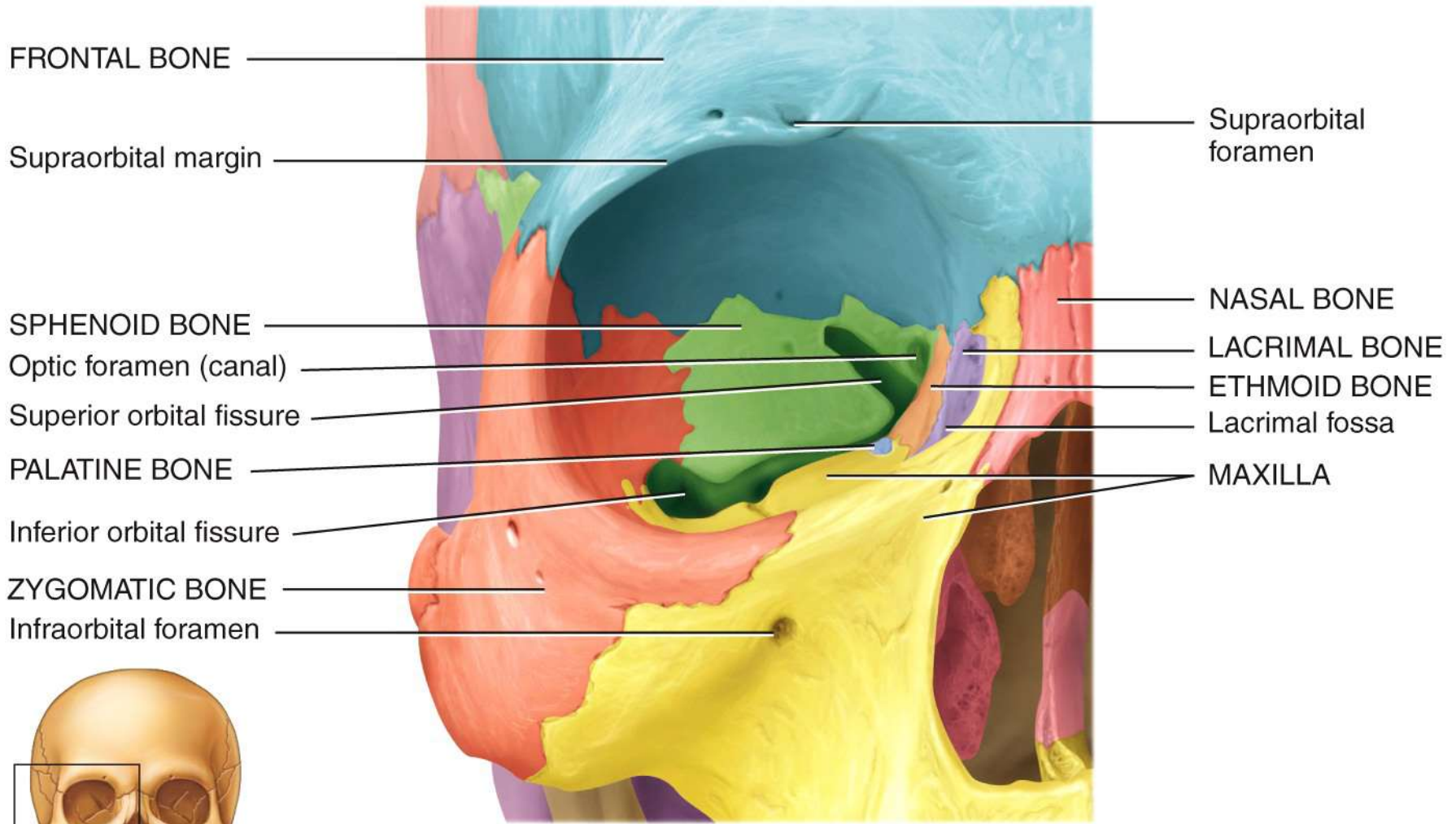
(e) Frontal section through ethmoid bone in skull



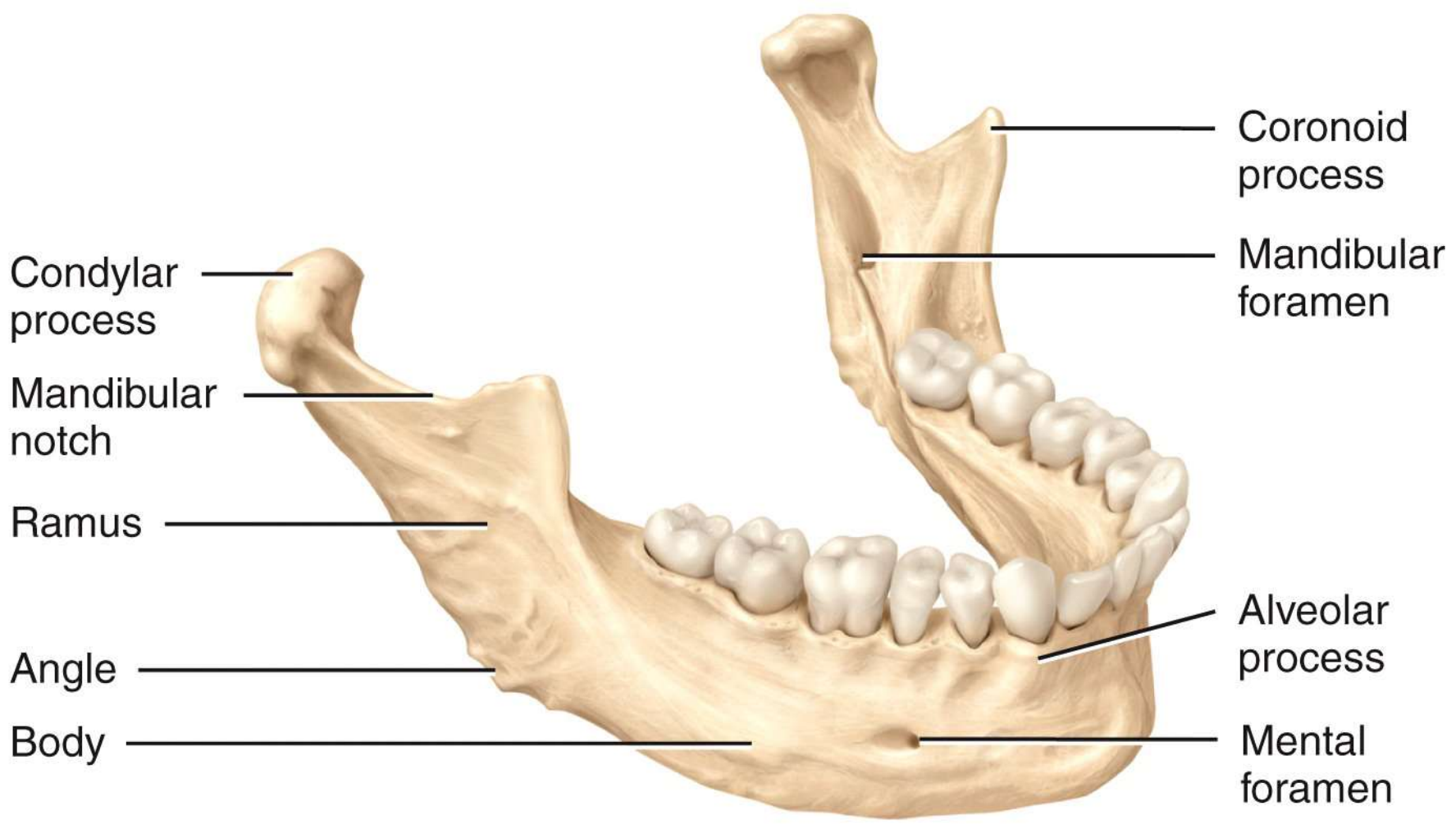
Right lateral view



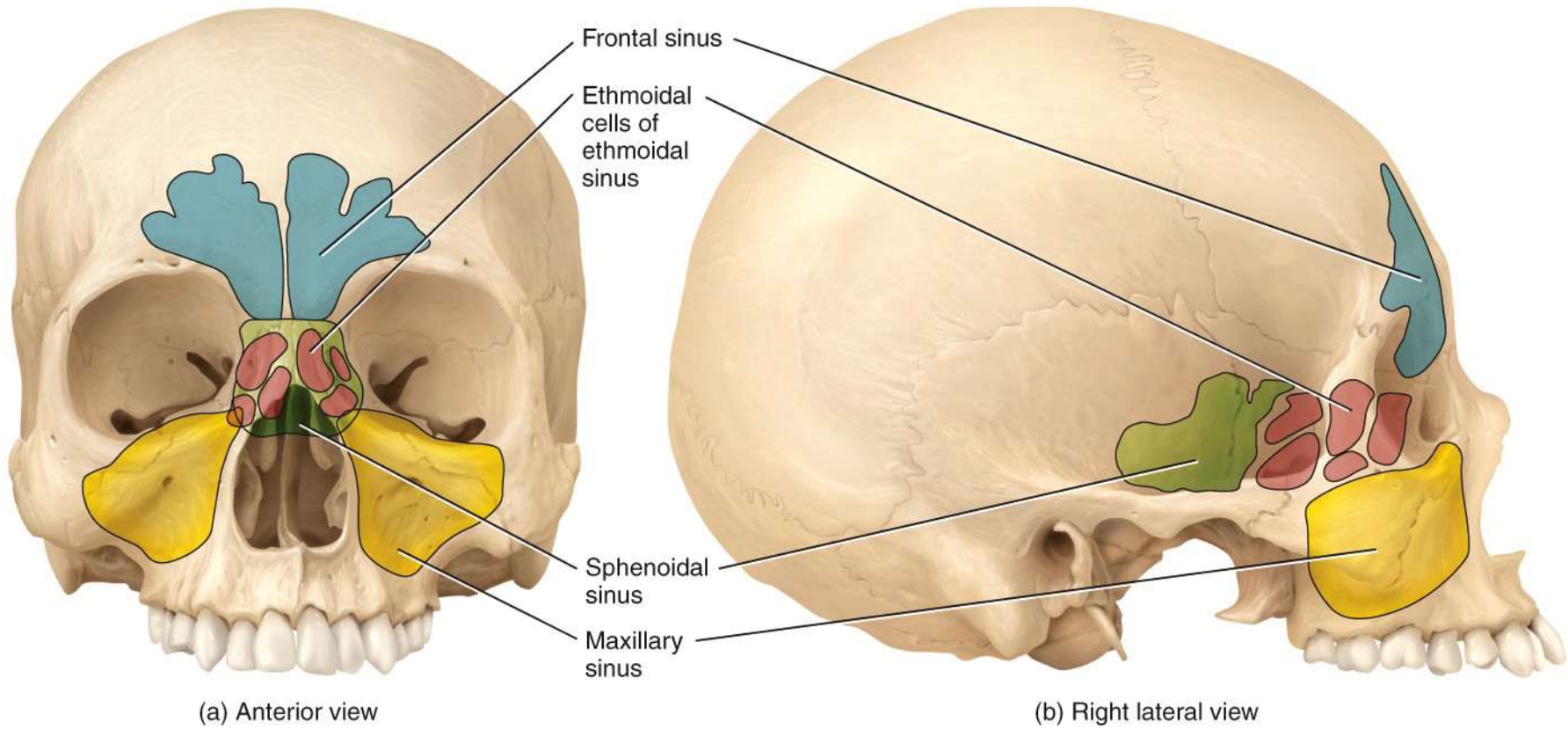
Sagittal section

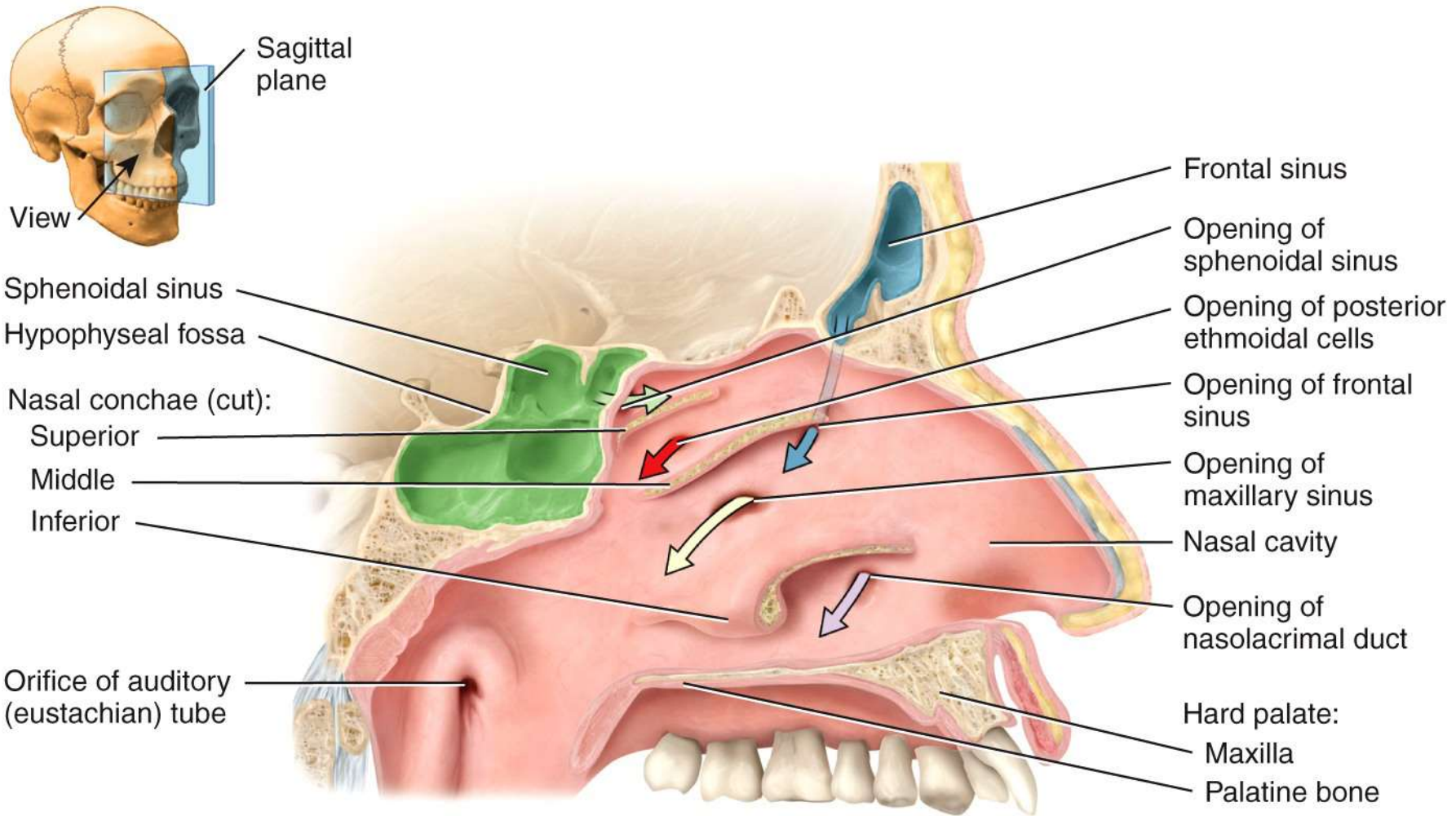


Anterior view showing the bones of the right orbit

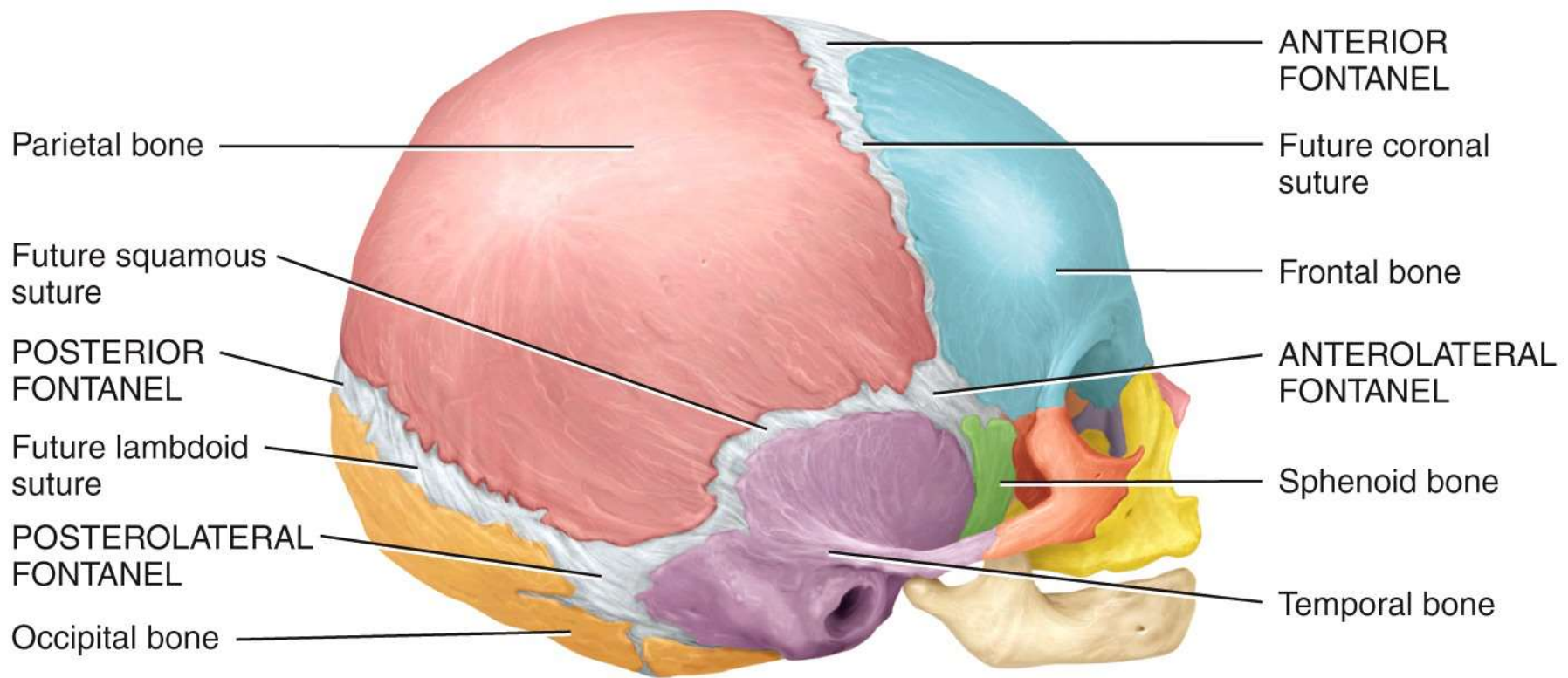


Right lateral view

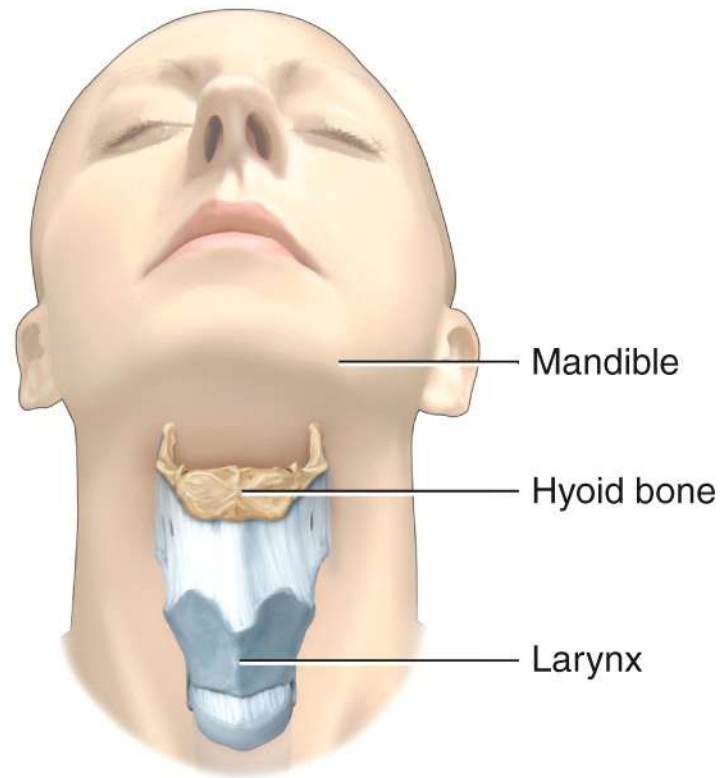




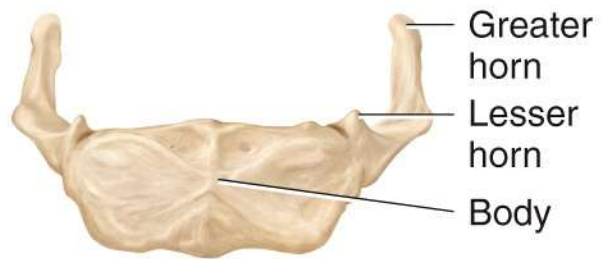
(c) Sagittal section



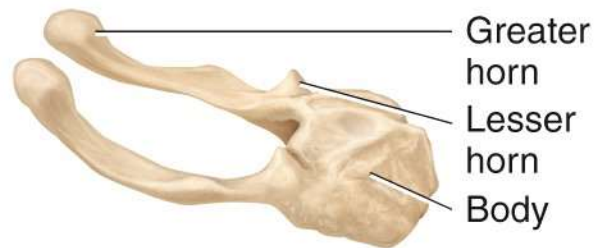
Right lateral view



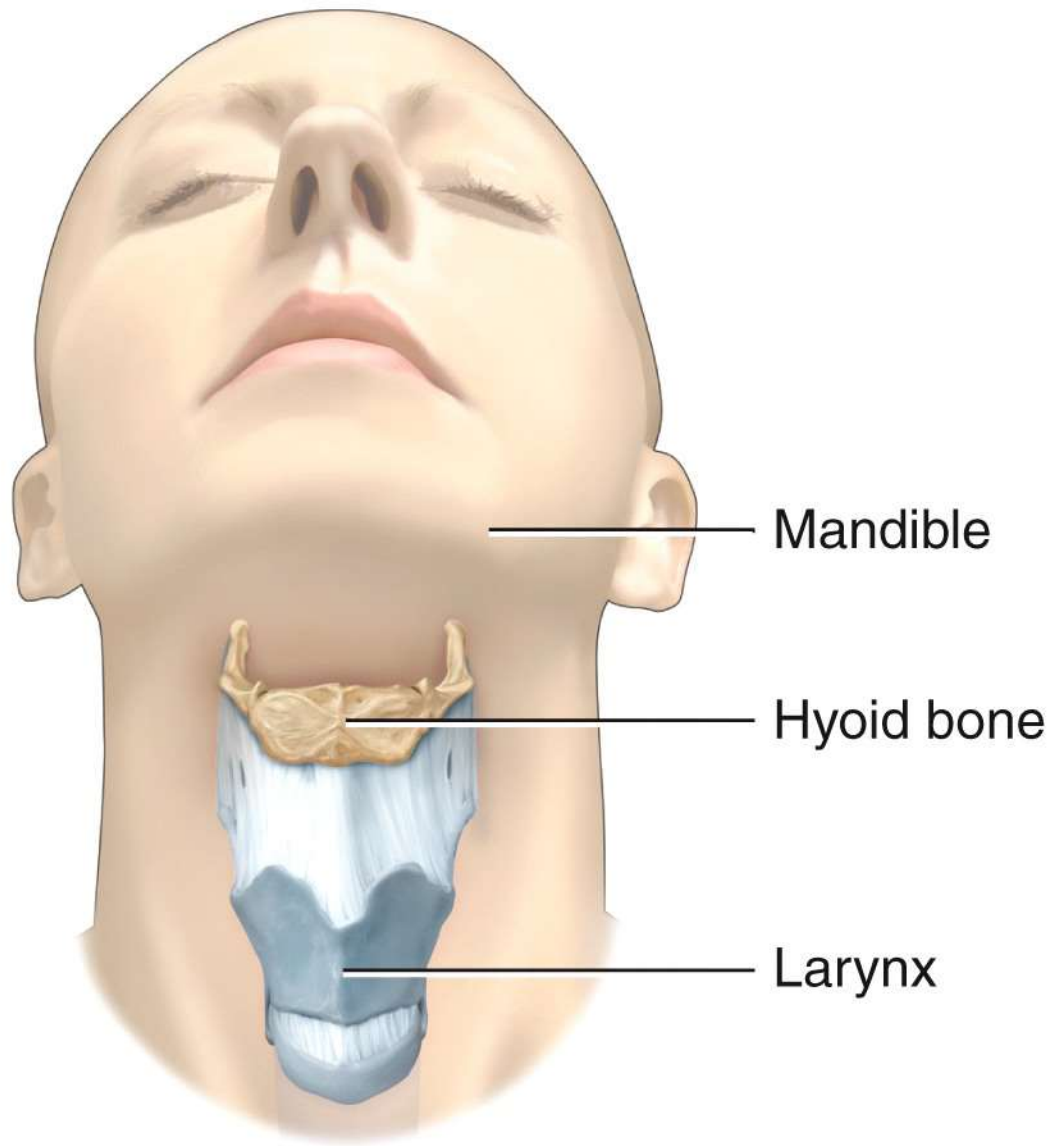
(a) Position of hyoid bone



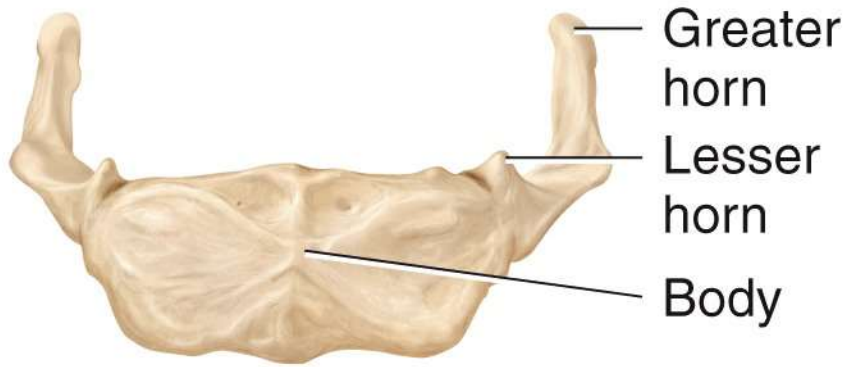
(b) Anterior view



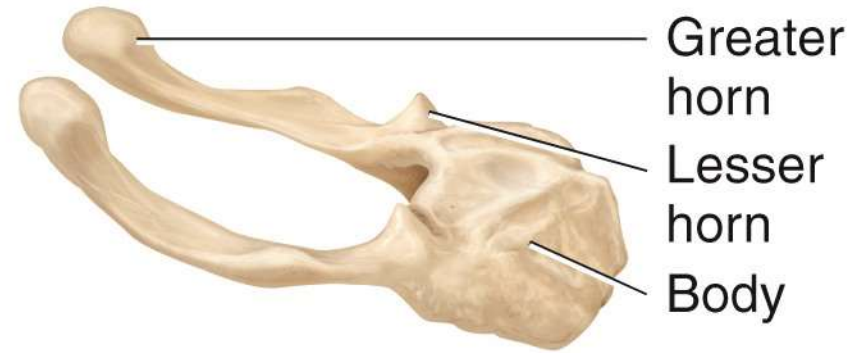
(c) Right lateral view



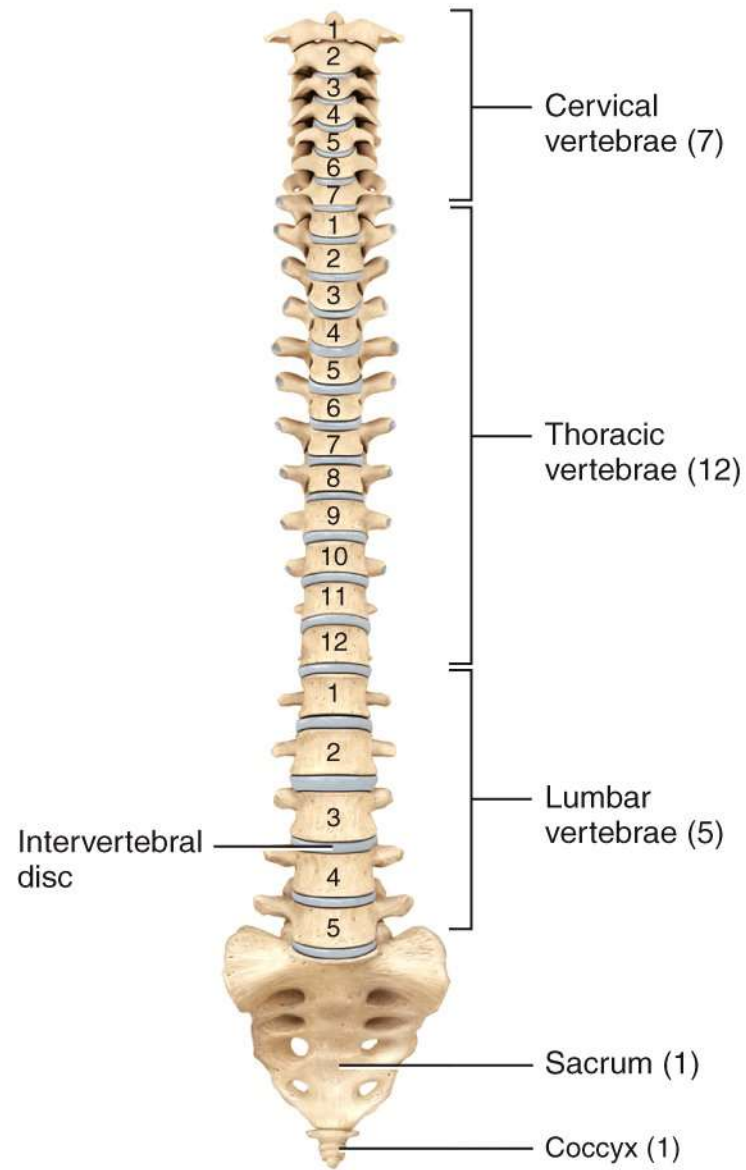
(a) Position of hyoid bone



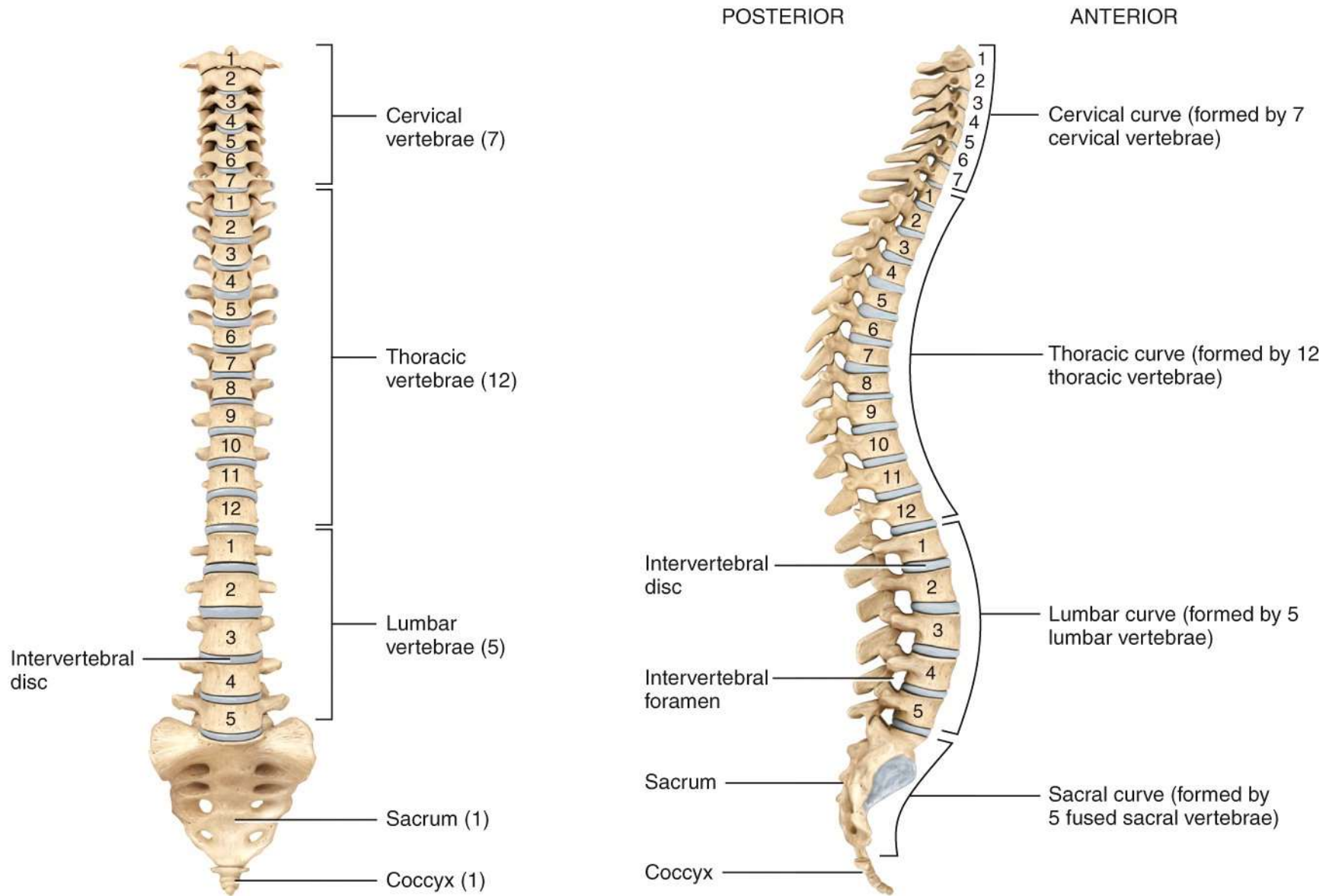
(b) Anterior view



(c) Right lateral view

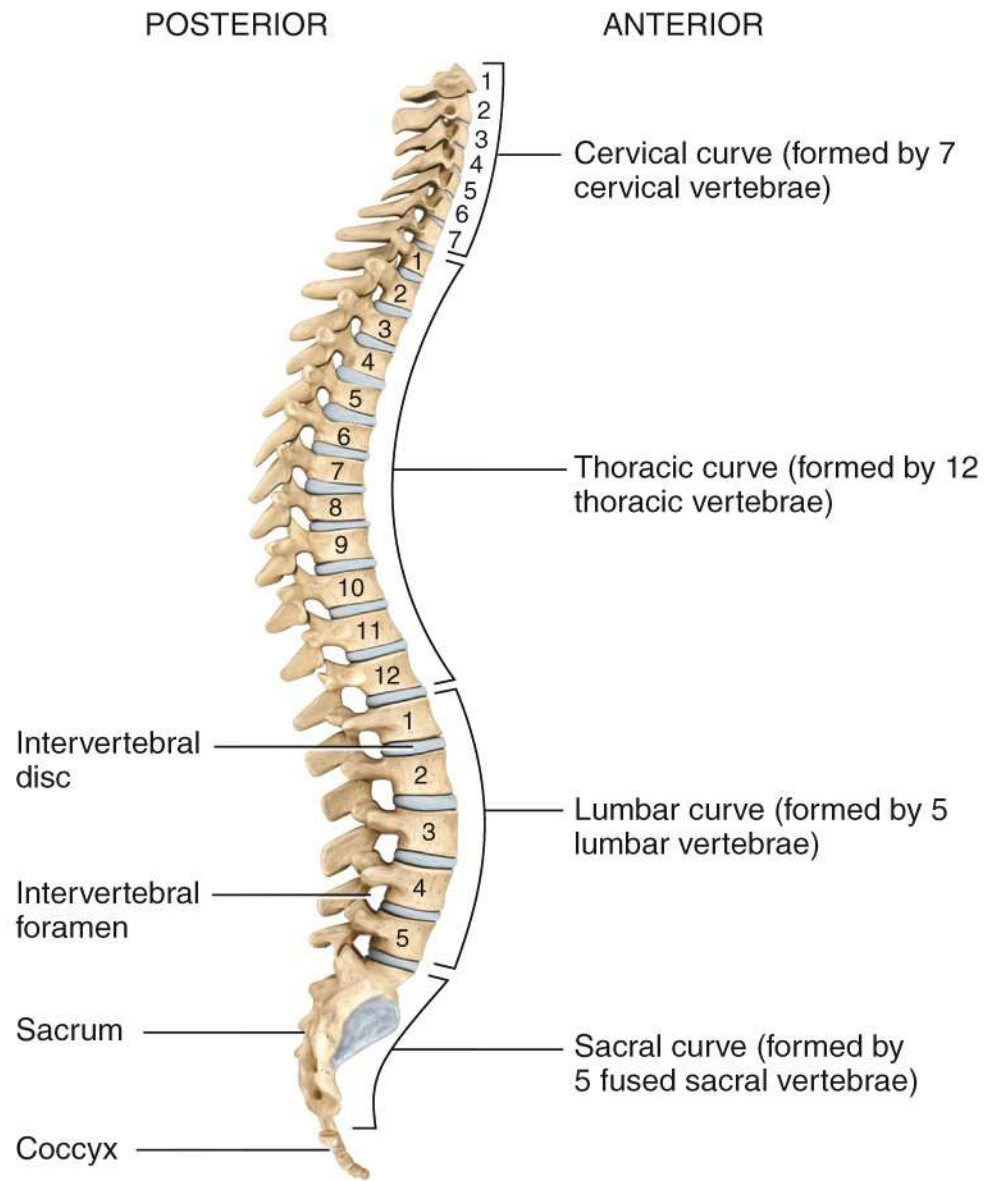


(a) Anterior view showing regions of the vertebral column

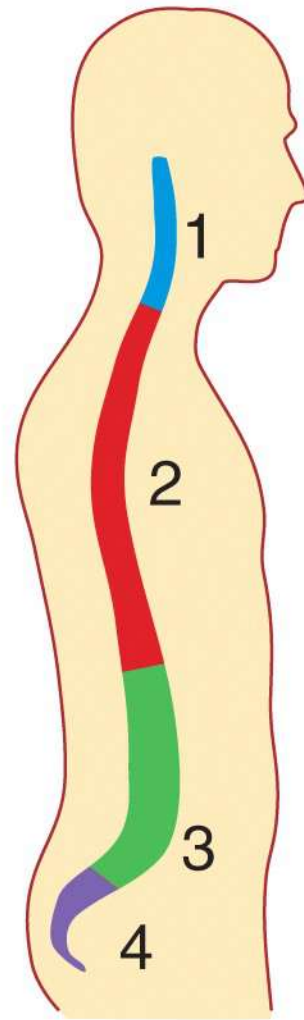
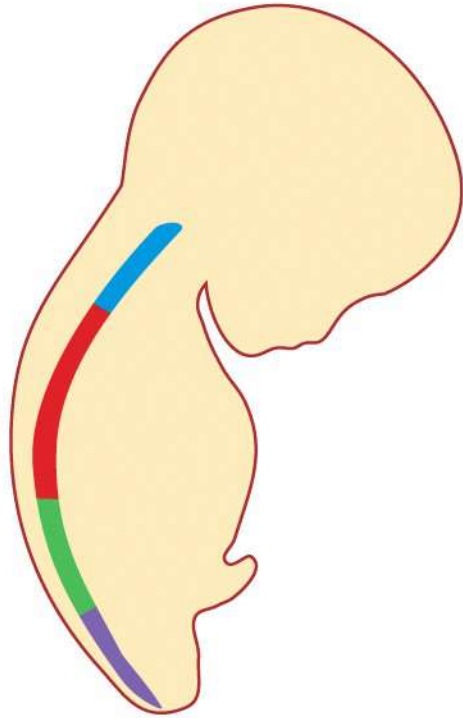


(a) Anterior view showing regions of the vertebral column

(b) Right lateral view showing four normal curves

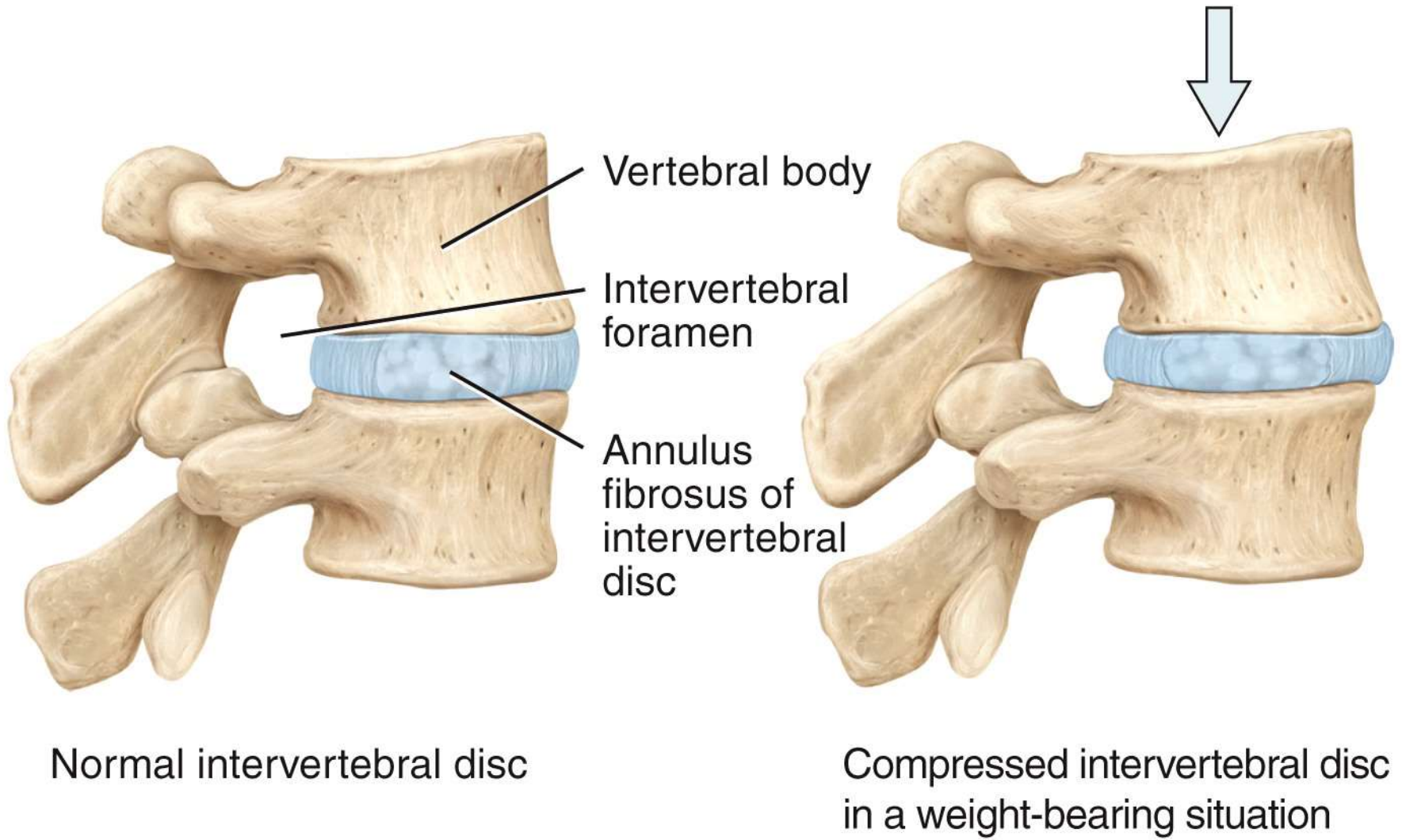


(b) Right lateral view showing four normal curves



Single curve in fetus Four curves in adult

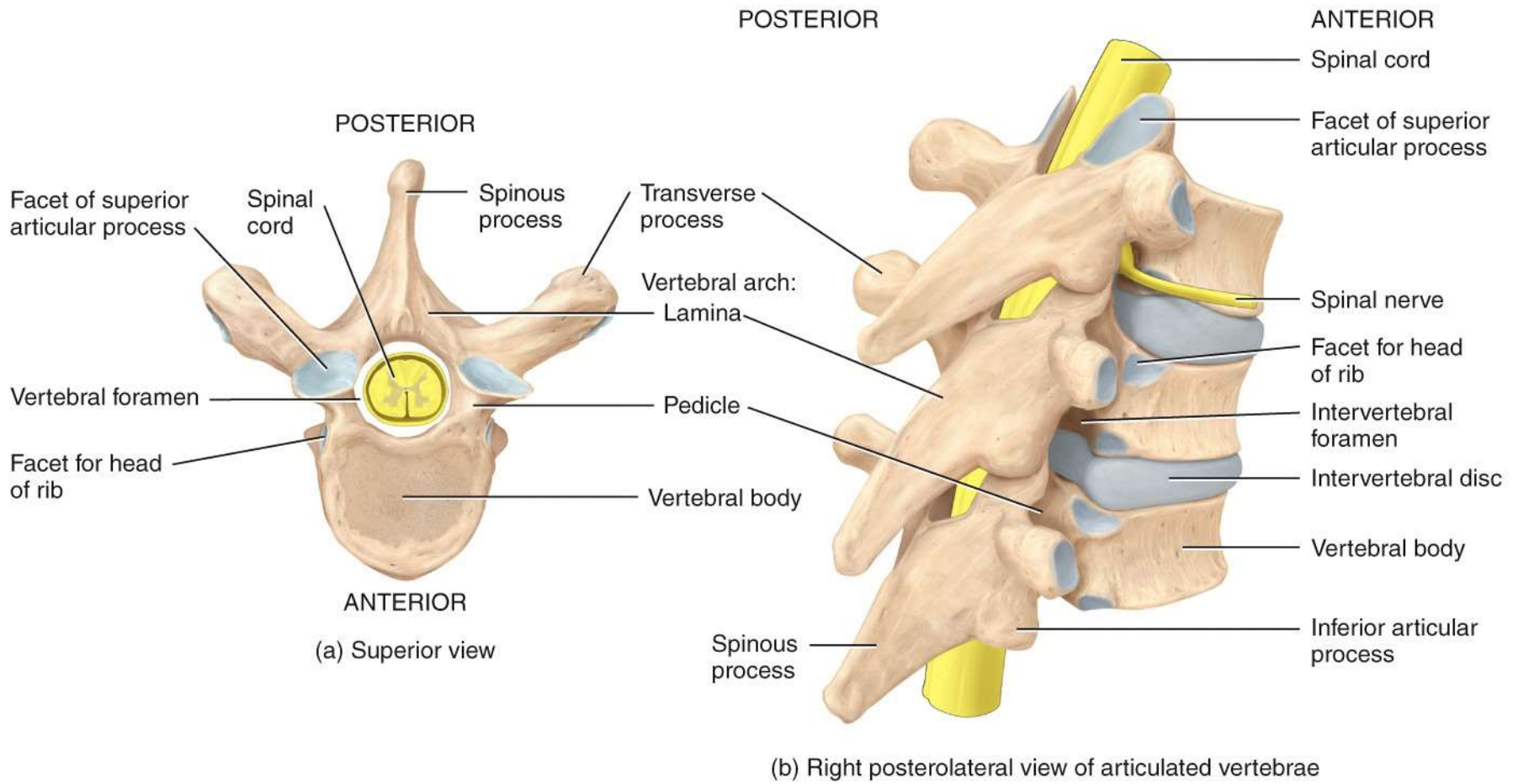
(c) Fetal and adult curves

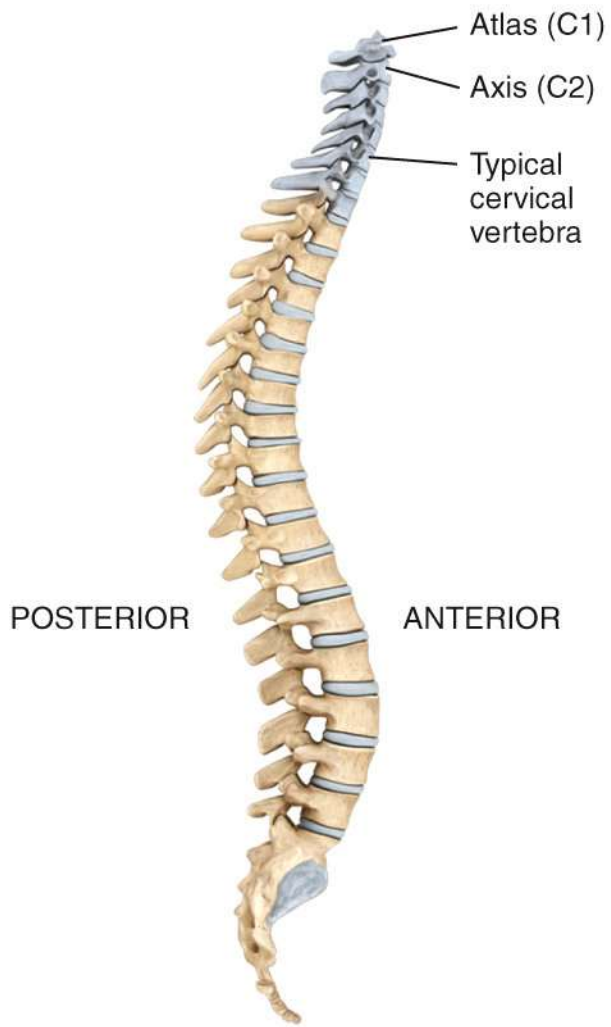


Normal intervertebral disc

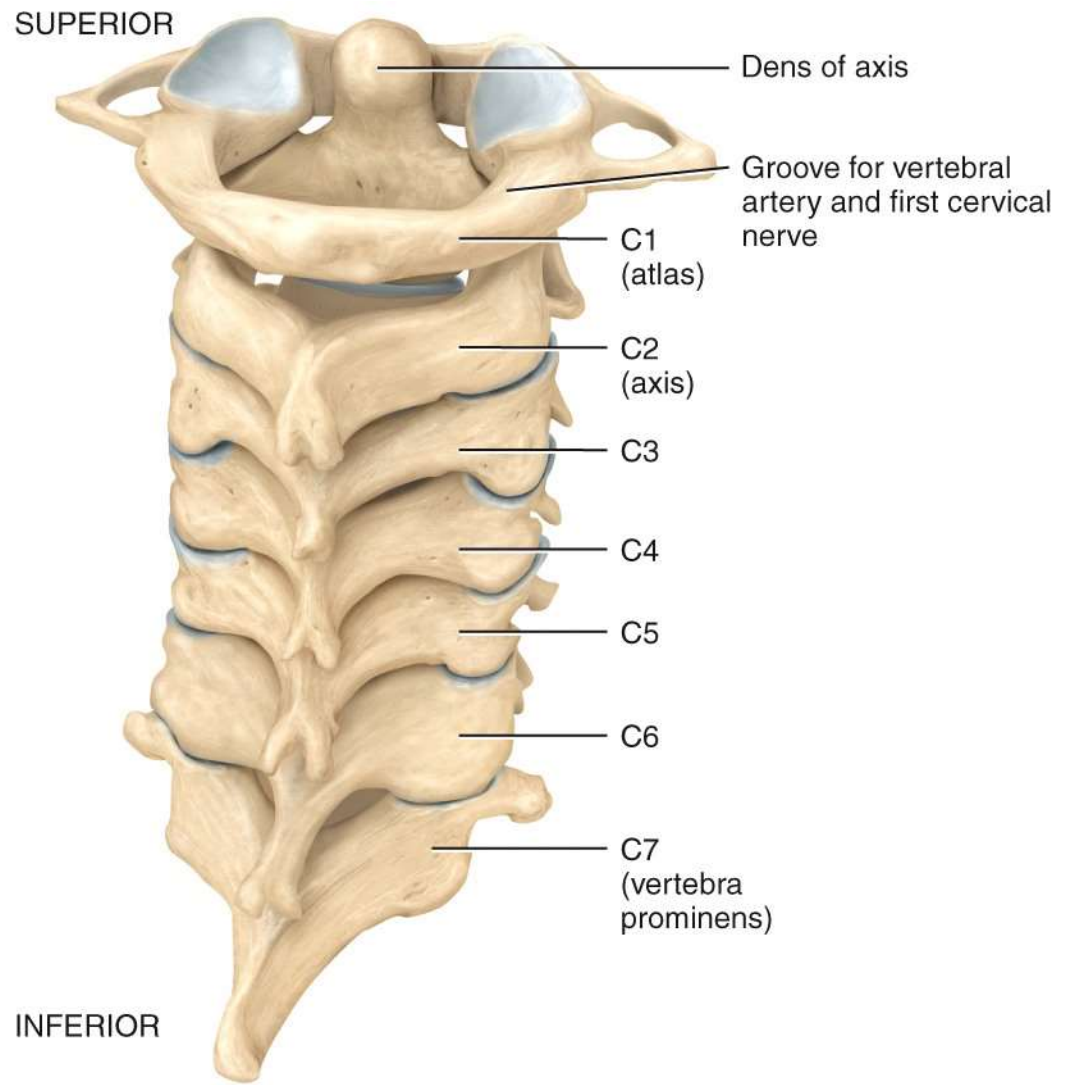
Compressed intervertebral disc
in a weight-bearing situation

(d) Intervertebral disc





Location of cervical vertebrae



(a) Posterior view of articulated cervical vertebrae

POSTERIOR

Posterior arch

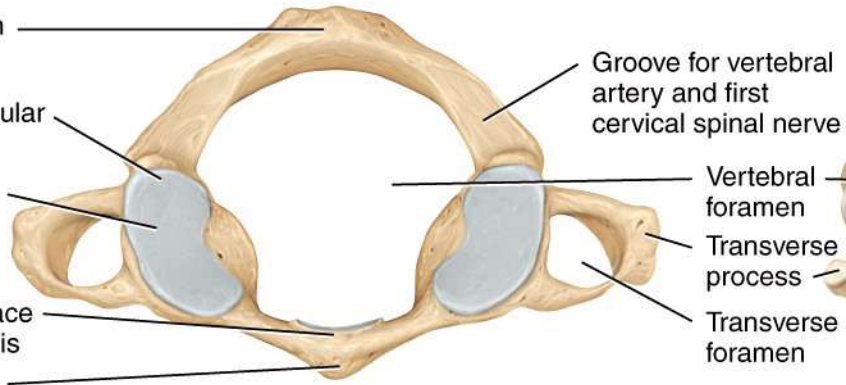
Superior articular facet

Lateral mass

Articular surface for dens of axis

Anterior arch

ANTERIOR



(b) Superior view of atlas (C1)

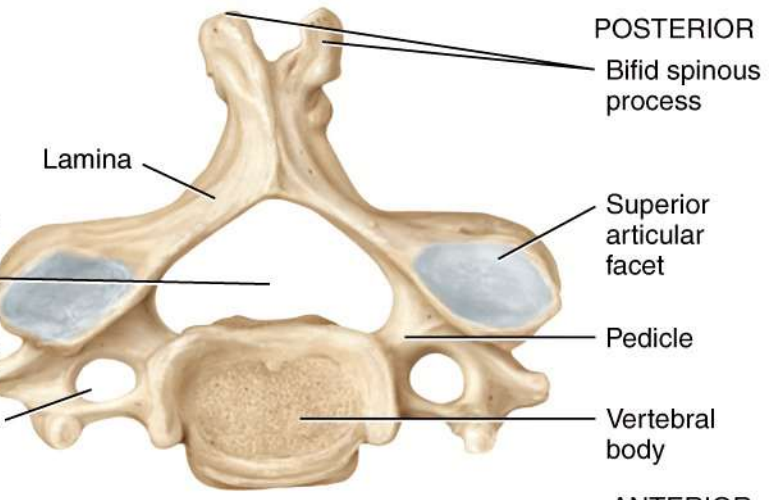
Groove for vertebral artery and first cervical spinal nerve

Vertebral foramen

Transverse process

Transverse foramen

Lamina



POSTERIOR

Bifid spinous process

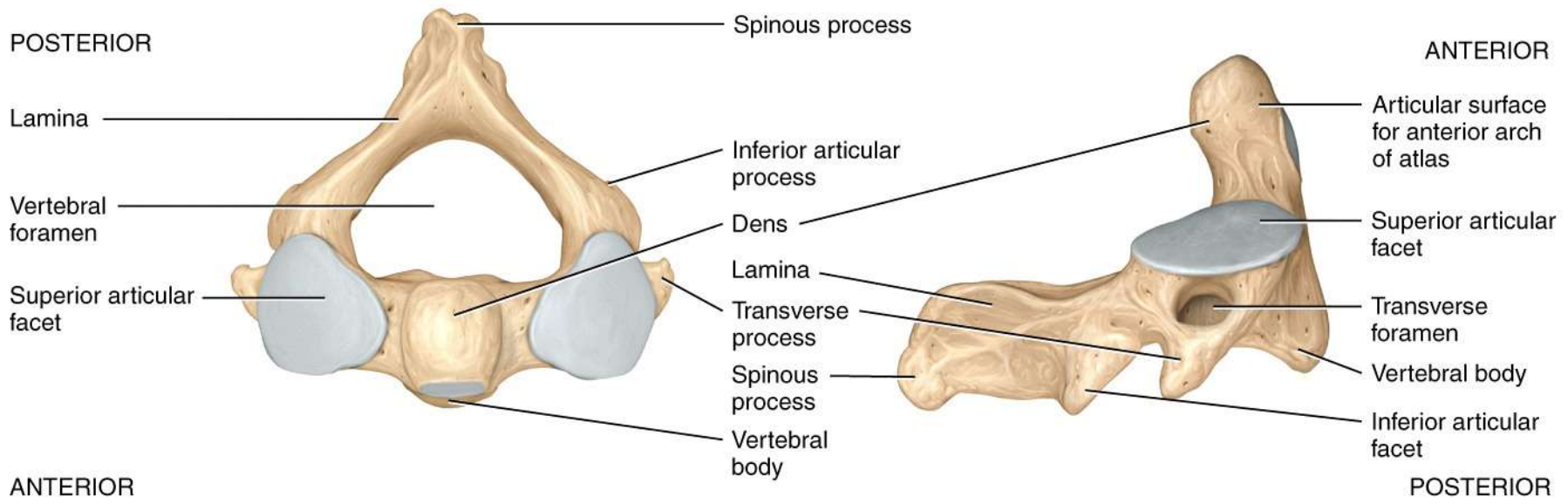
Superior articular facet

Pedicle

Vertebral body

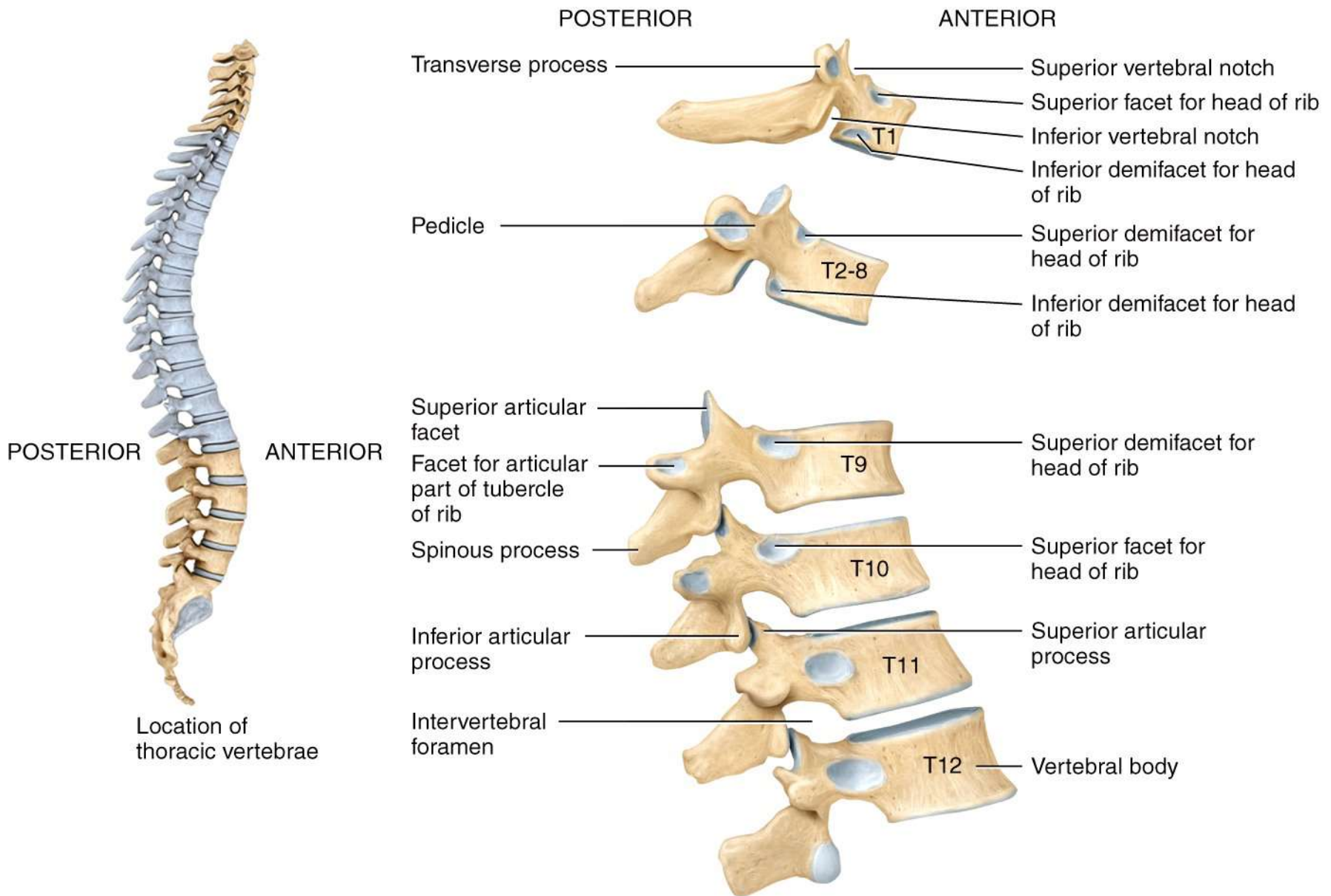
ANTERIOR

(c) Superior view of a typical cervical vertebra

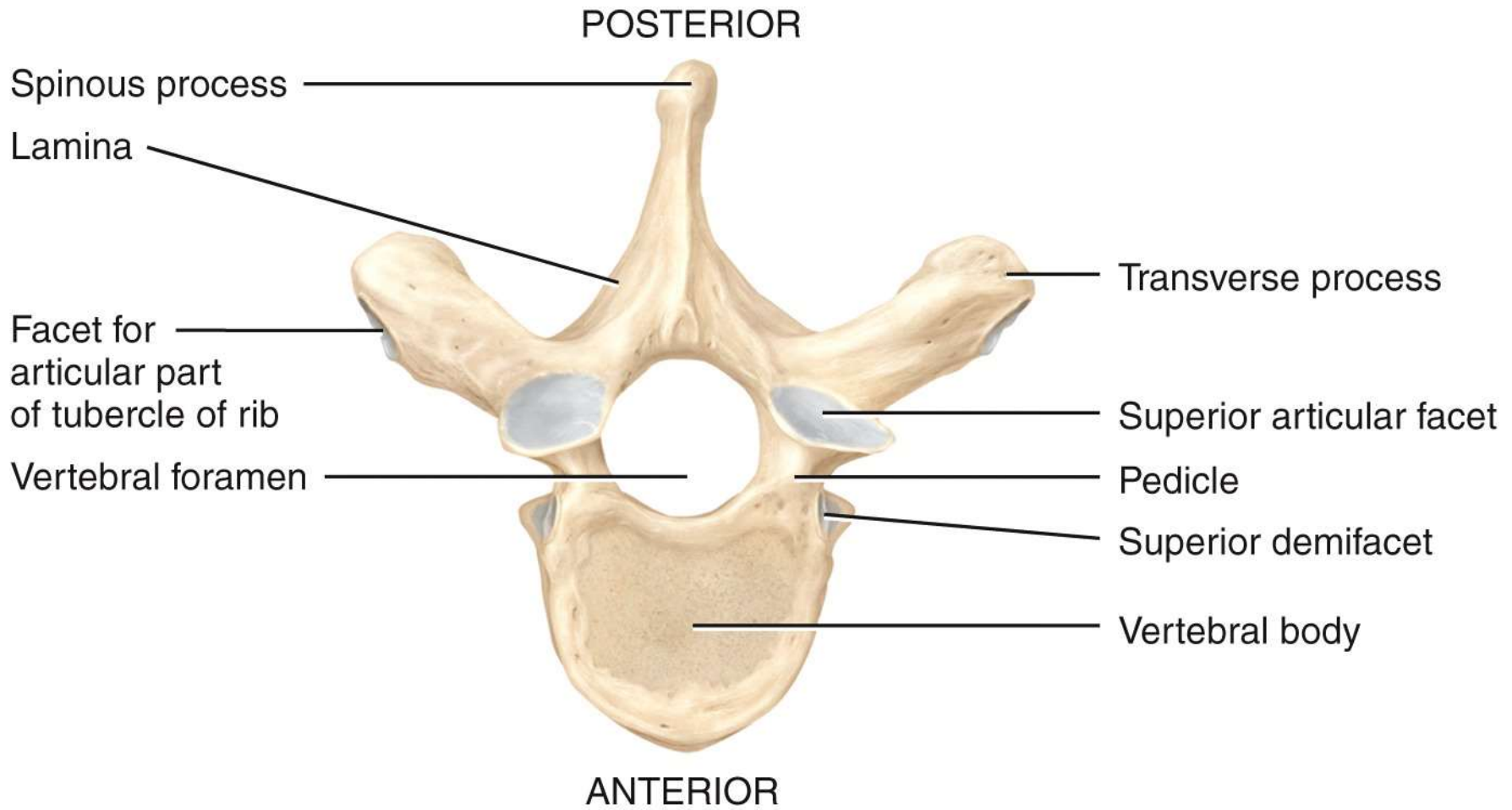


(d) Superior view of axis (C2)

(e) Right lateral view of axis (C2)



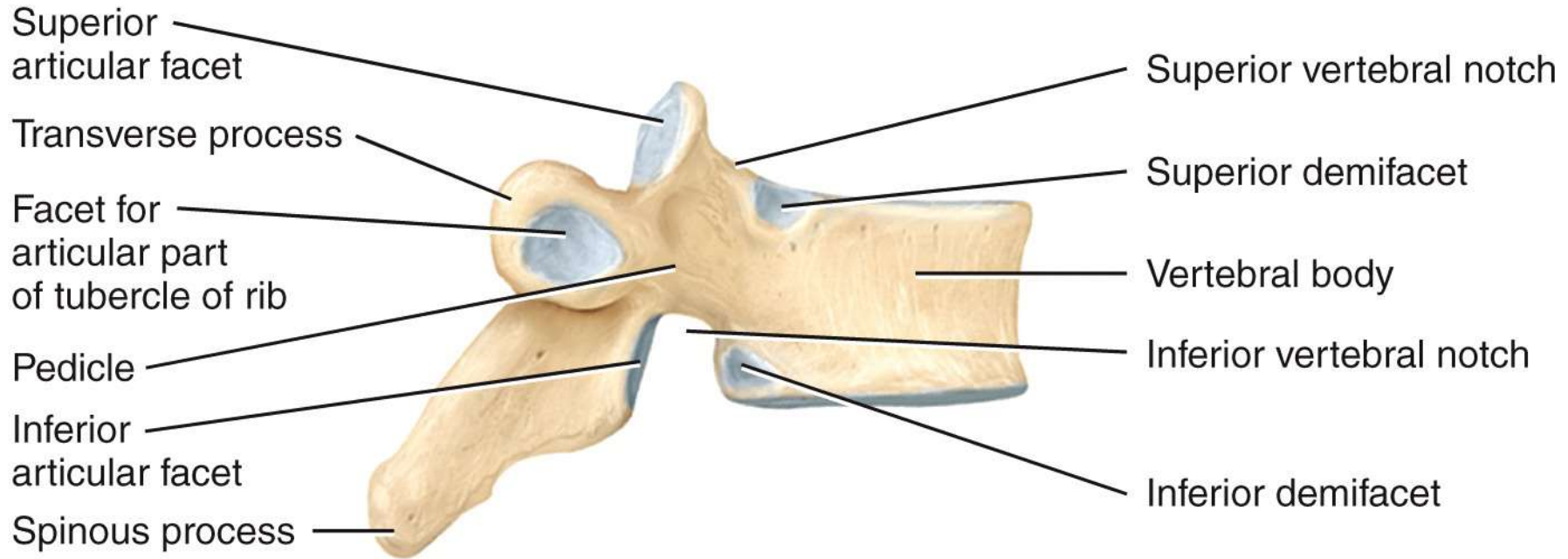
(a) Right lateral view of several articulated thoracic vertebrae



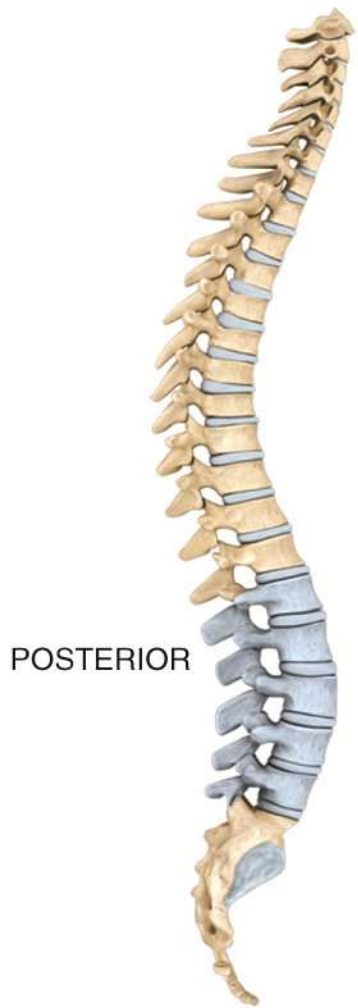(b) Superior view

POSTERIOR

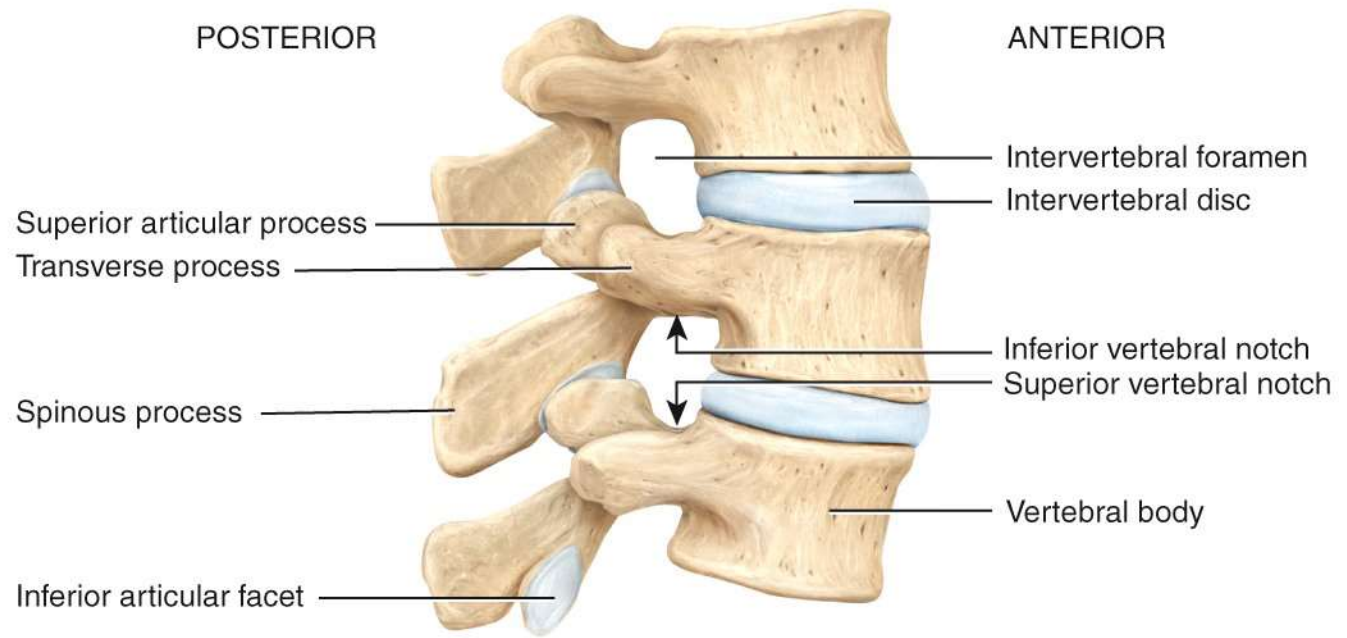
ANTERIOR



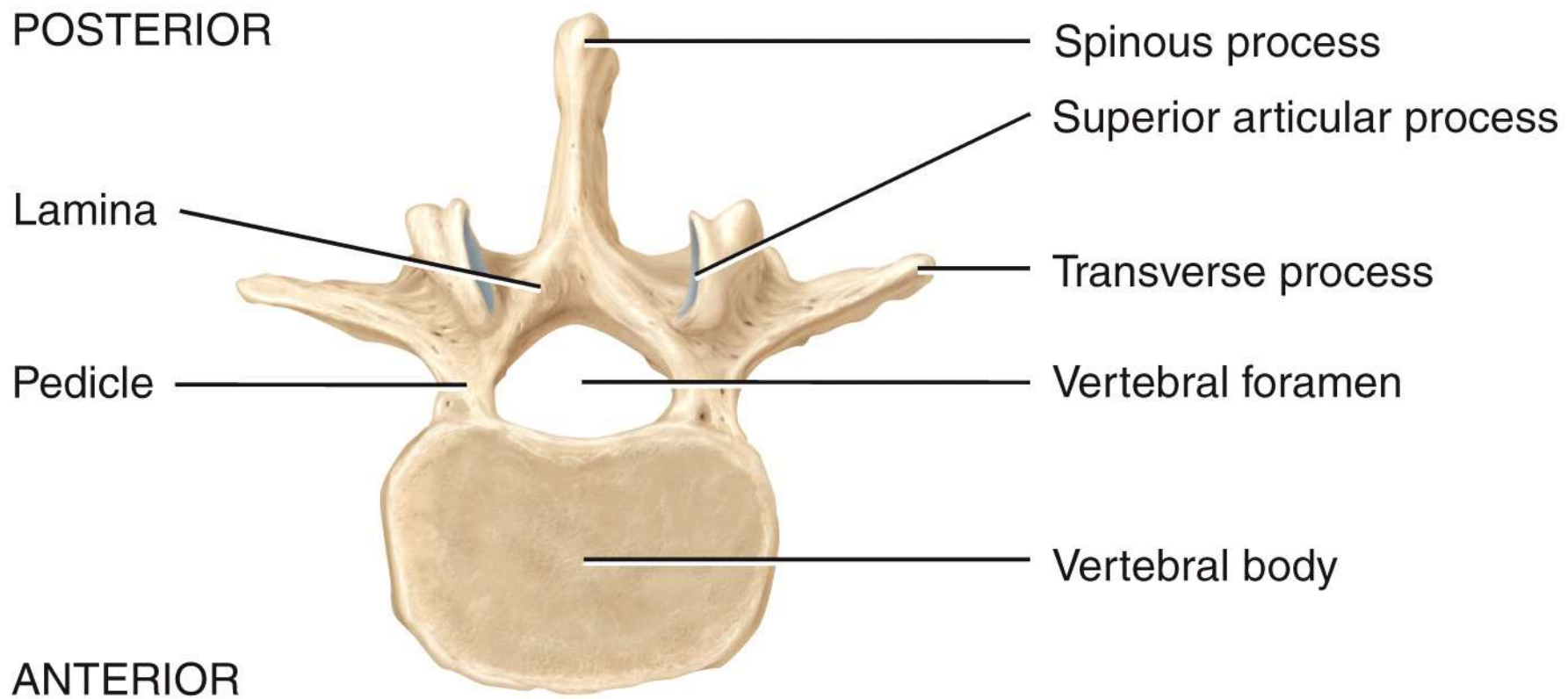
(c) Right lateral view



Location of lumbar vertebrae



(a) Right lateral view of articulated lumbar vertebrae



(b) Superior view

POSTERIOR

ANTERIOR

Superior articular process

Transverse process

Spinous process

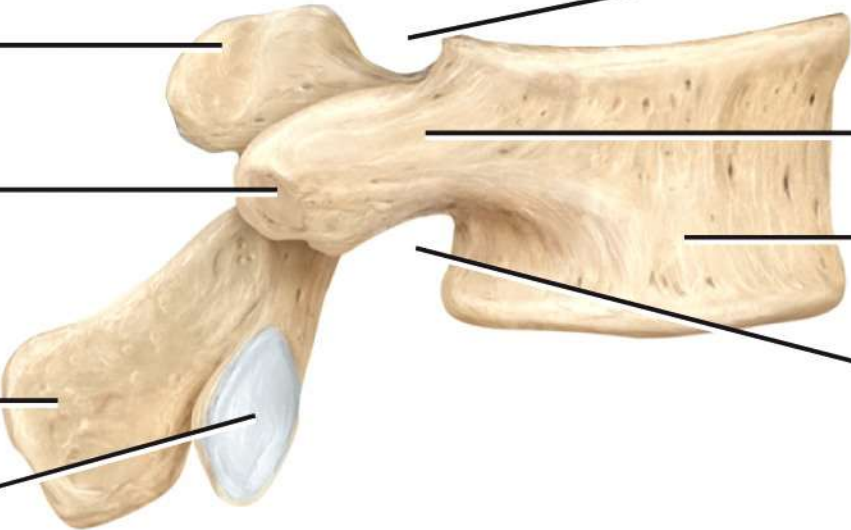
Inferior articular facet

Superior vertebral notch

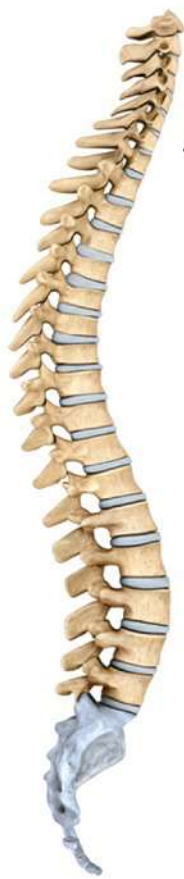Pedicle

Vertebral body

Inferior vertebral notch

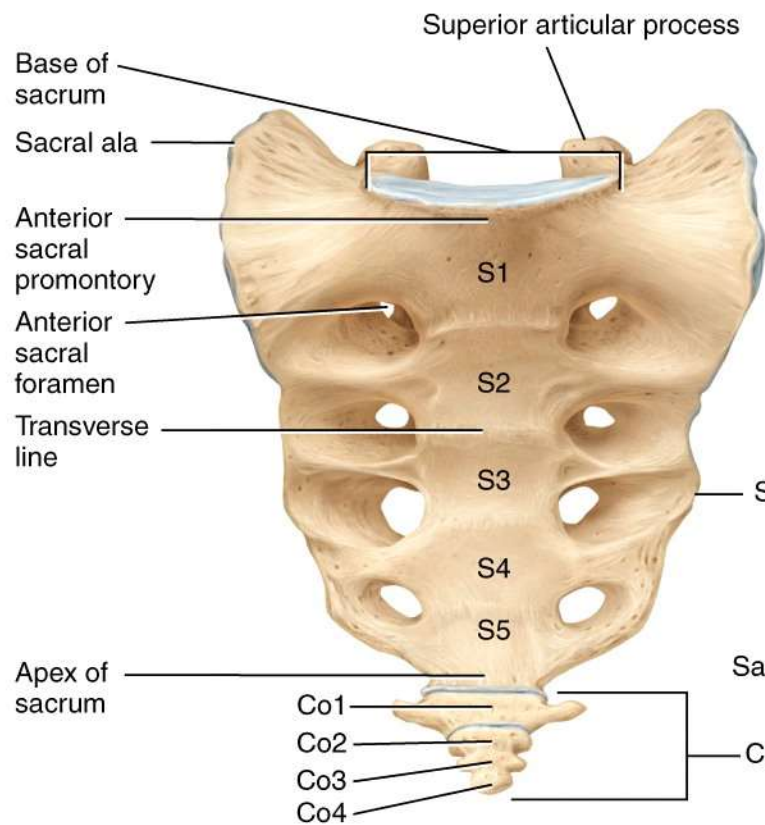


(c) Right lateral view

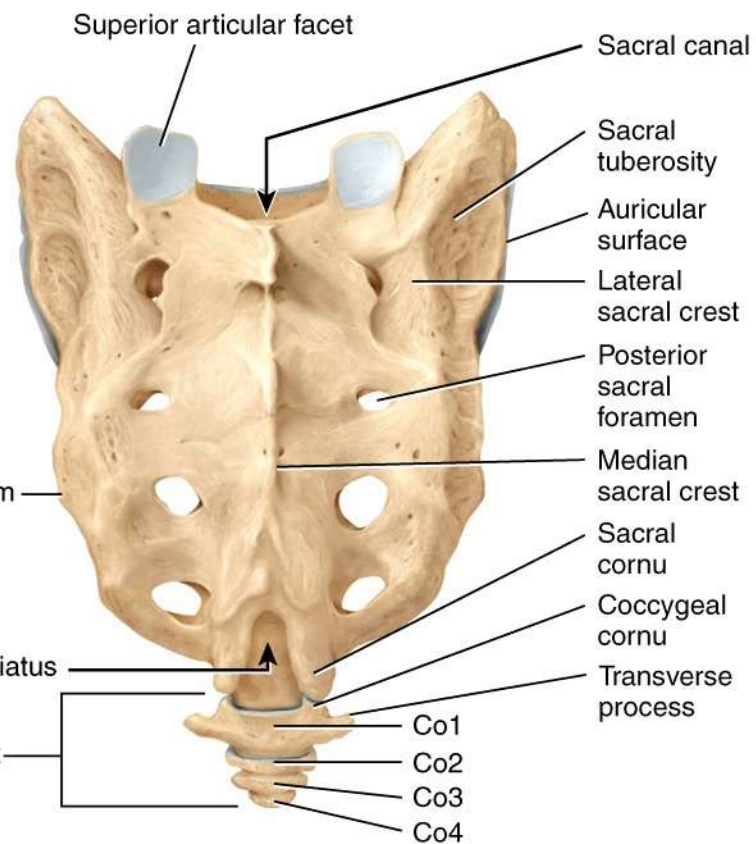


Location of sacrum and coccyx

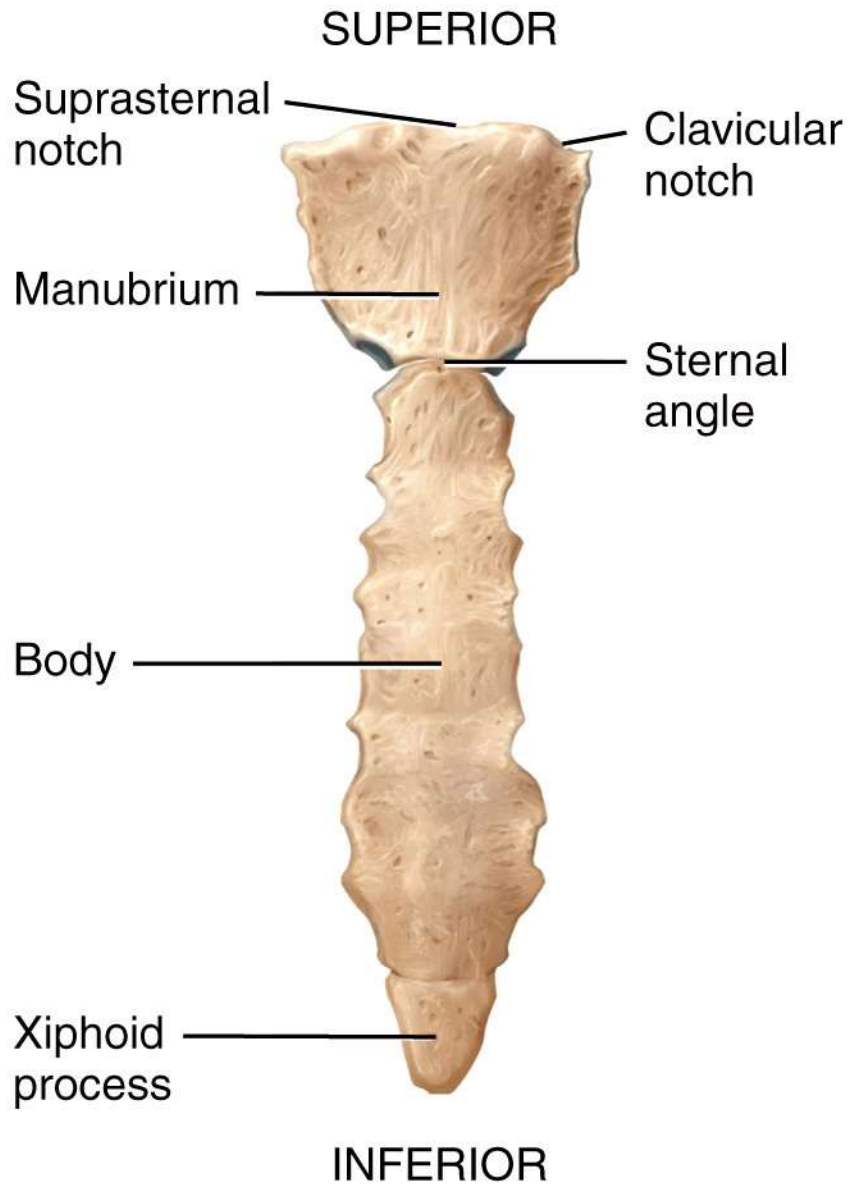
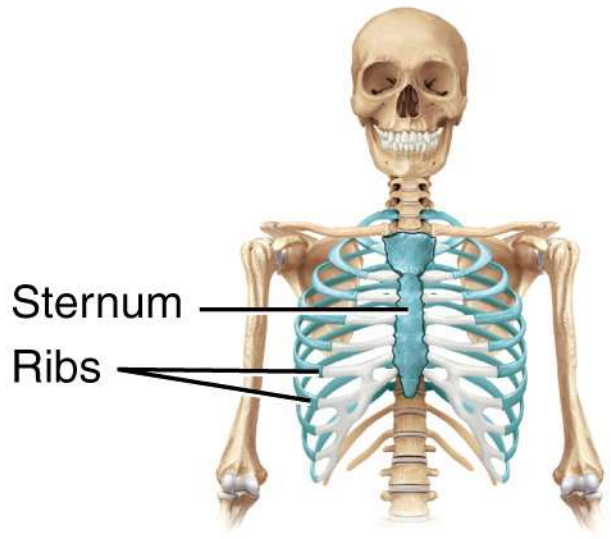
ANTERIOR



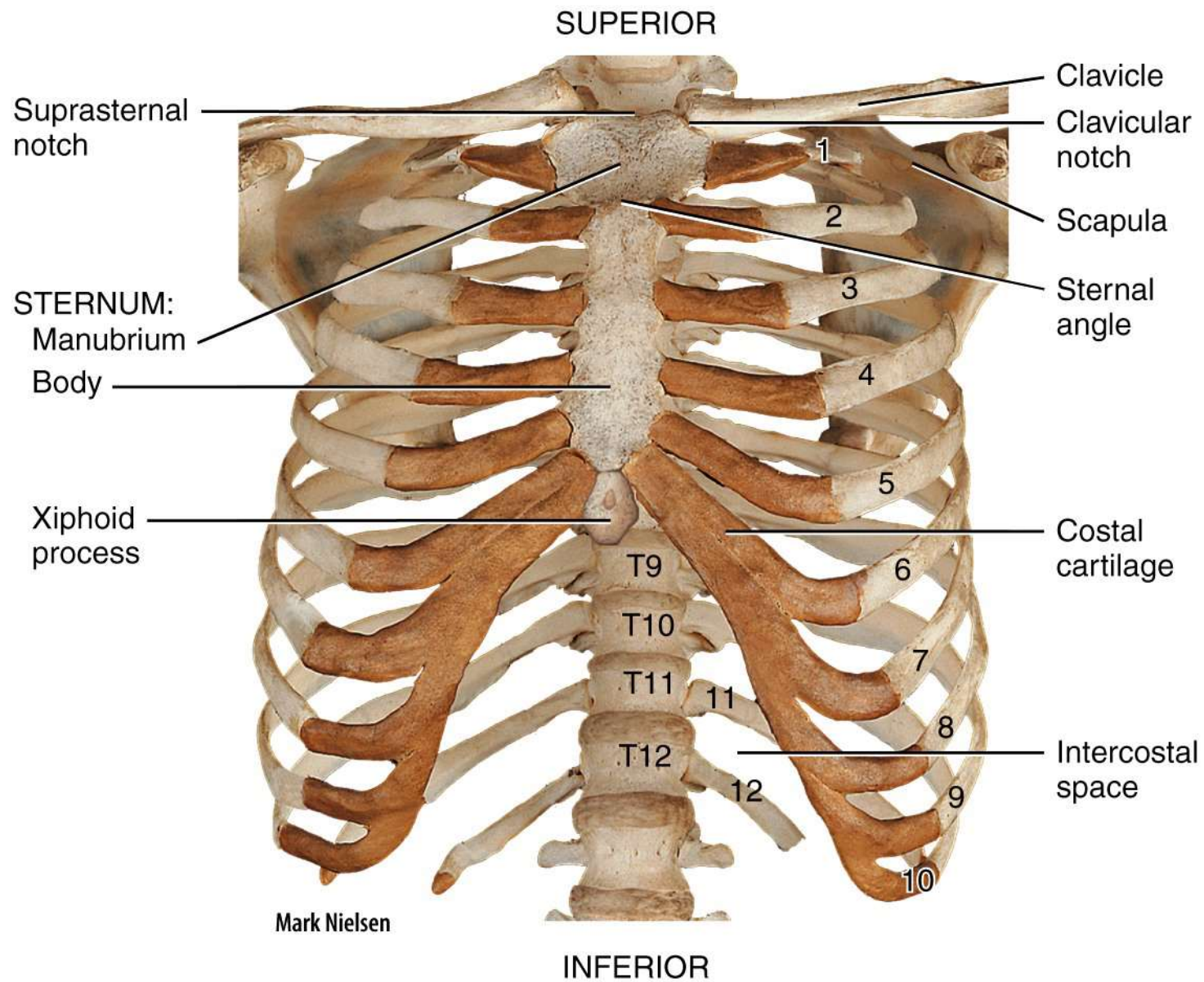
(a) Anterior view



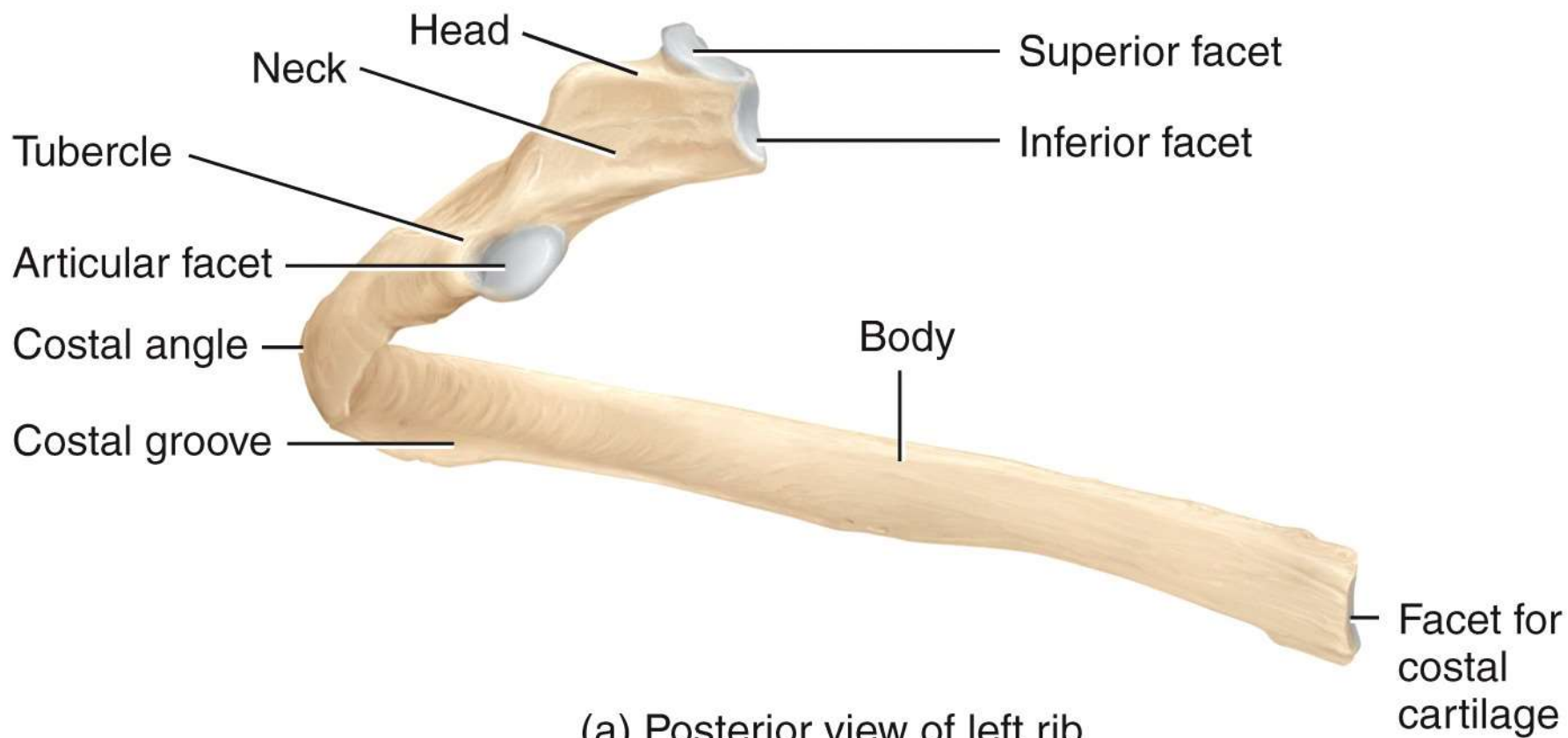
(b) Posterior view

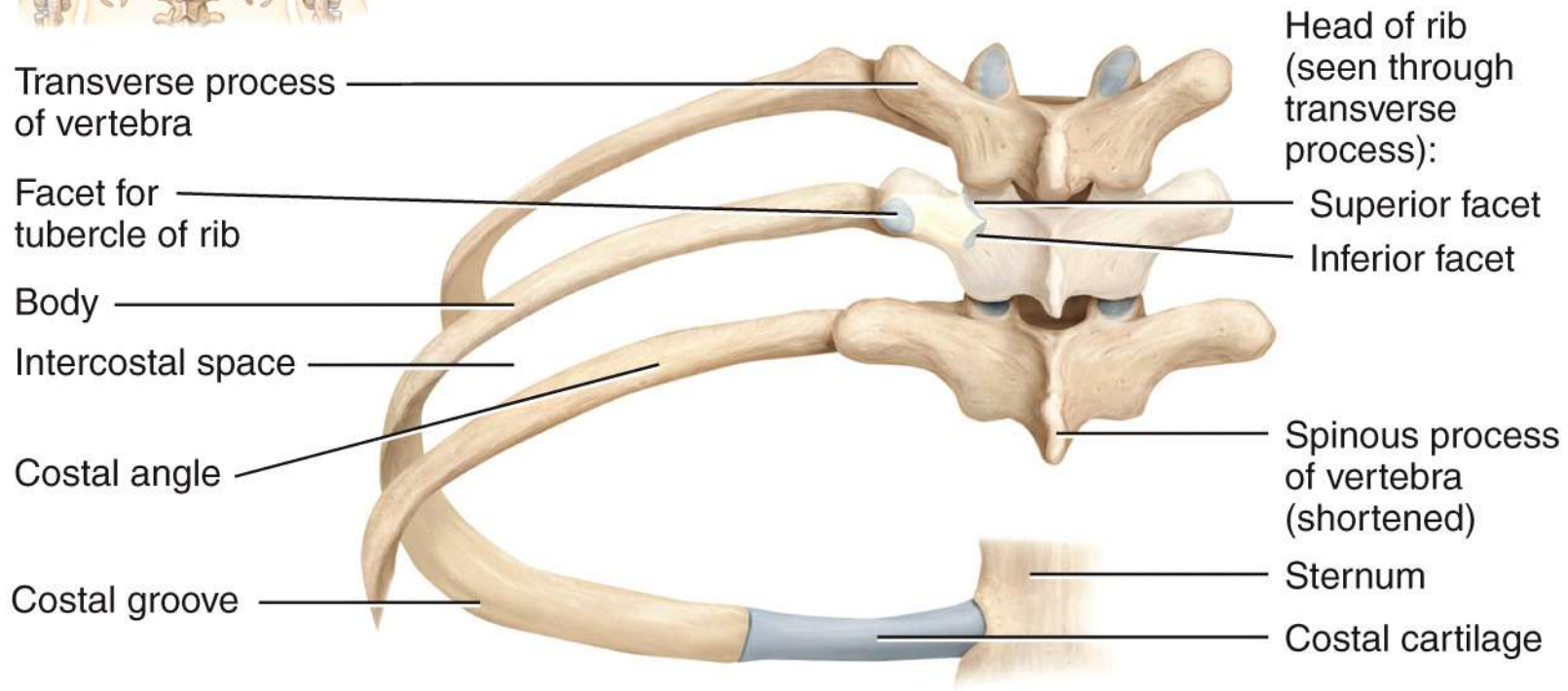
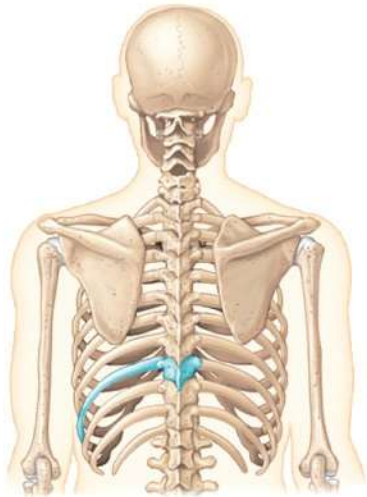


(a) Anterior view of sternum

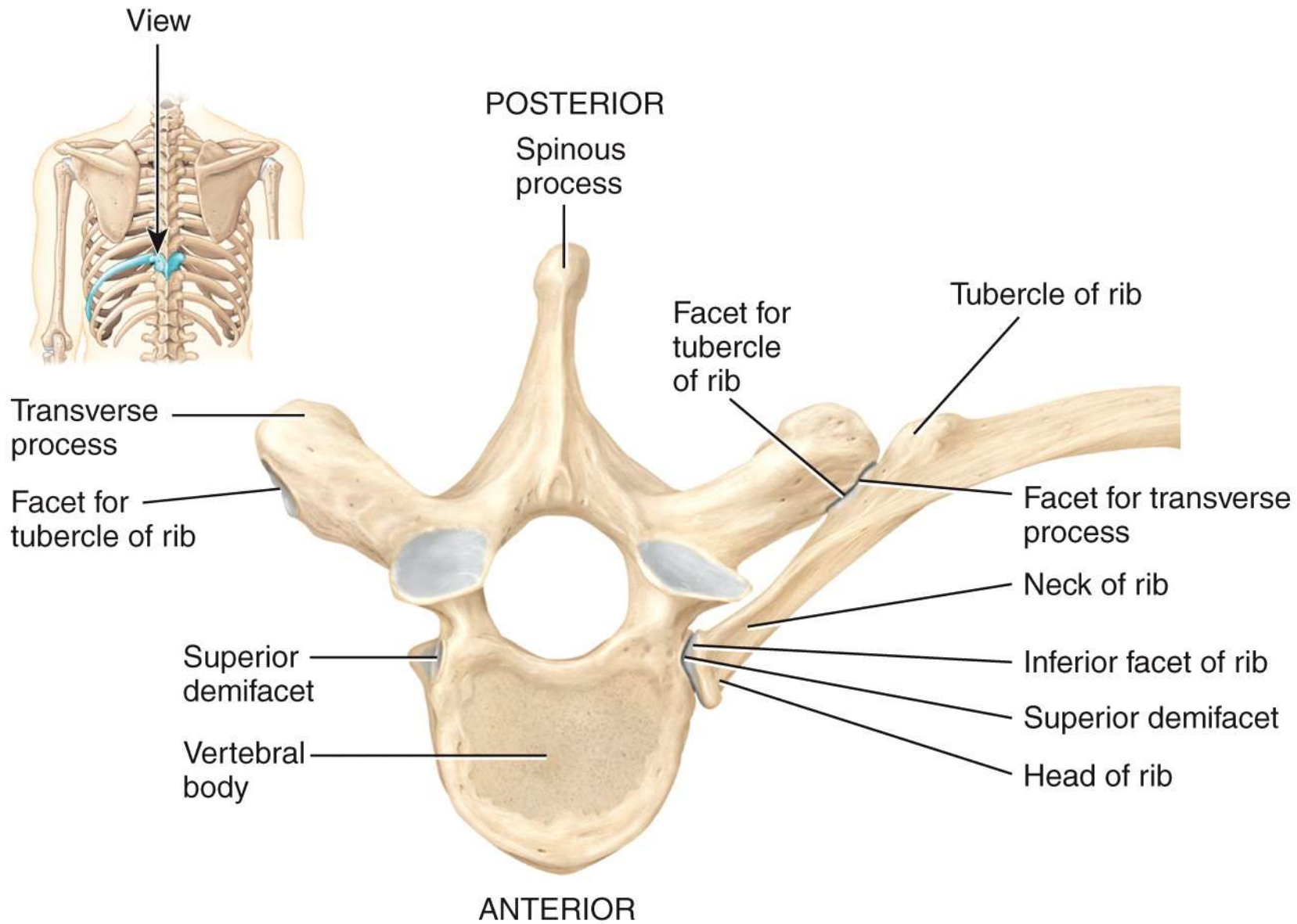


(b) Anterior view of skeleton of thorax



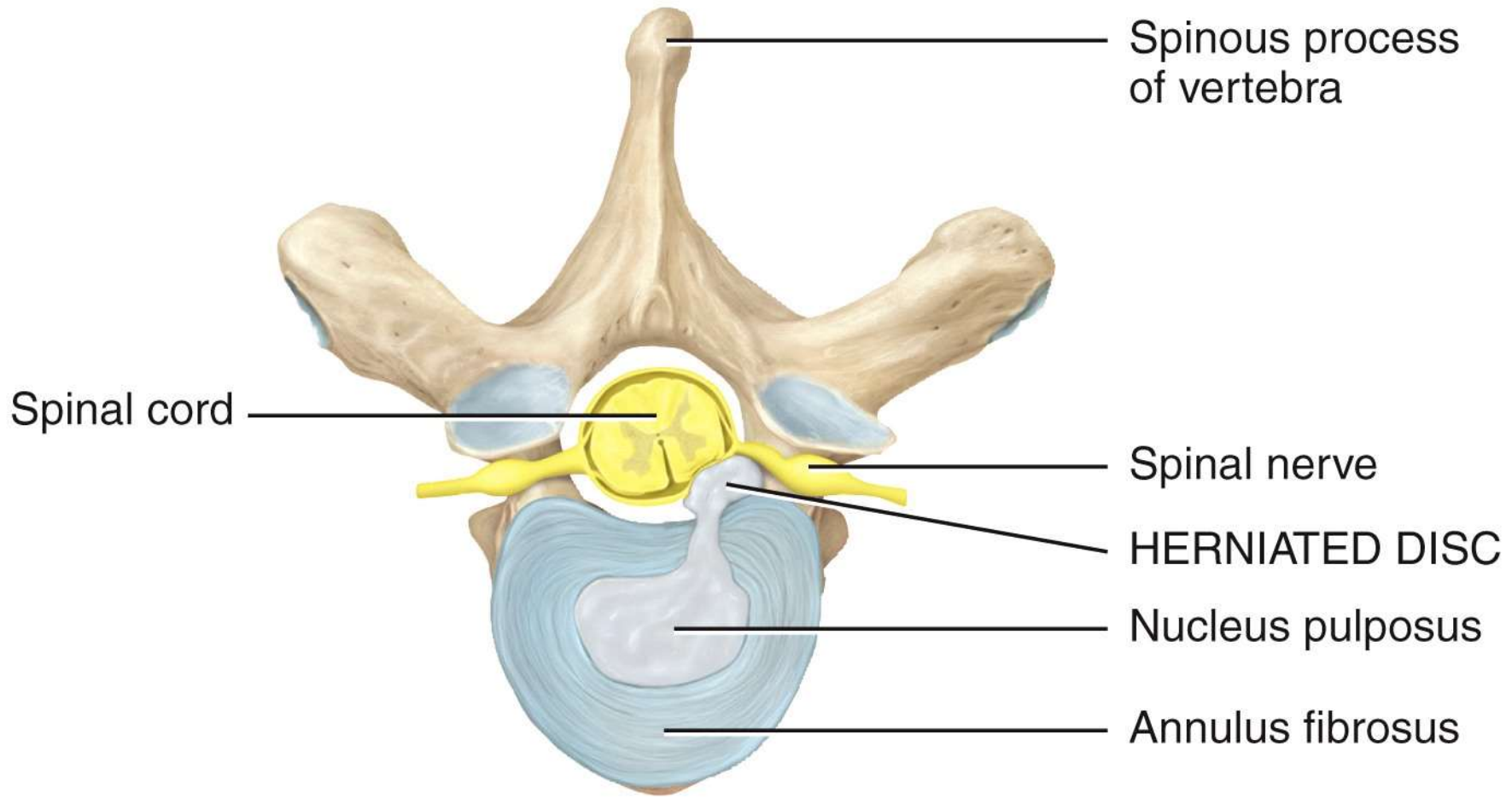


(b) Posterior view of left ribs articulated with thoracic vertebrae and sternum



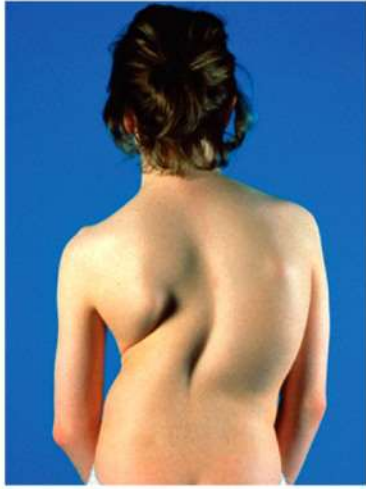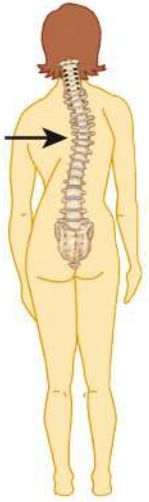(c) Superior view of left rib articulated with thoracic vertebra

POSTERIOR



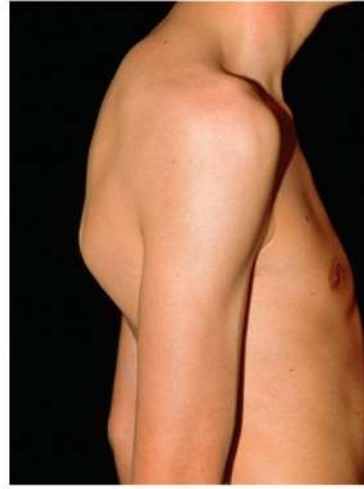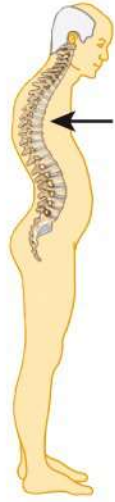ANTERIOR

Superior view



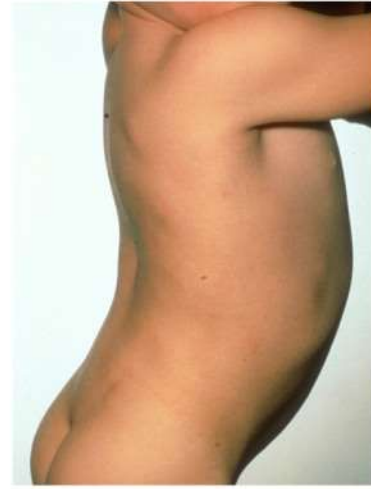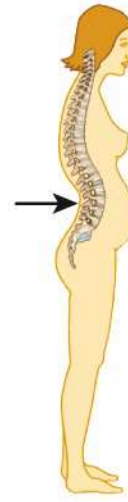Princess Margaret Rose Orthopaedic
Hospital/Photo Researchers, Inc.

(a) Scoliosis



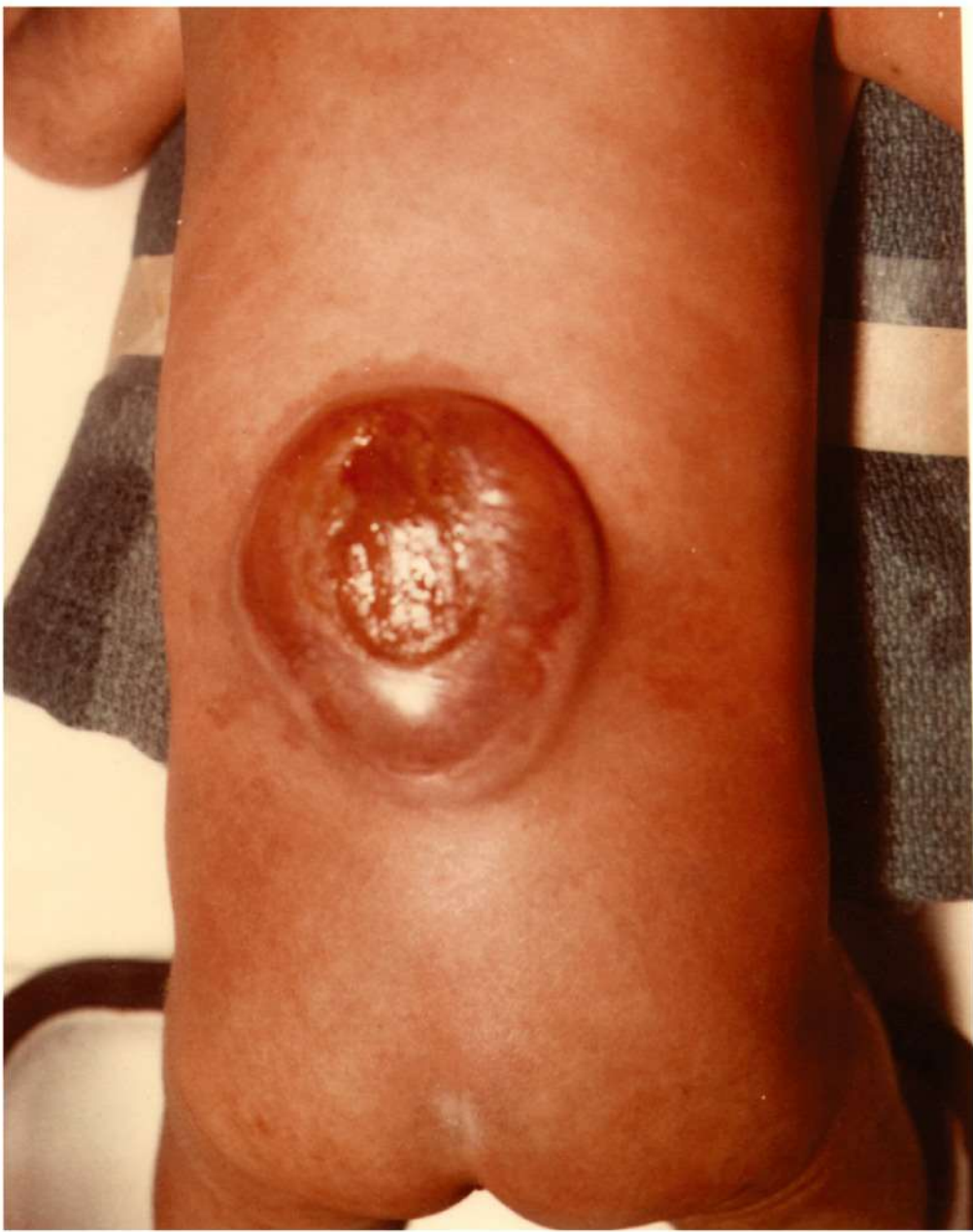Dr. P. Marazzi/Photo Researchers, Inc.

(b) Kyphosis



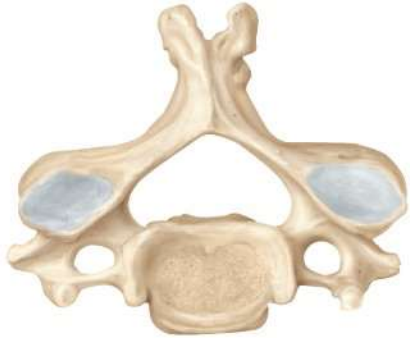Custom Medical Stock Photo, Inc.

(c) Lordosis

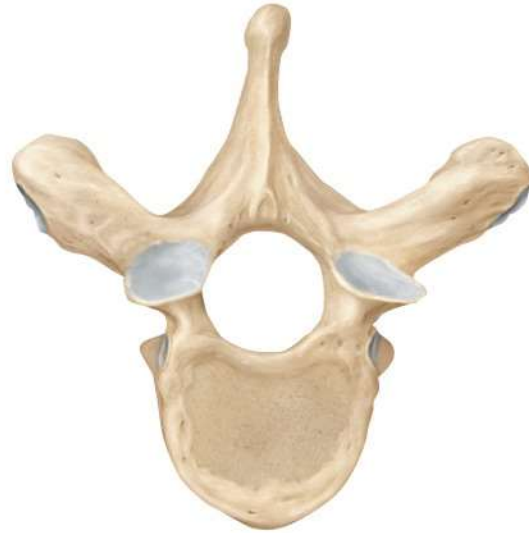

Center for Disease Control/Project Masters, Inc

Cervical



Thoracic



Lumbar

