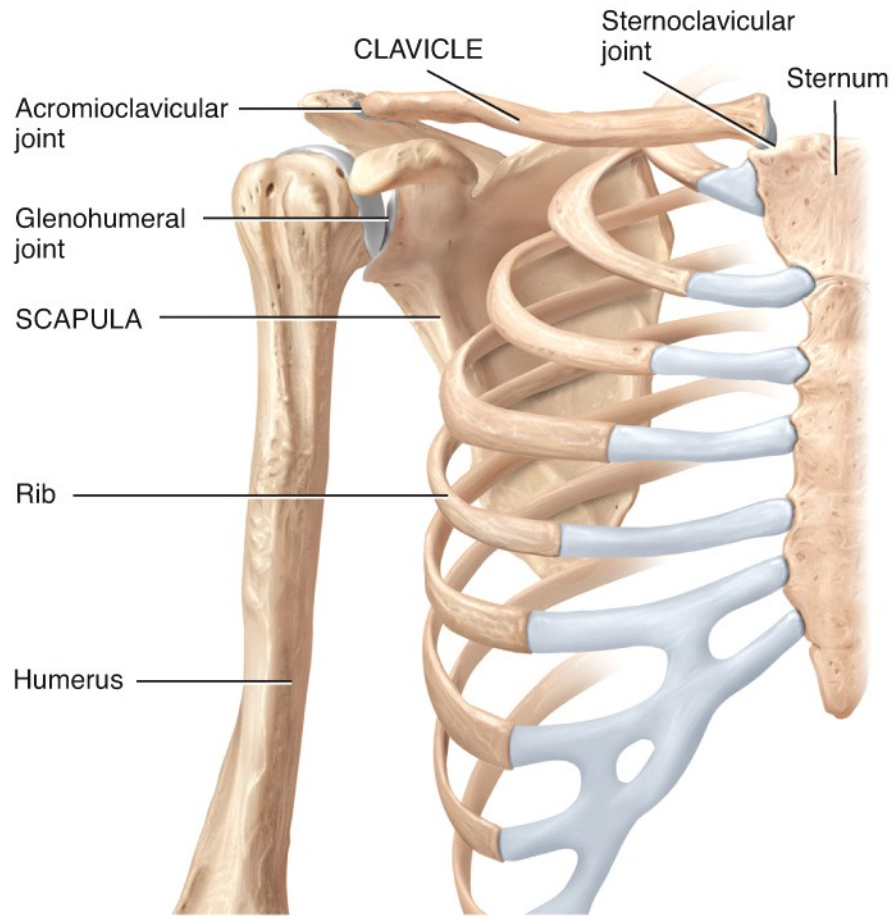
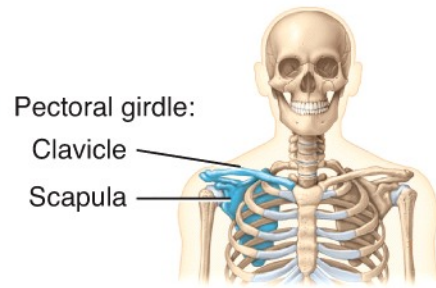
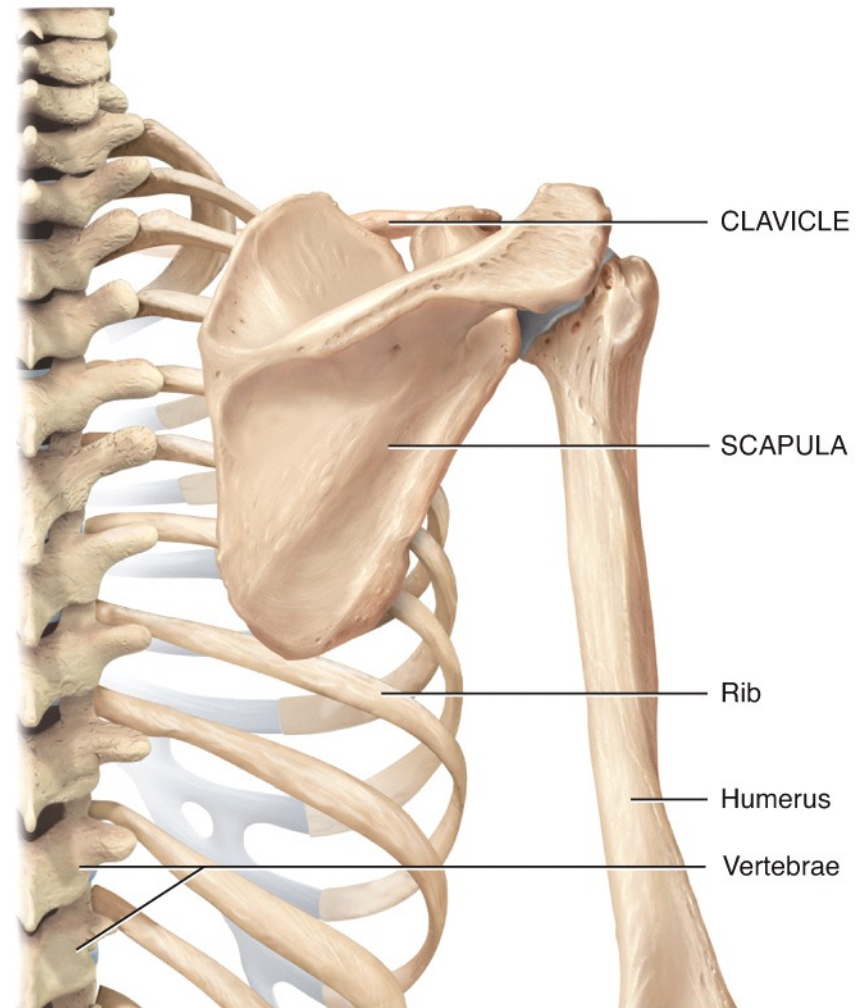


Chapter 8

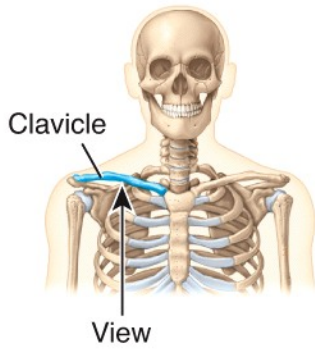
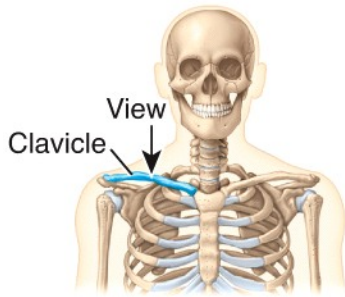
Images of the Appendicular Skeletal System



(a) Anterior view of pectoral girdle

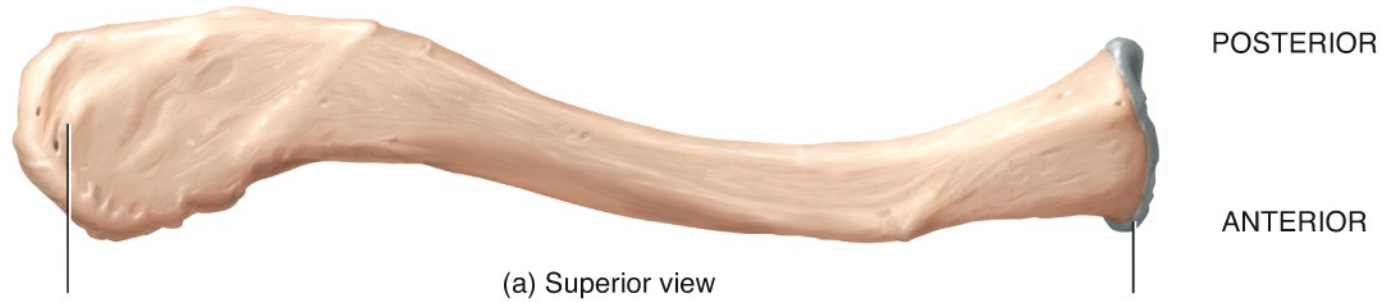

(b) Posterior view of pectoral girdle



LATERAL

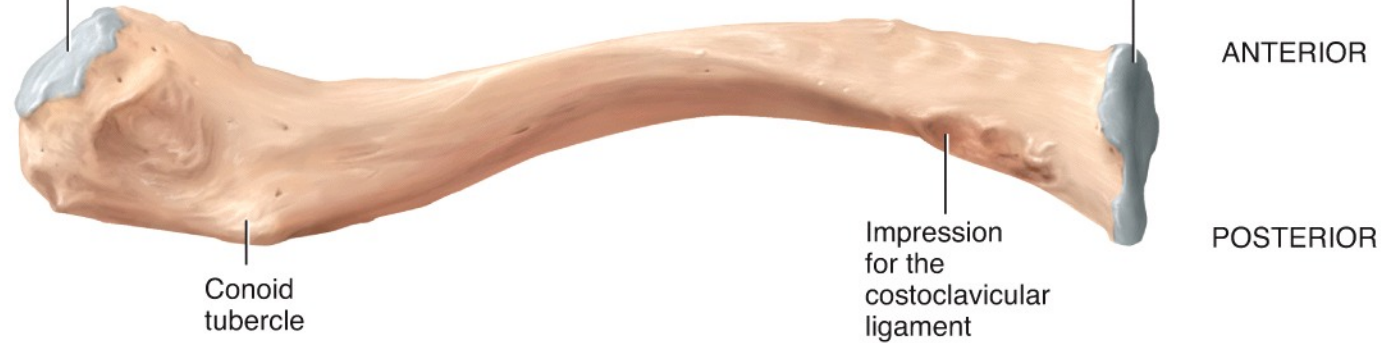MEDIAL



Acromial end

Sternal end

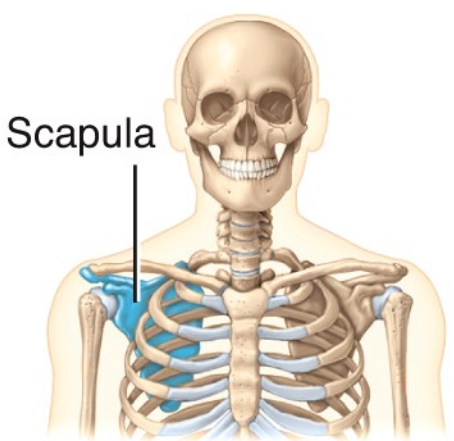
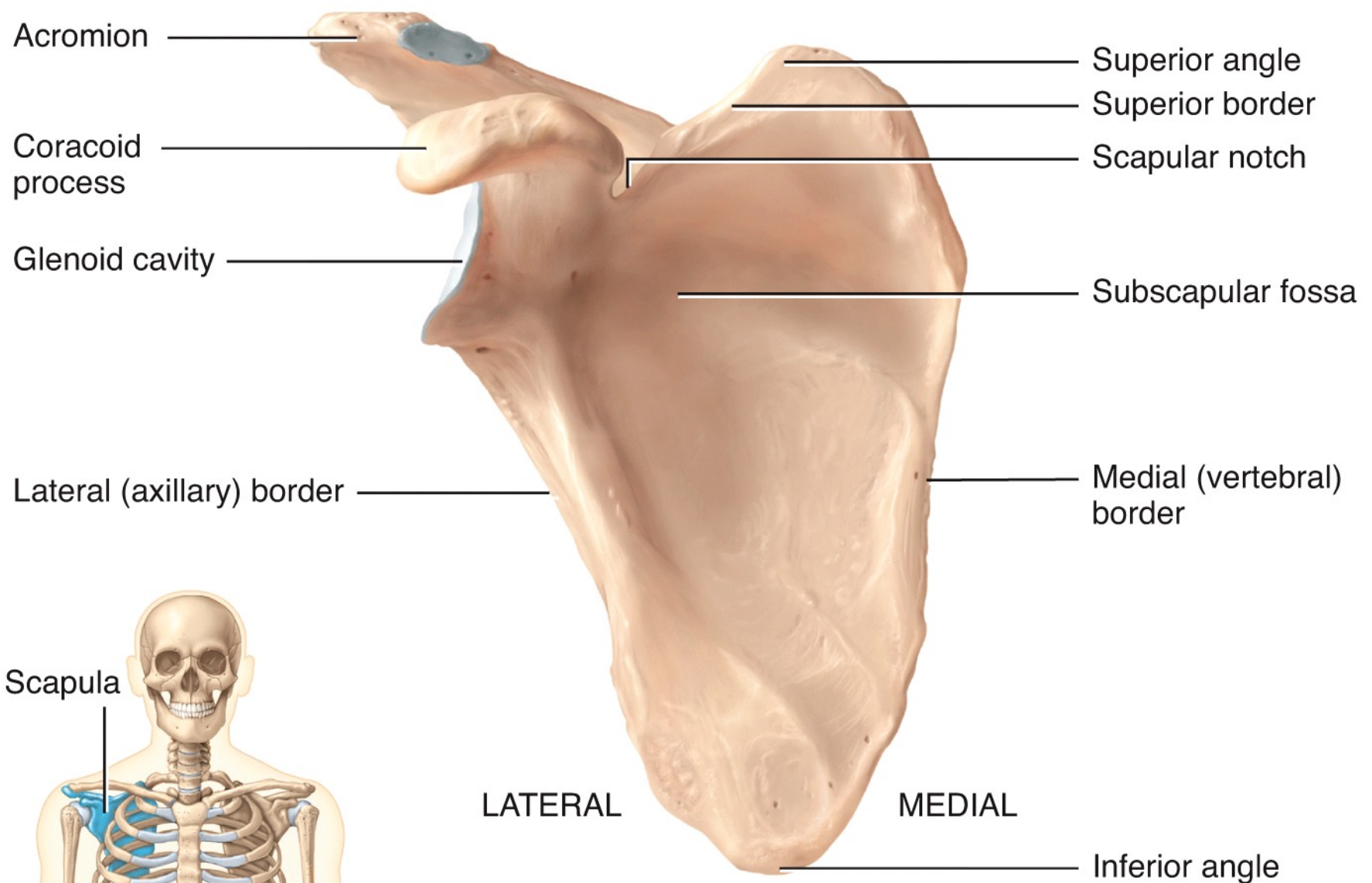
(a) Superior view



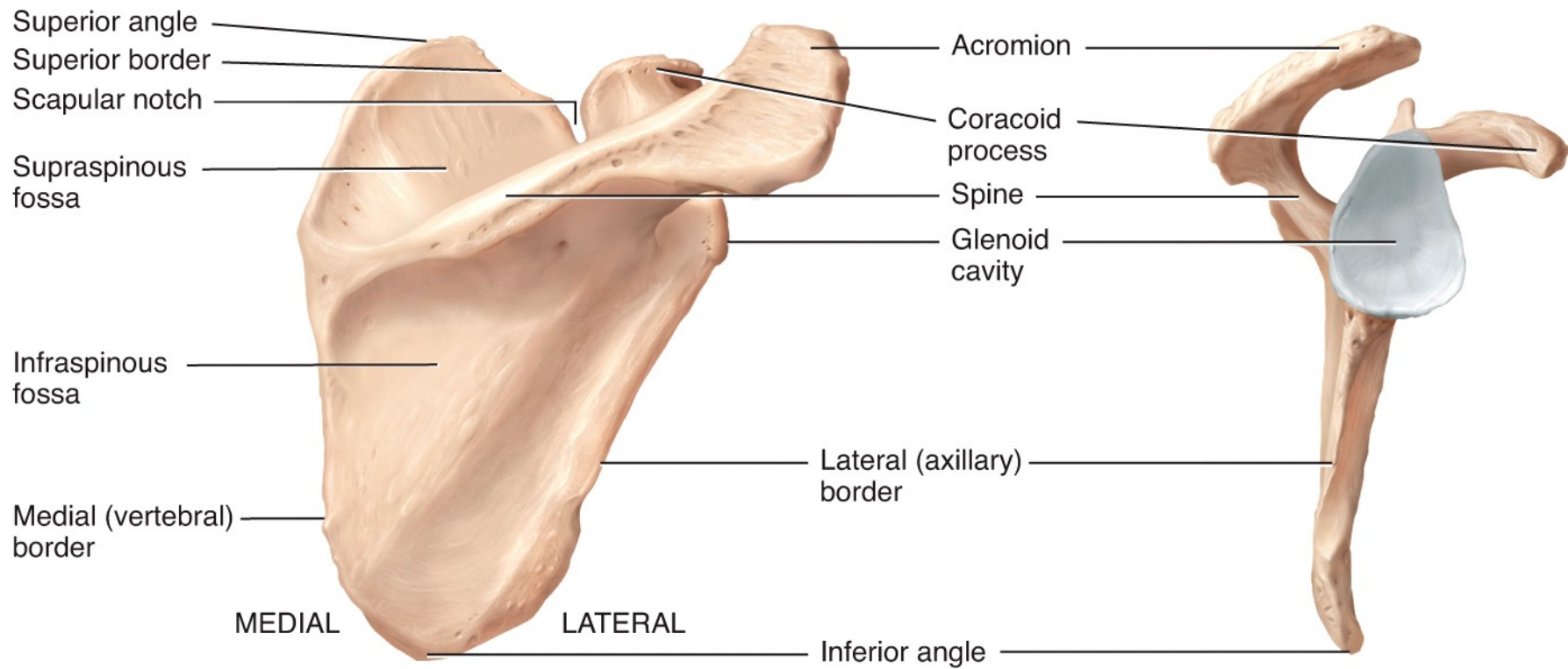
Conoid tubercle

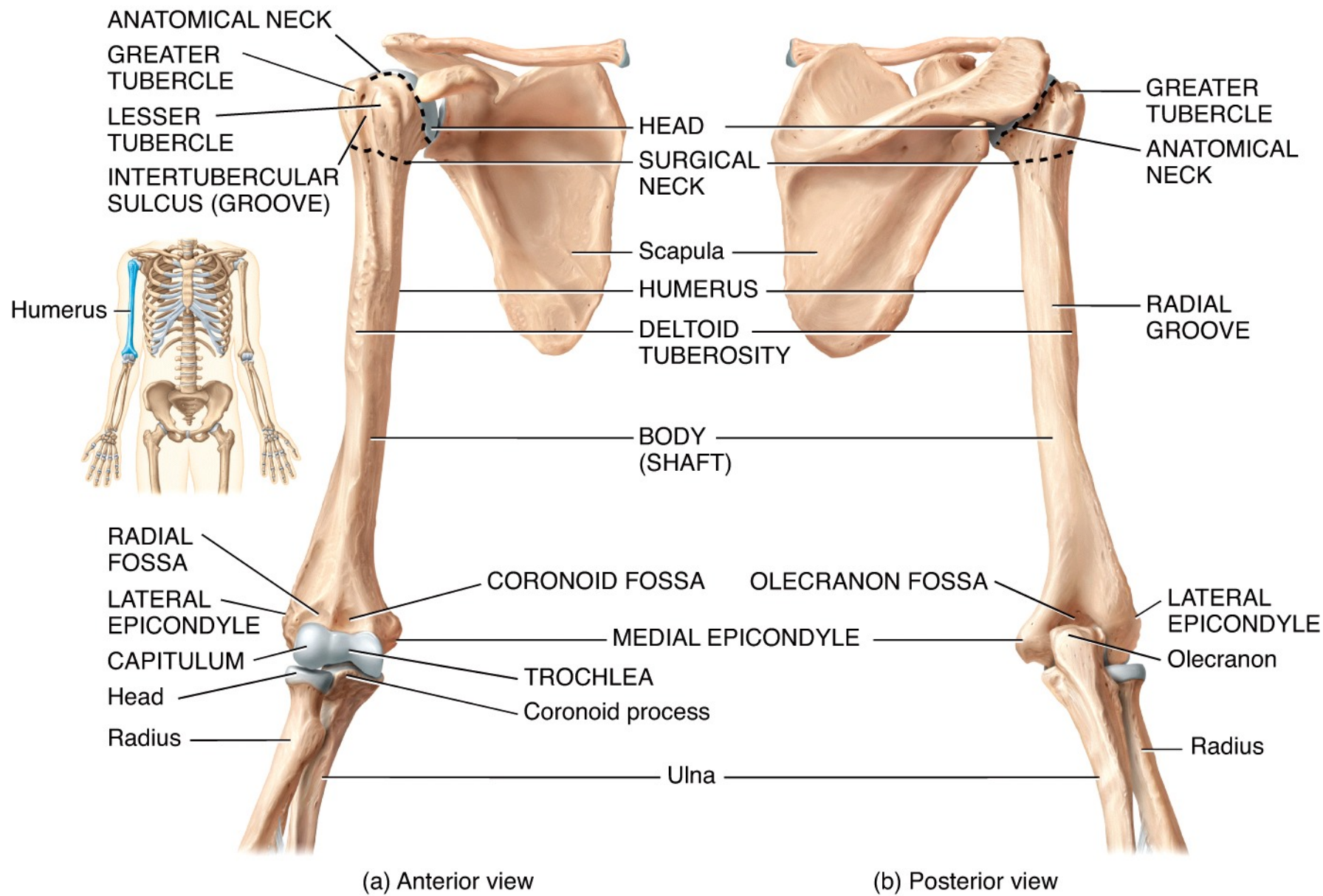
Impression for the costoclavicular ligament

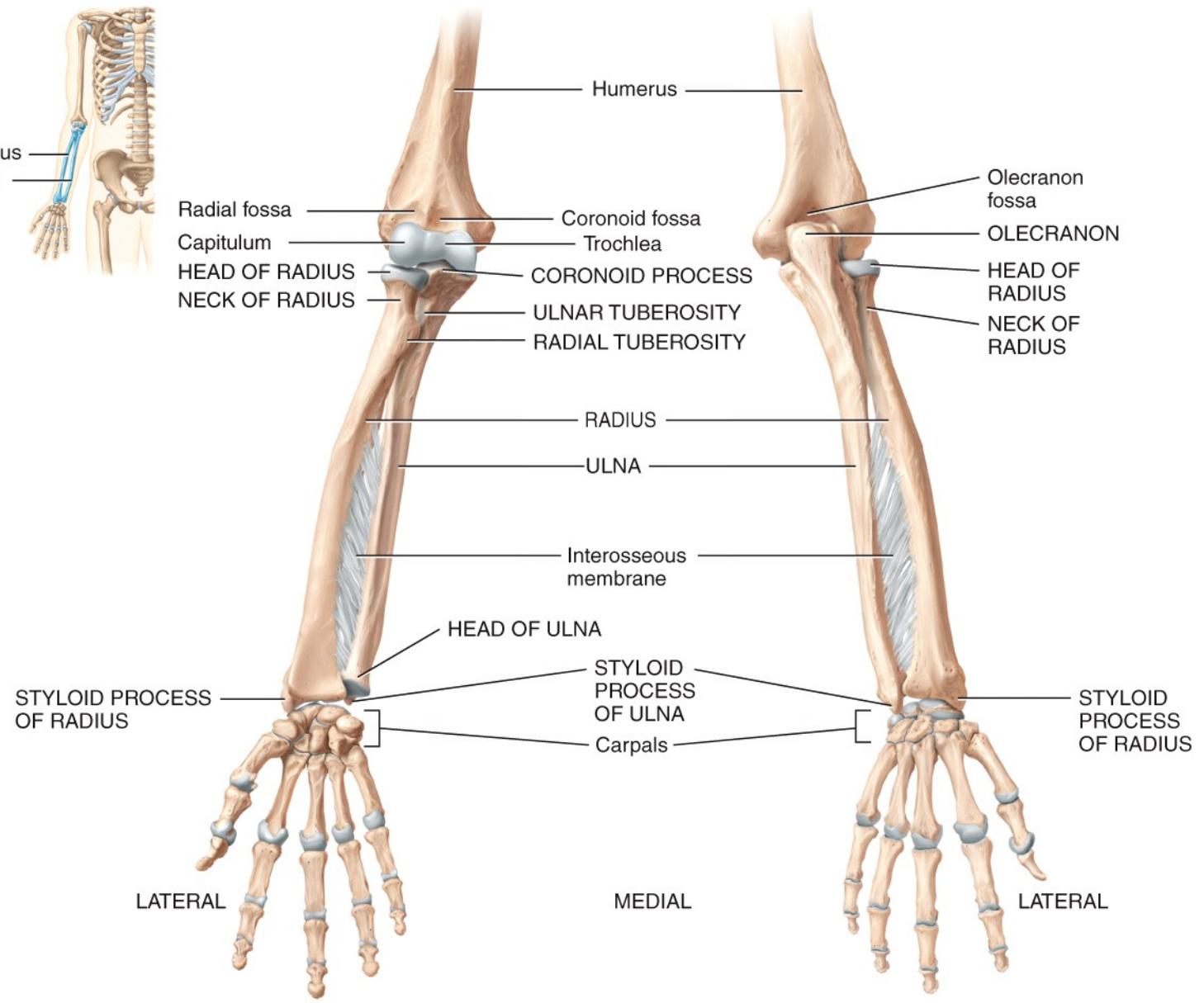
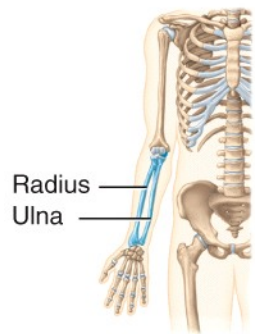
(b) Inferior view



(a) Anterior view

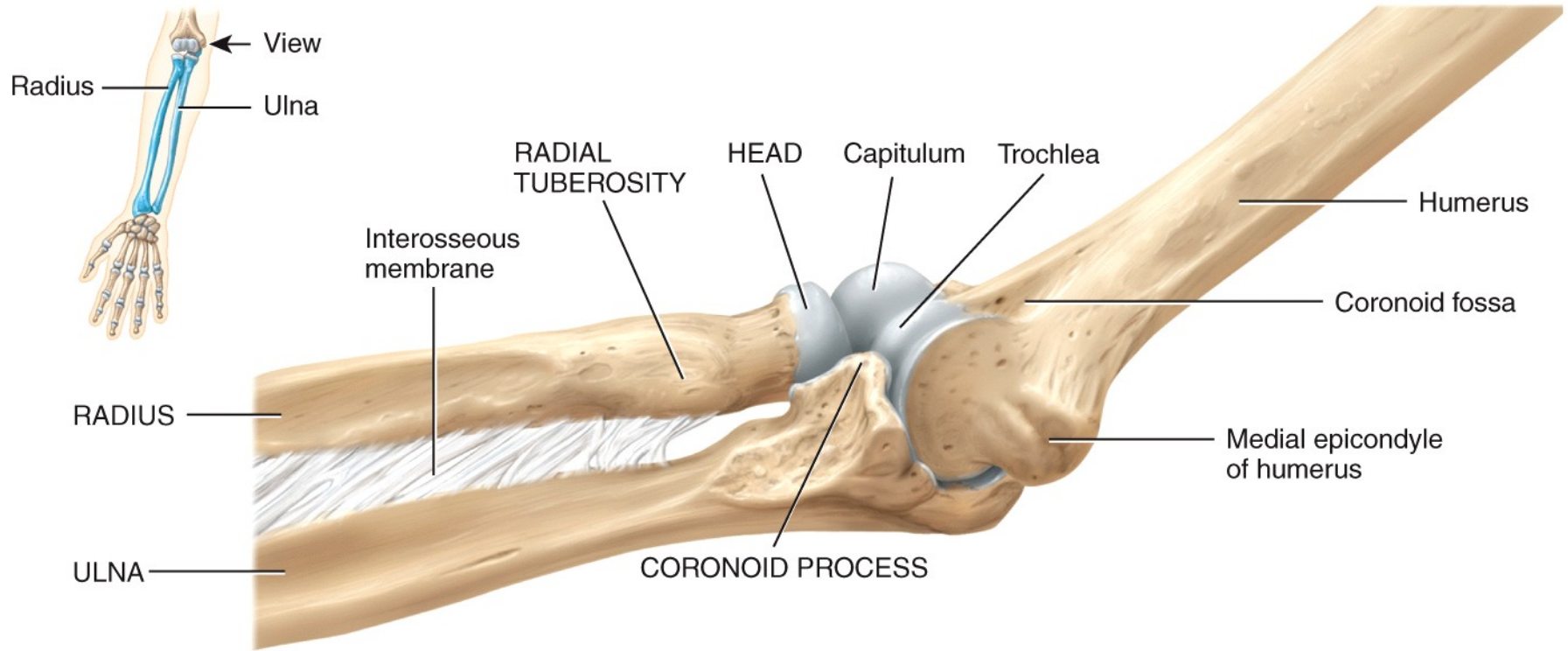




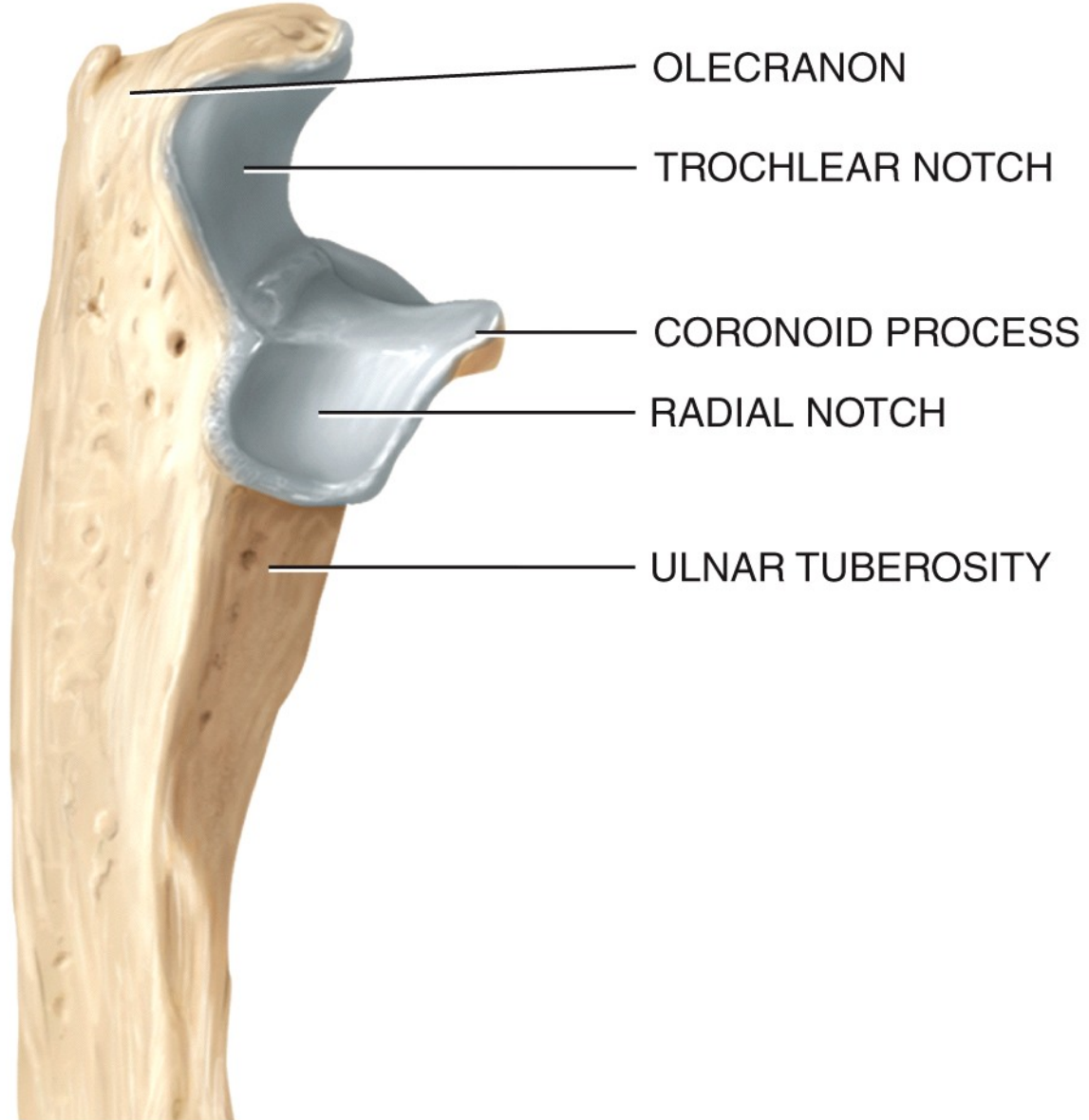


(a) Anterior view

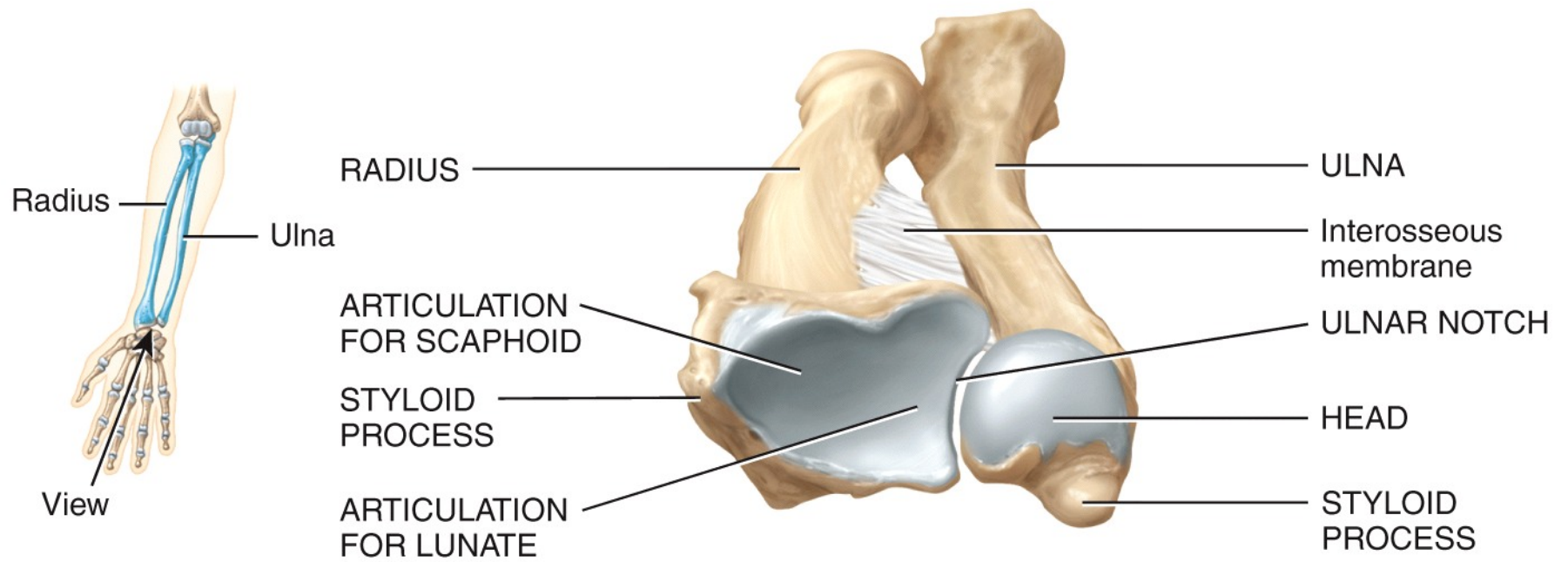
(b) Posterior view



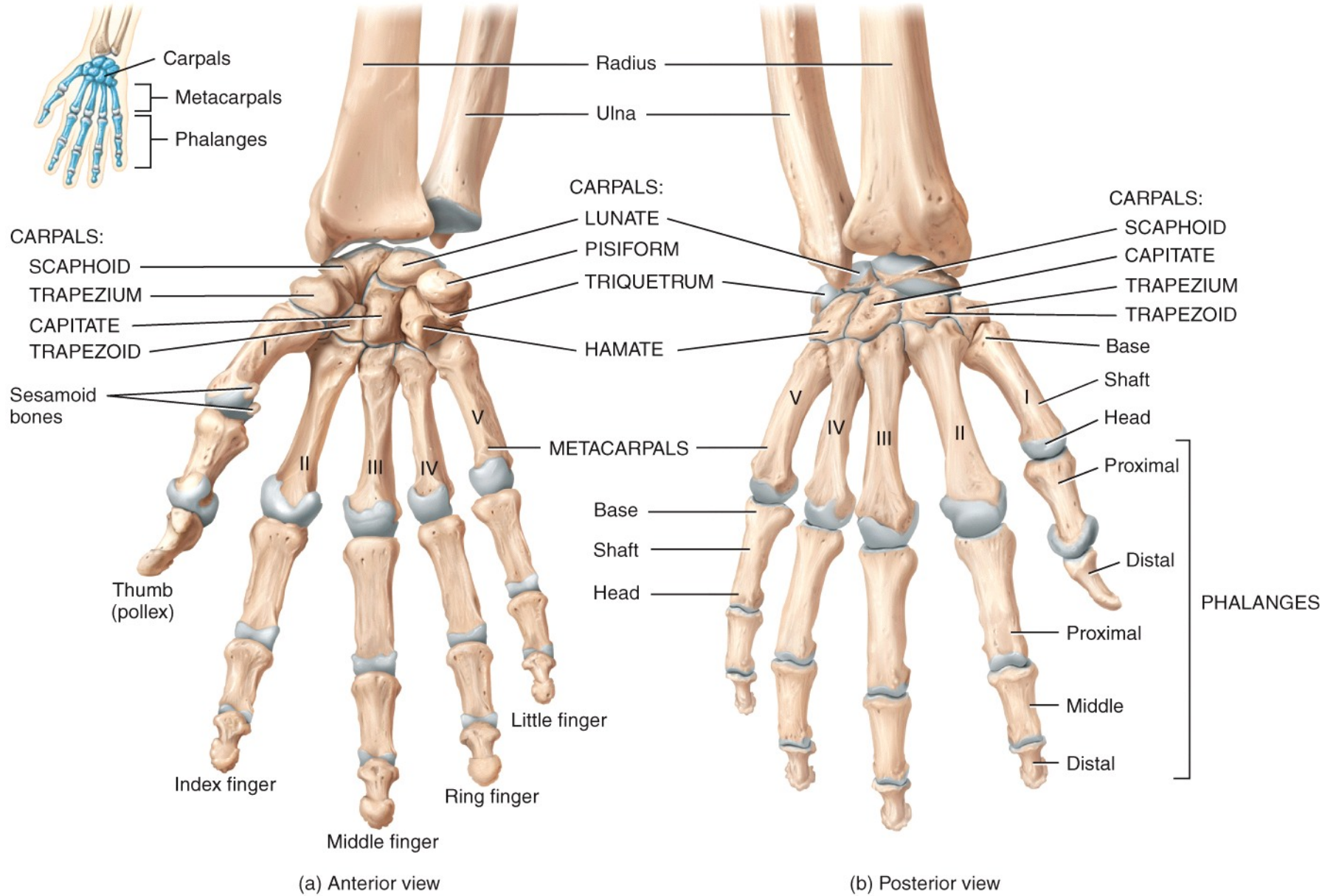
(a) Medial view in relation to humerus



(b) Lateral view of proximal end of ulna



(c) Inferior view of distal ends of radius and ulna



MNEMONIC for carpal bones*:

Stop **L**etting **T**hose **P**eople **T**ouch **T**he **C**adaver's **H**and.

Scaphoid **L**unate **T**riquetrum **P**isiform **T**rapezium **T**rapezoid **C**apitate **H**amate



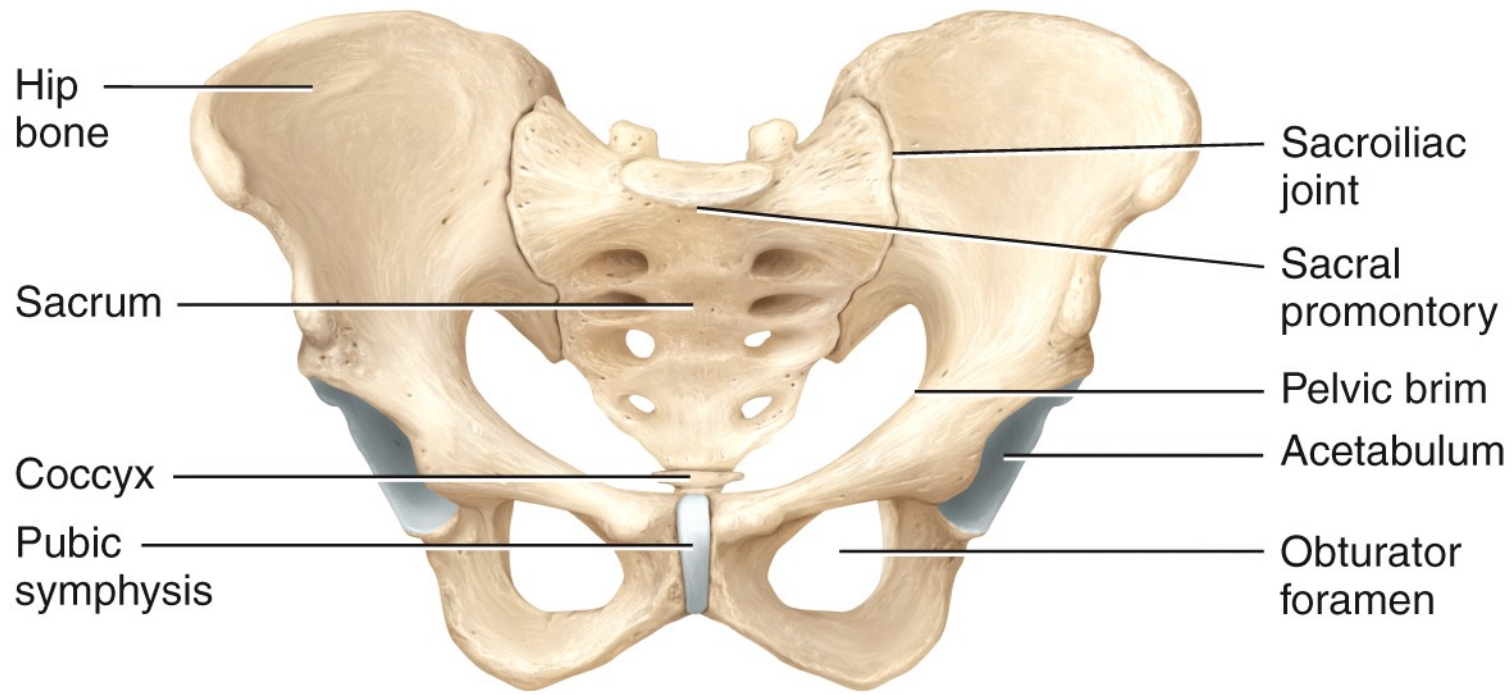
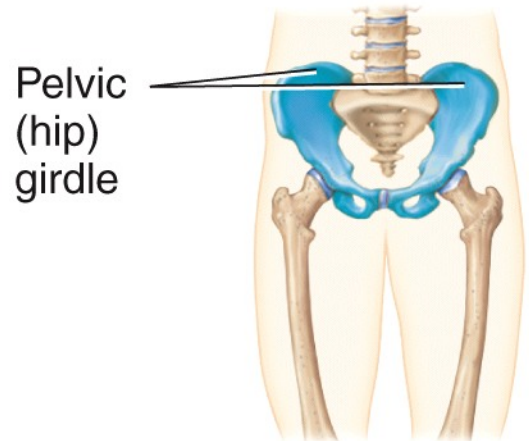
Proximal row

Distal row

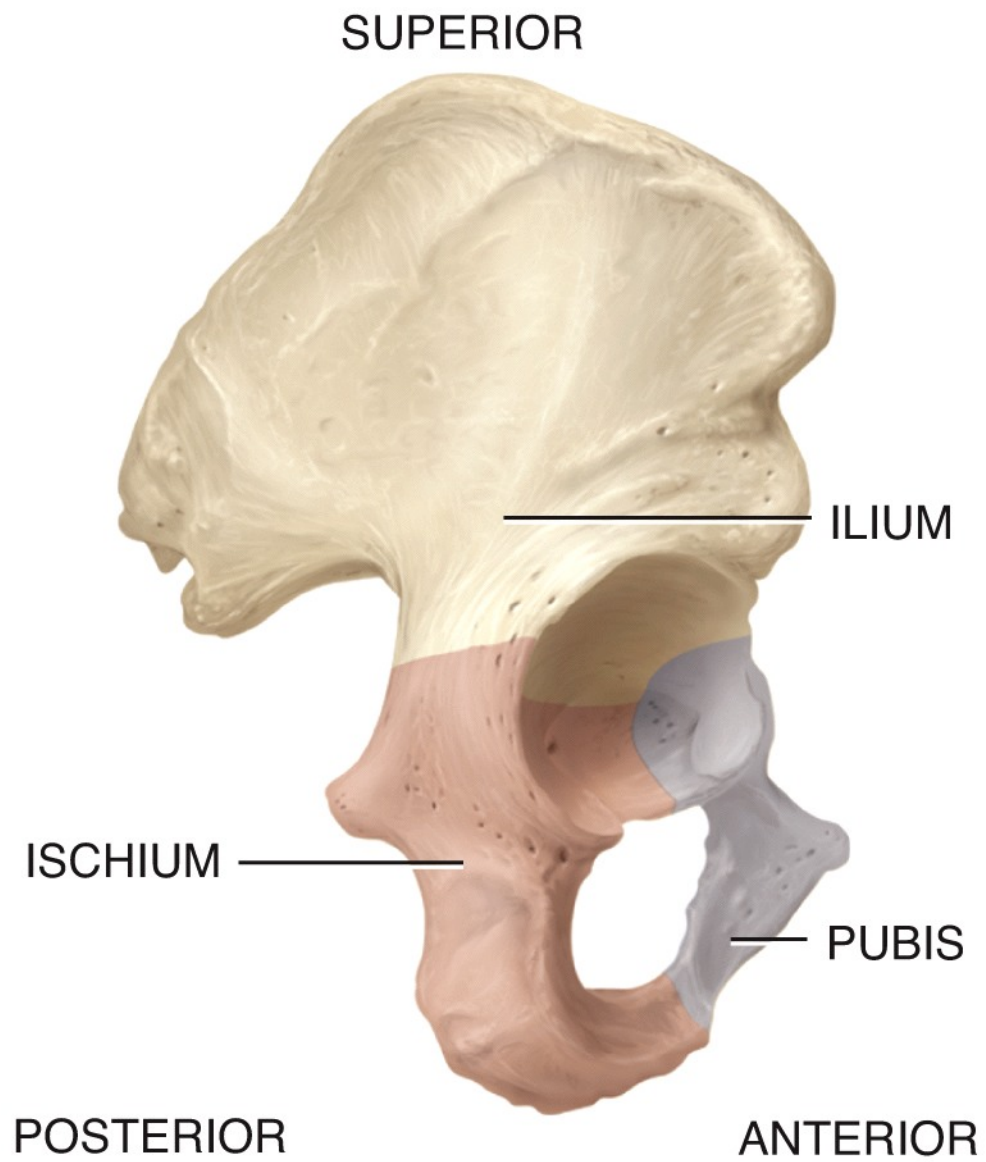
Lateral → Medial

Lateral → Medial

* *Edward Tanner, University of Alabama, SOM*



Anterosuperior view of pelvic girdle



(a) Lateral view showing parts of hip bone

POSTERIOR

ANTERIOR

Gluteal lines

Anterior

Inferior

Posterior

Iliac crest

Ala

ILIUM

Anterior superior
iliac spine

Posterior

superior

iliac spine

Anterior inferior
iliac spine

Posterior

inferior

iliac spine

Body of ilium

Acetabulum

Greater sciatic notch

Acetabular notch

Body of ischium

Superior ramus
of pubis

Ischial spine

Pubic tubercle

Lesser sciatic notch

PUBIS

Obturator
foramen

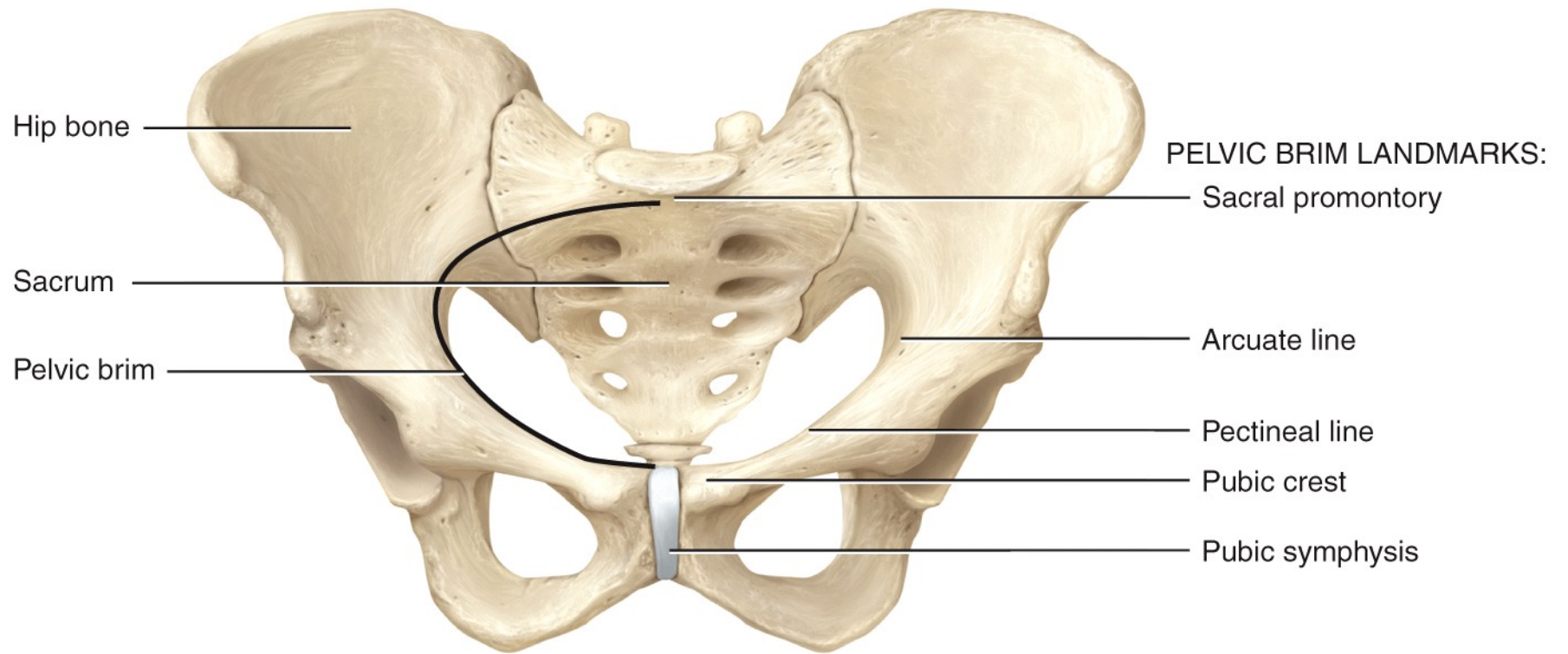
Ischial tuberosity

Ramus of ischium

Inferior ramus
of pubis

ISCHIUM

(b) Detailed lateral view



(a) Anterosuperior view of pelvic girdle

ANTERIOR

POSTERIOR

Iliac crest

Anterior superior
iliac spine

Iliac fossa

Anterior inferior
iliac spine

Arcuate line

Pectineal line

Superior ramus of pubis

Body of pubis

Pubic tubercle

Pubic crest

Pubic symphysis

Inferior ramus
of pubis

ILIUM

PUBIS

ISCHIUM

Iliac tuberosity

Auricular surface

Posterior superior
iliac spine

Posterior inferior
iliac spine

Greater sciatic notch

Body of ilium

Body of ischium

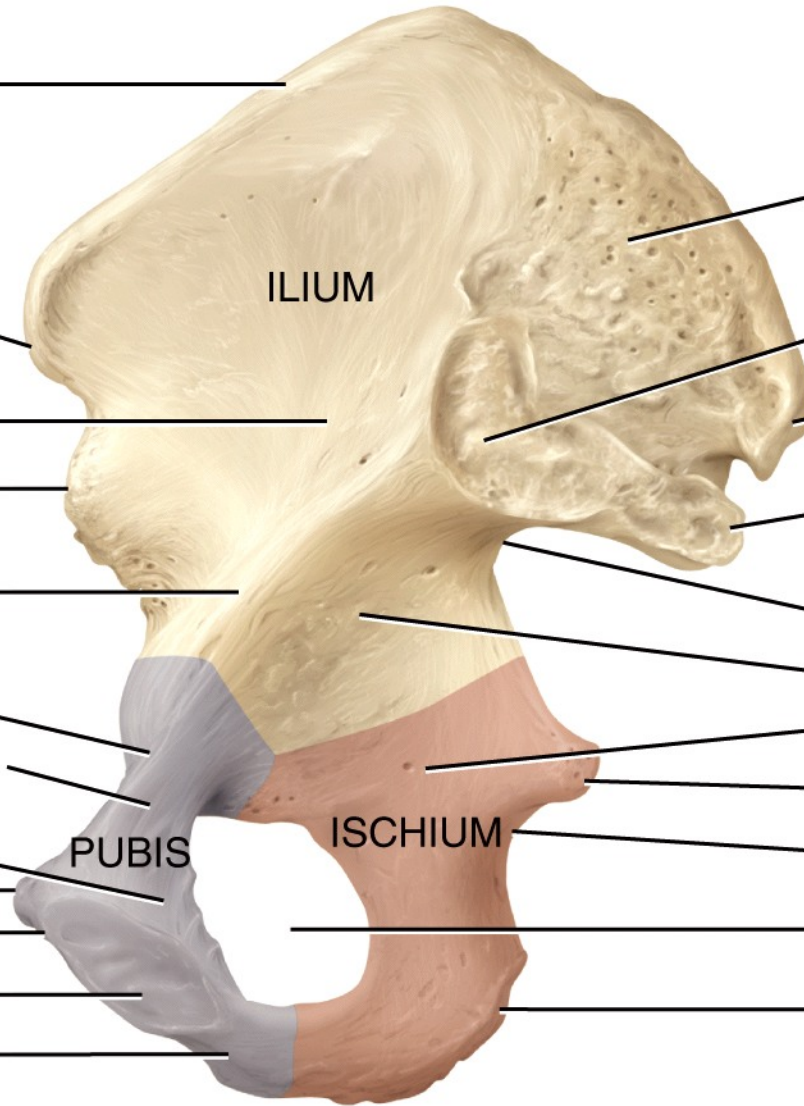
Ischial spine

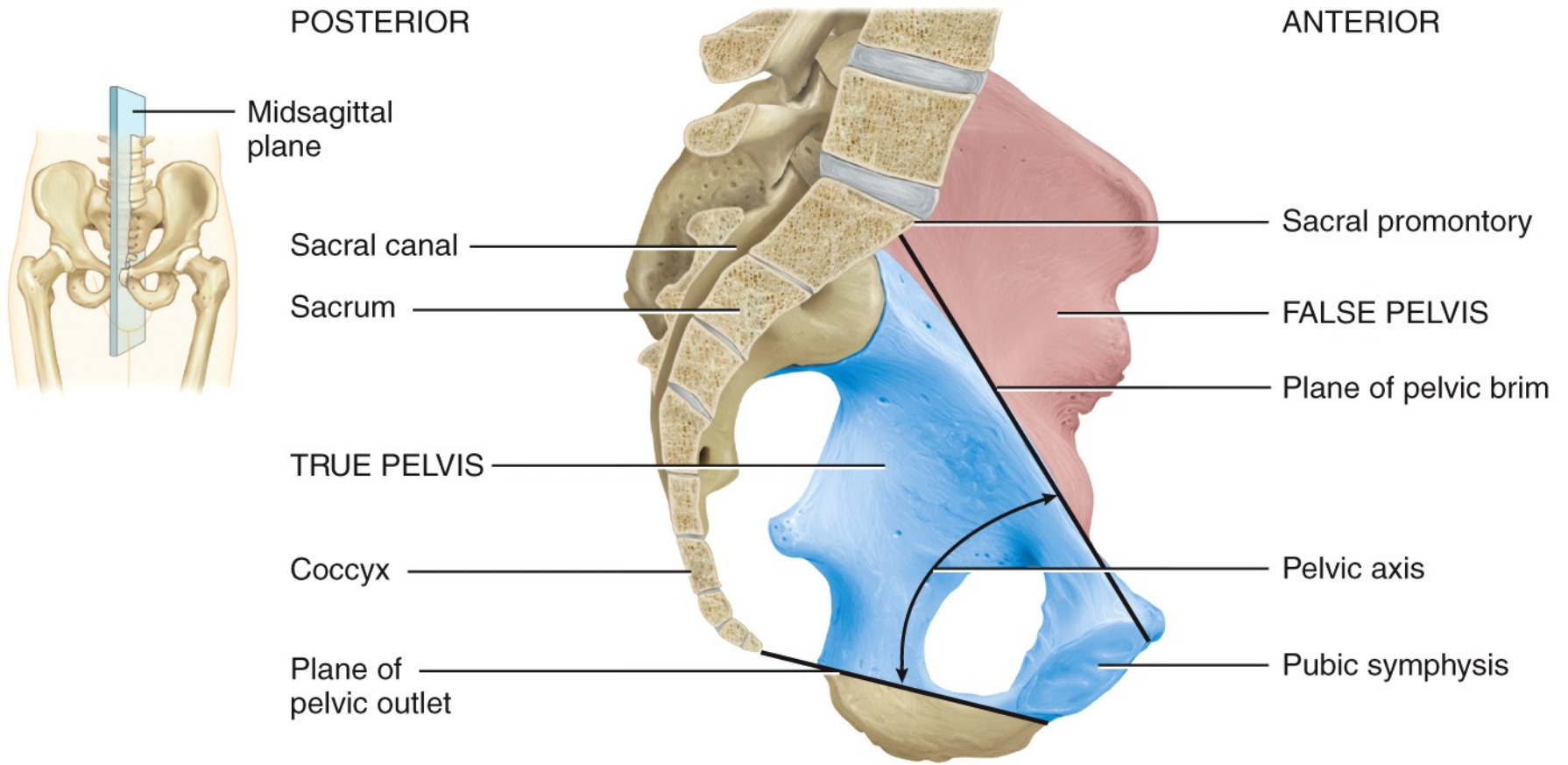
Lesser sciatic notch

Obturator foramen

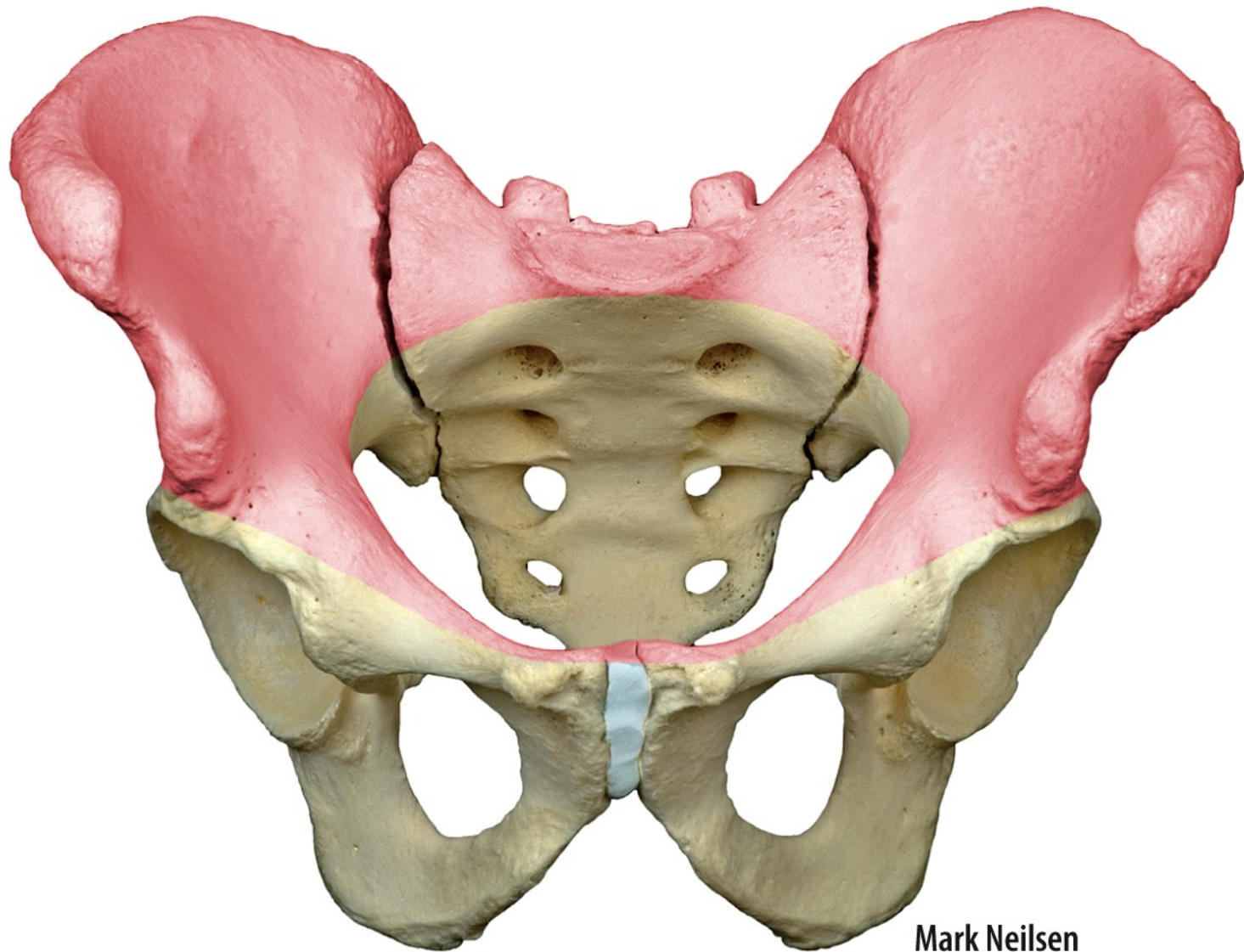
Ischial tuberosity

(c) Detailed medial view

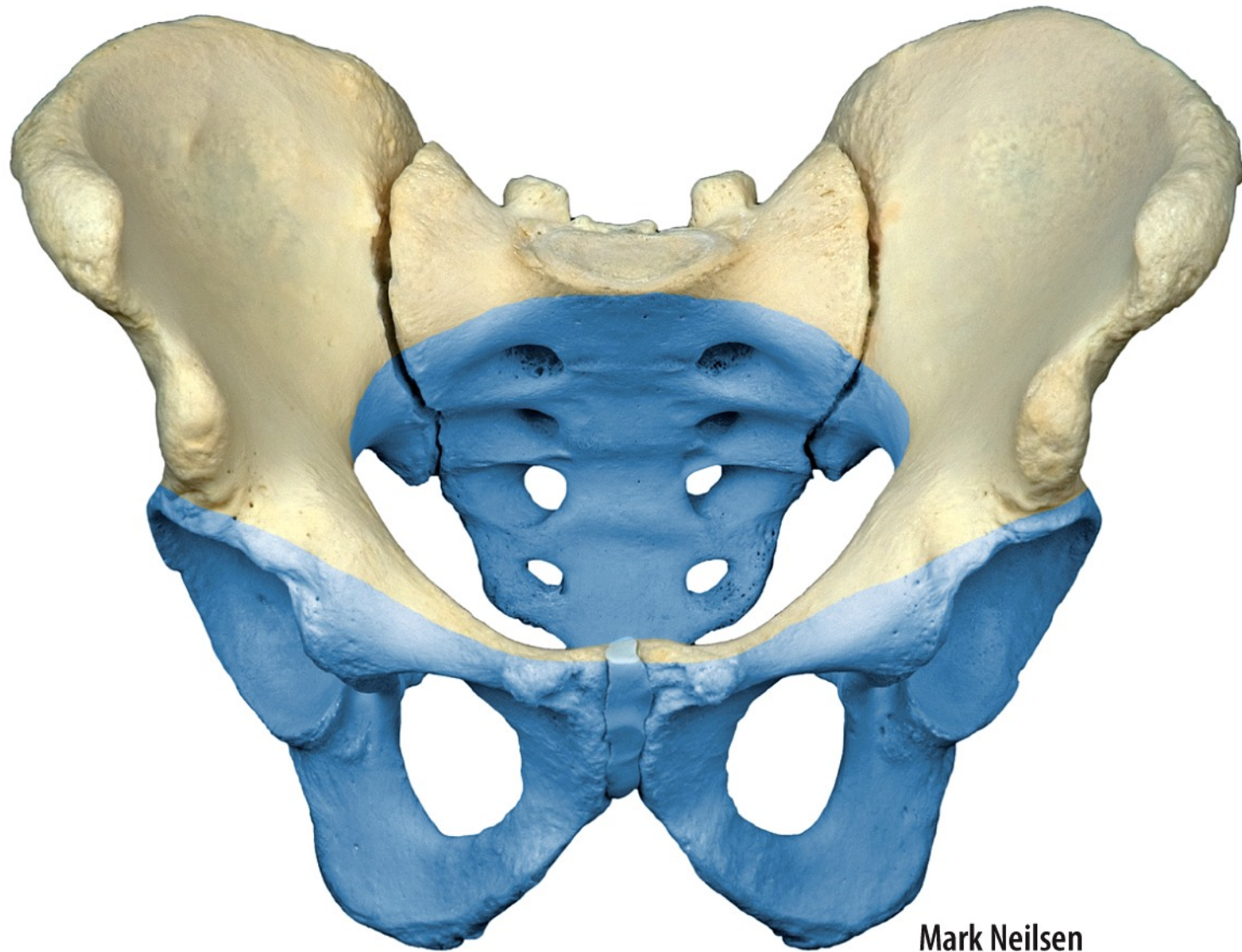




(b) Midsagittal section indicating locations of true and false pelvis

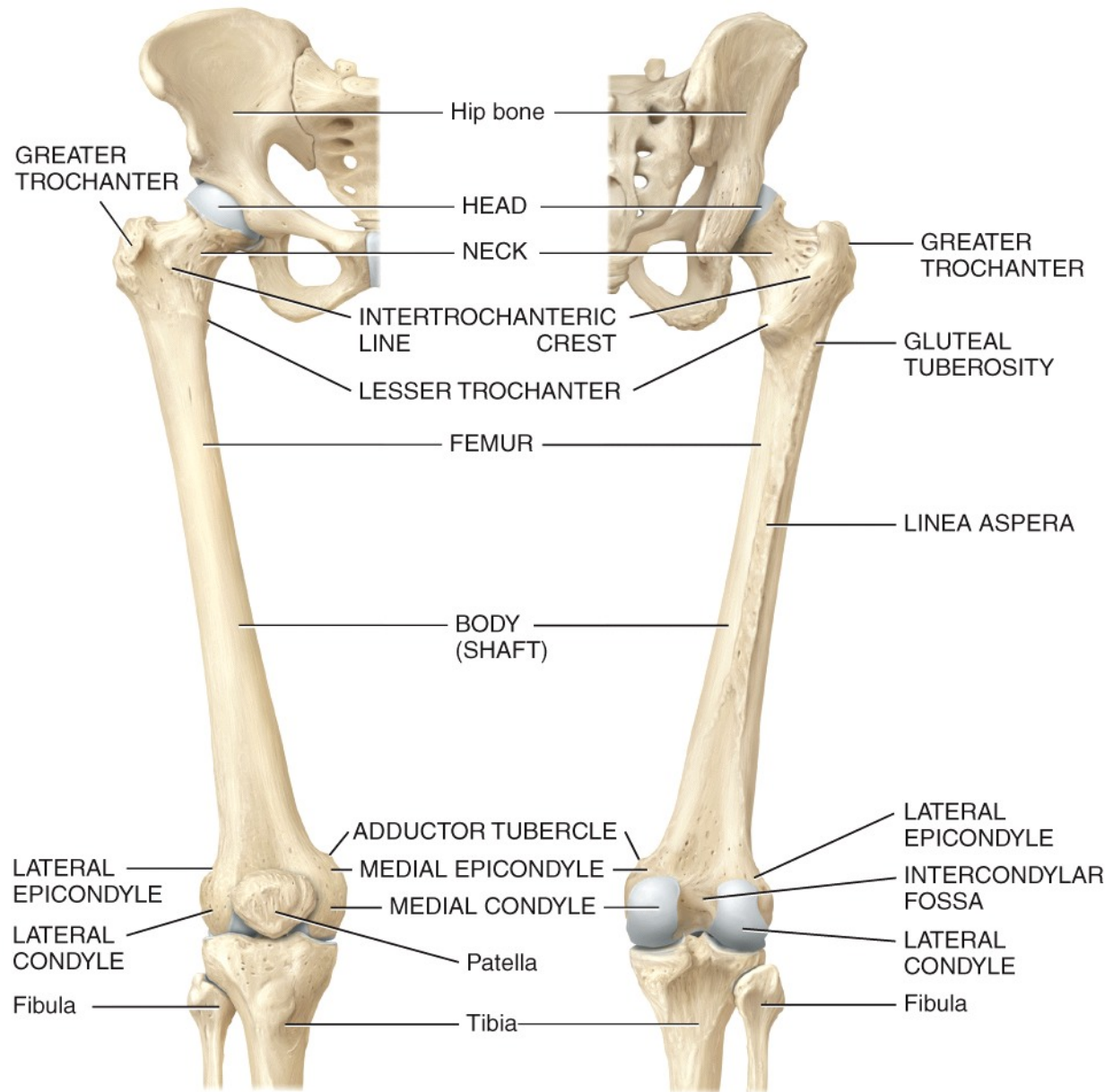
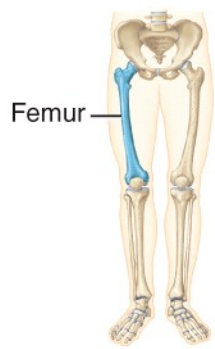


(c) Anterosuperior view of false pelvis (pink)



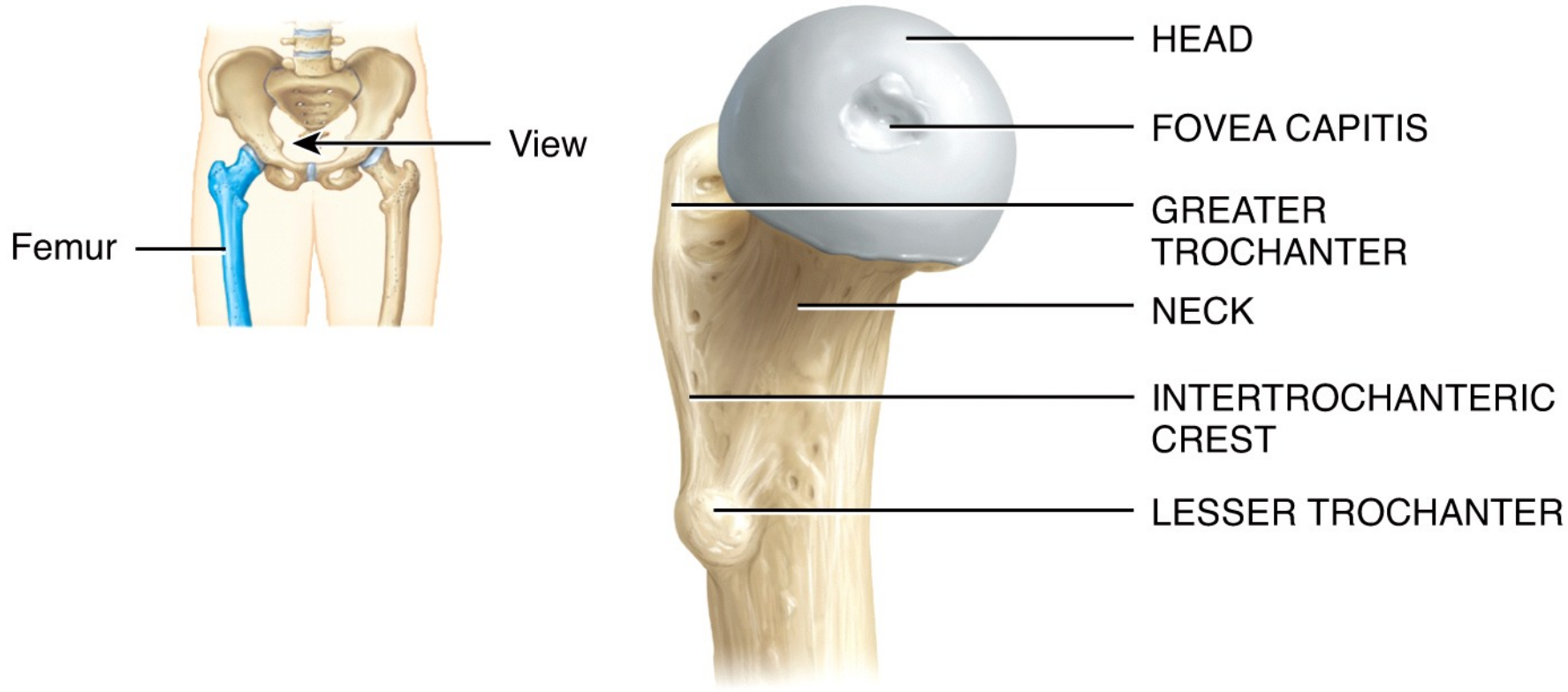
Mark Neilsen

(d) Anterosuperior view of true pelvis (blue)

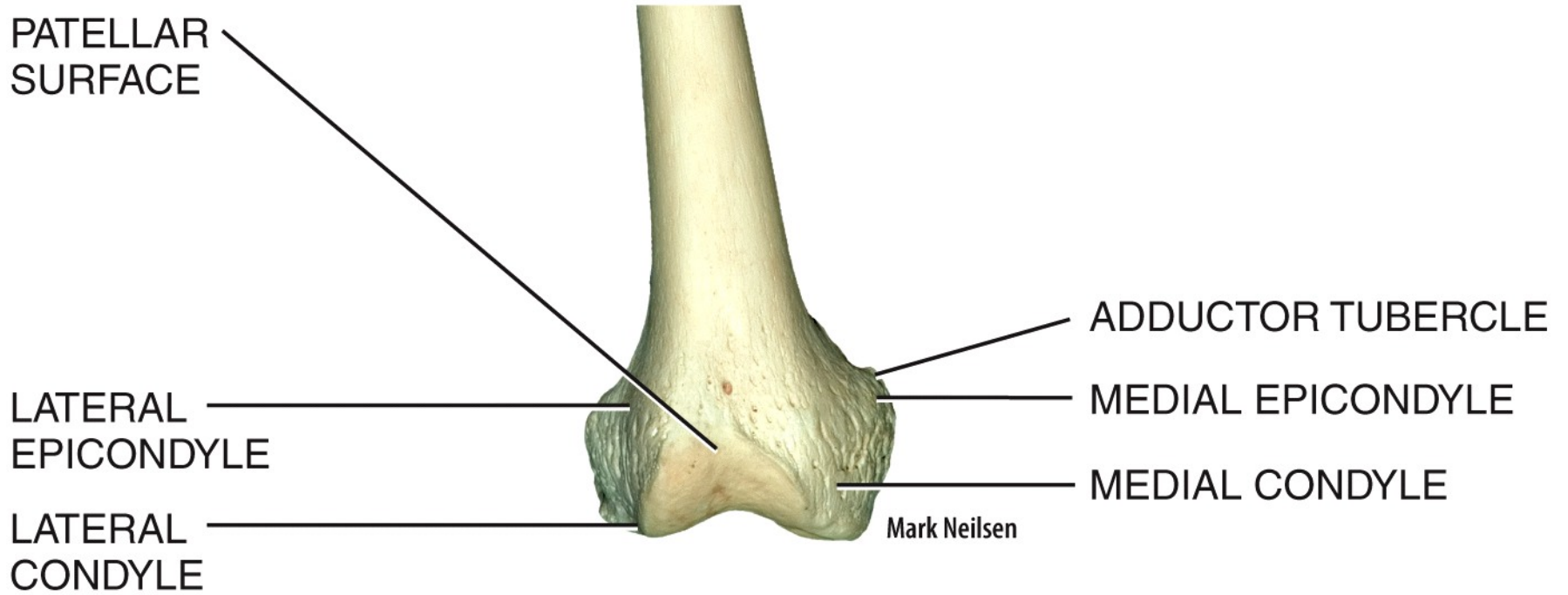


(a) Anterior view

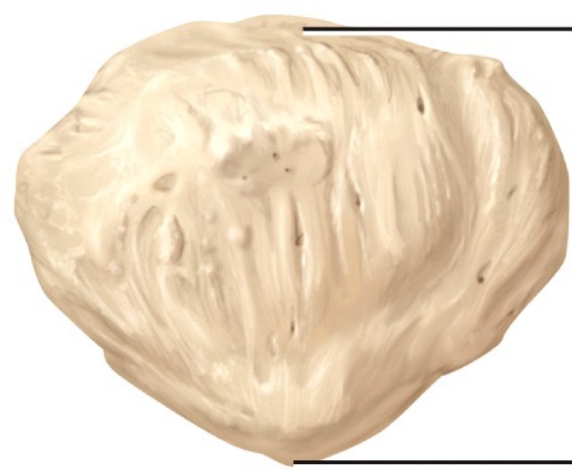
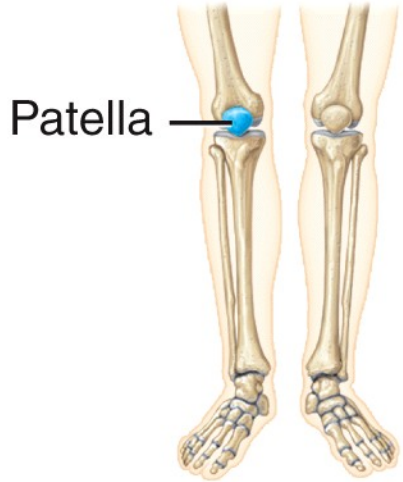
(b) Posterior view



(c) Medial view of proximal end of femur



(d) Anterior view of distal end of femur

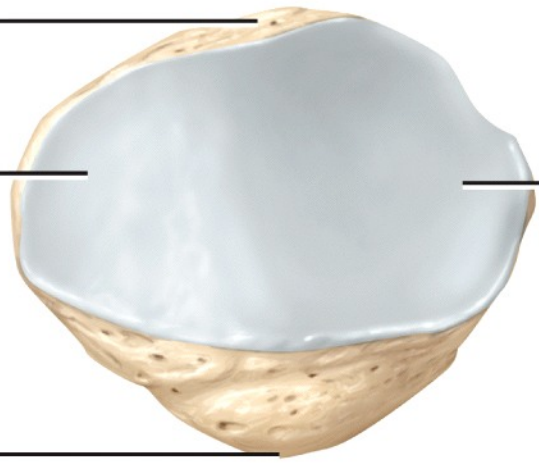


(a) Anterior view

Base

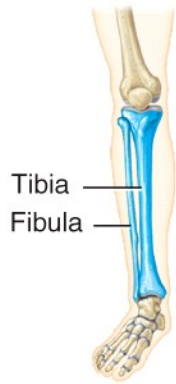
Articular facet
for medial
femoral condyle

Apex

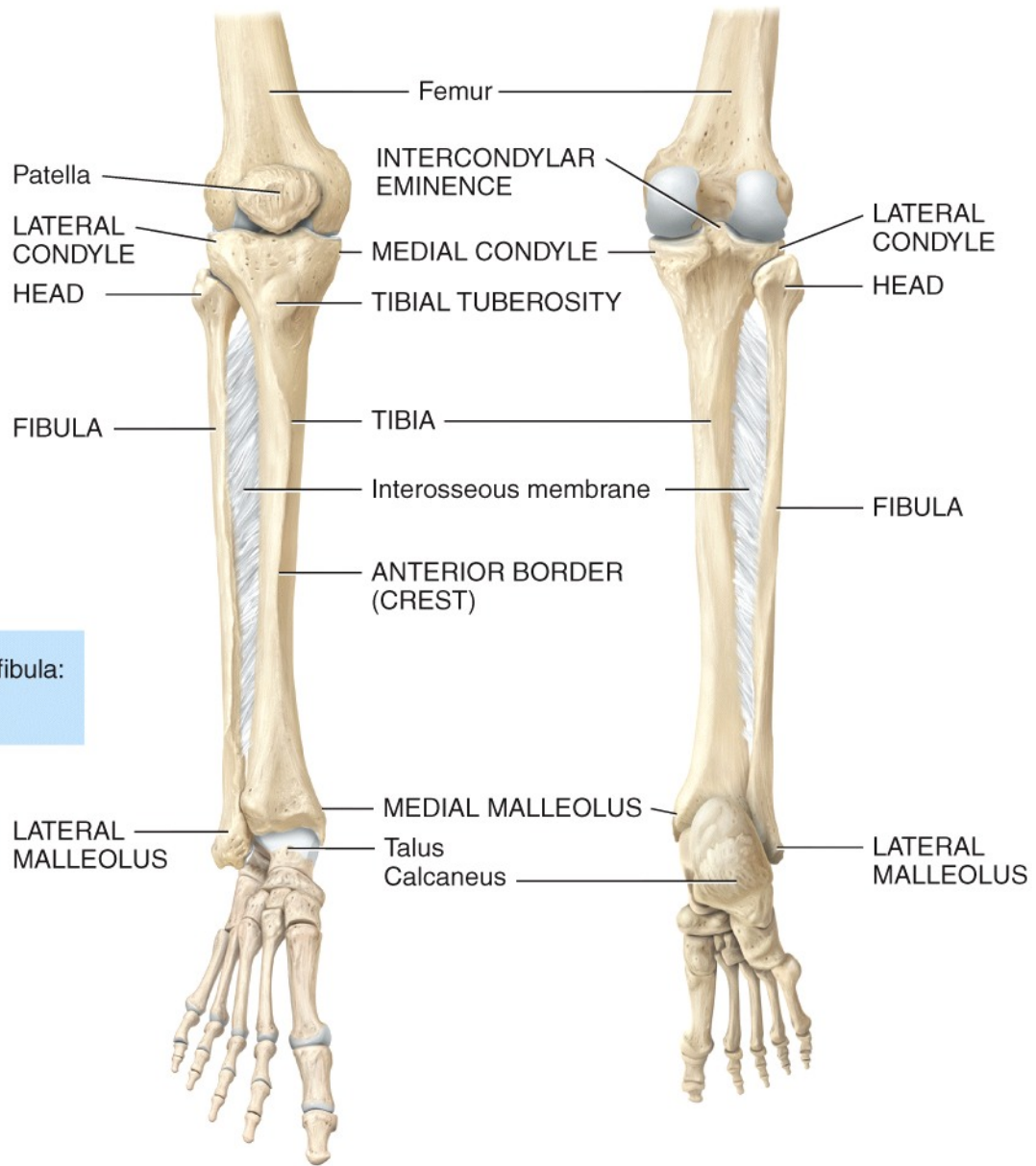


(b) Posterior view

Articular
facet
for lateral
femoral
condyle

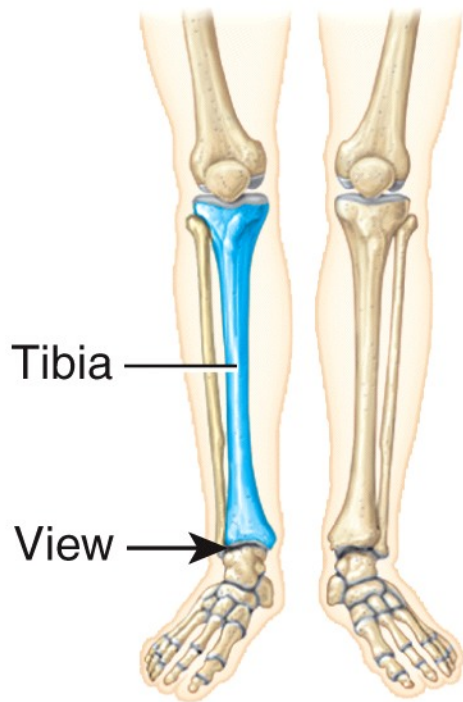


MNEMONIC for location of tibia and fibula:
The fibu**LA** is **LA**teral.



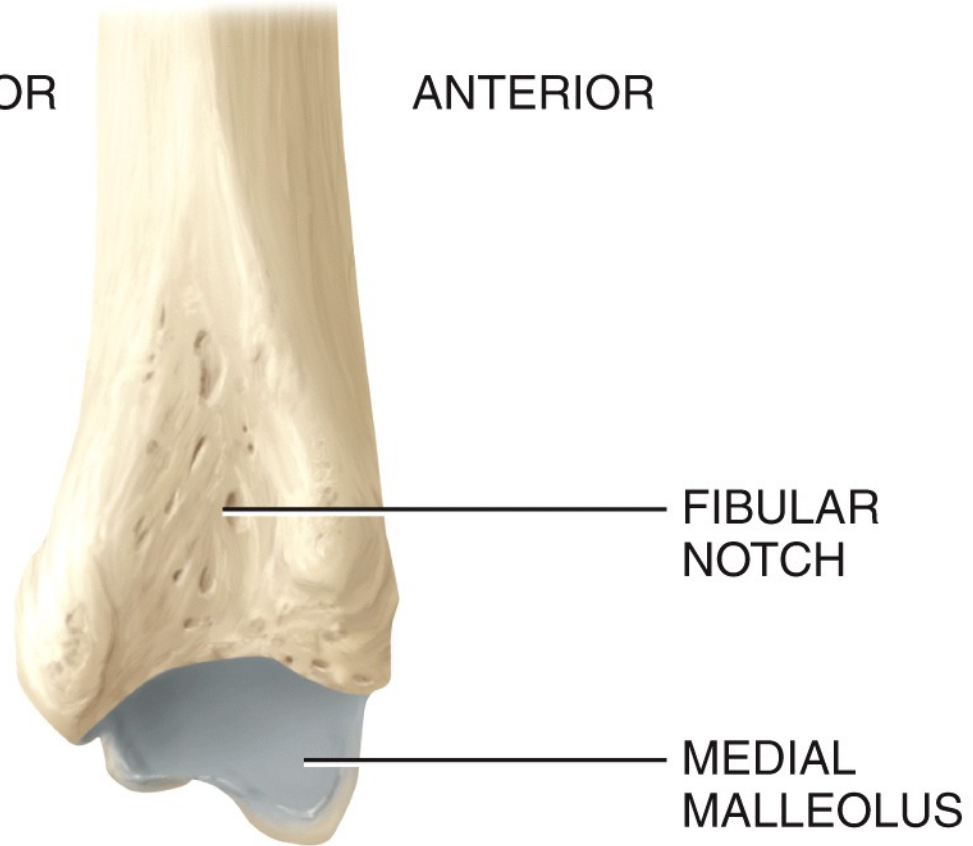
(a) Anterior view

(b) Posterior view

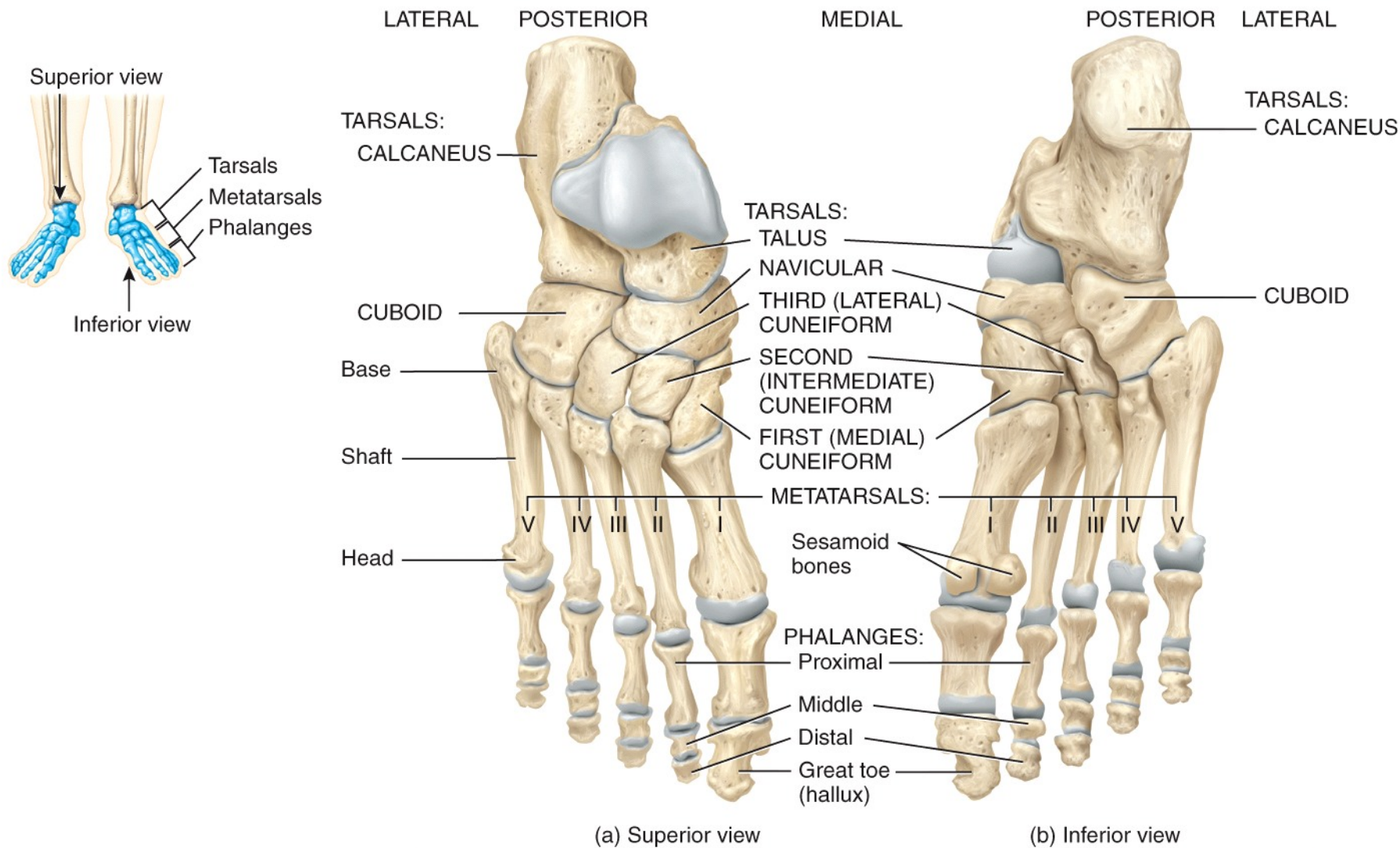


POSTERIOR

ANTERIOR

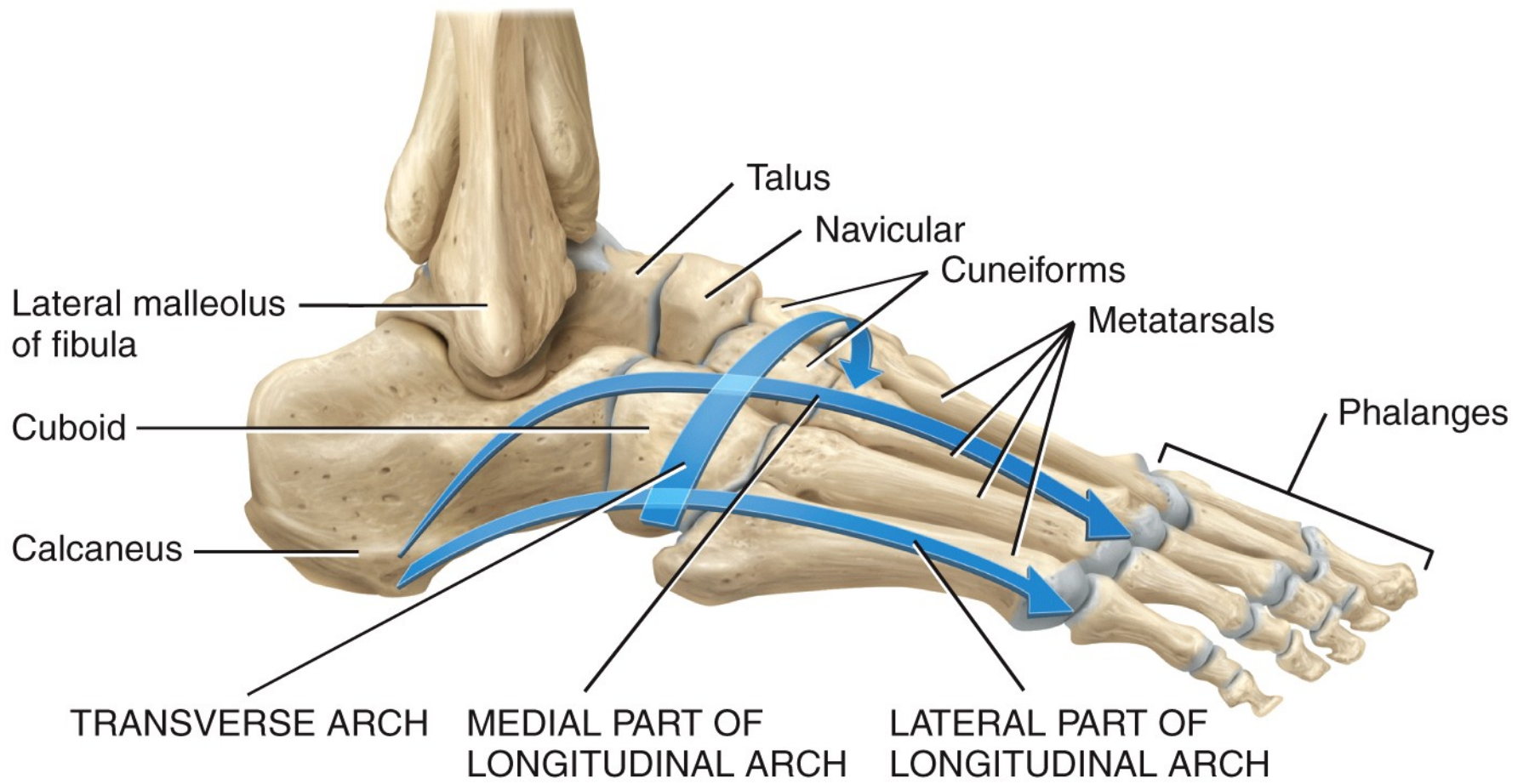


(c) Lateral view of distal end of tibia

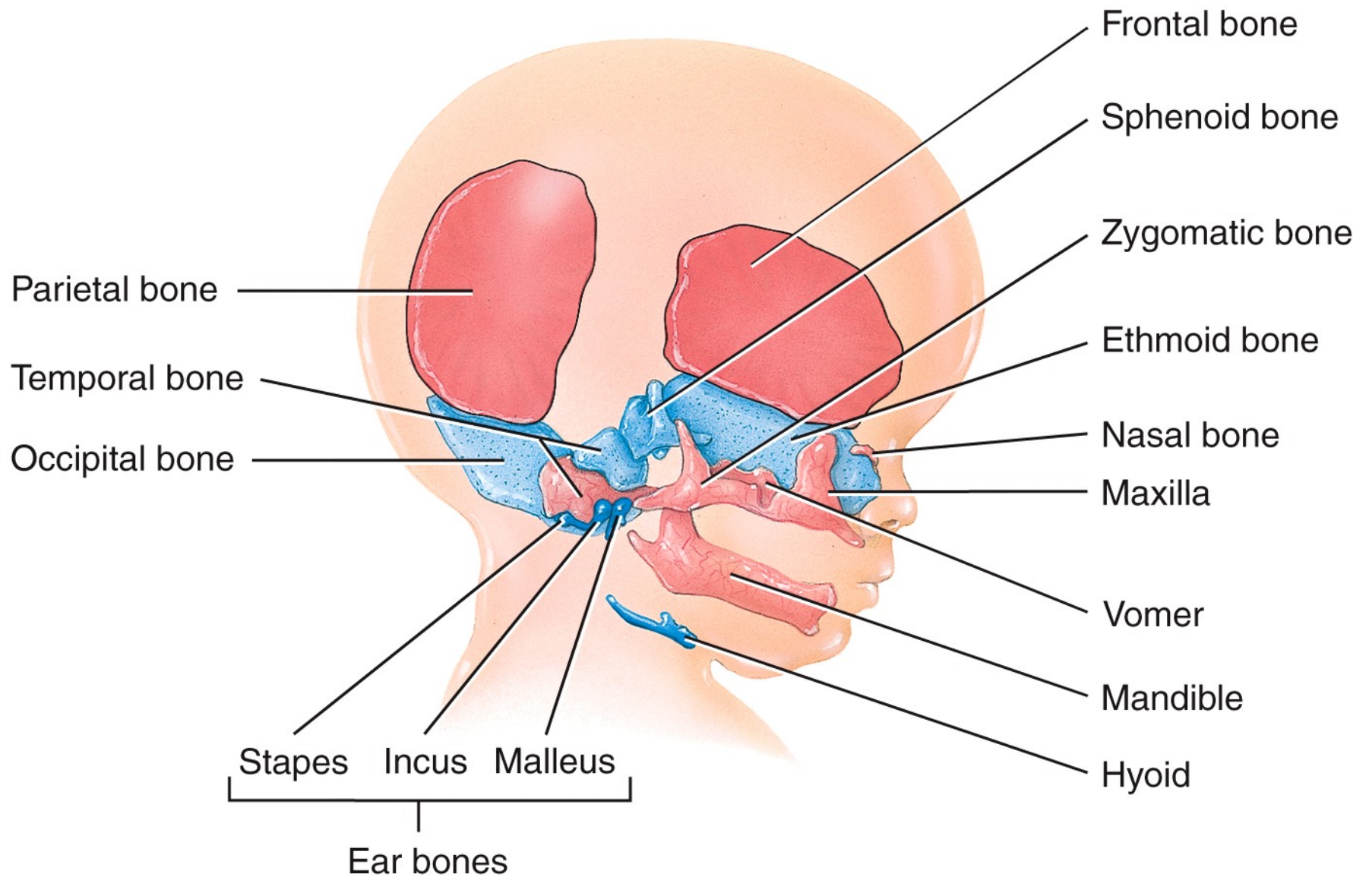


MNEMONIC for tarsals:

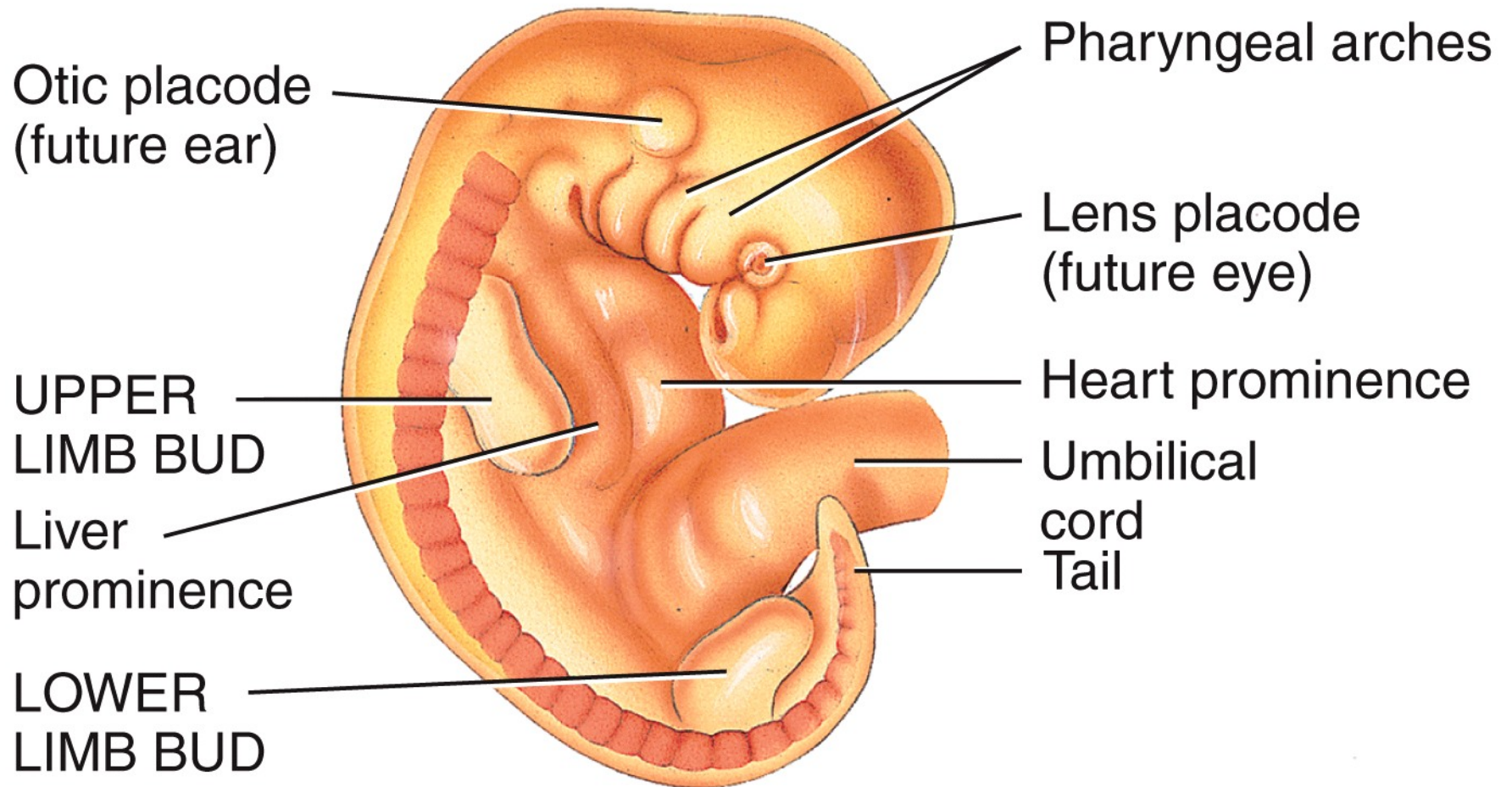
Tall Centers Never Take Shots From Corners.
Talus Calcaneus Navicular Third cuneiform Second cuneiform First cuneiform Cuboid



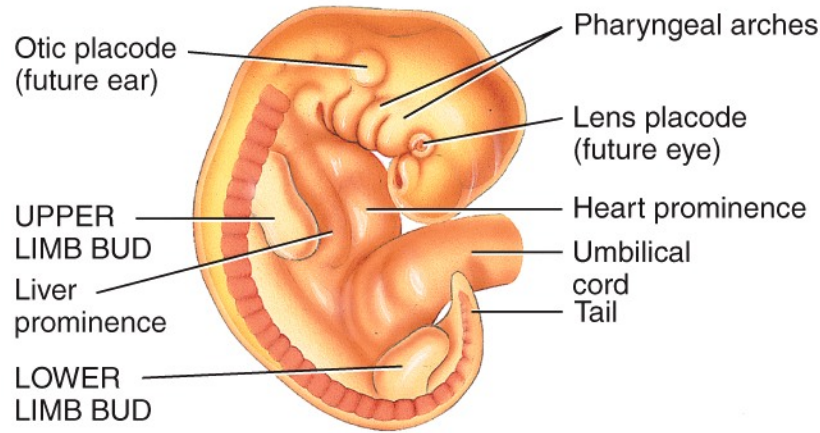
Lateral view of arches



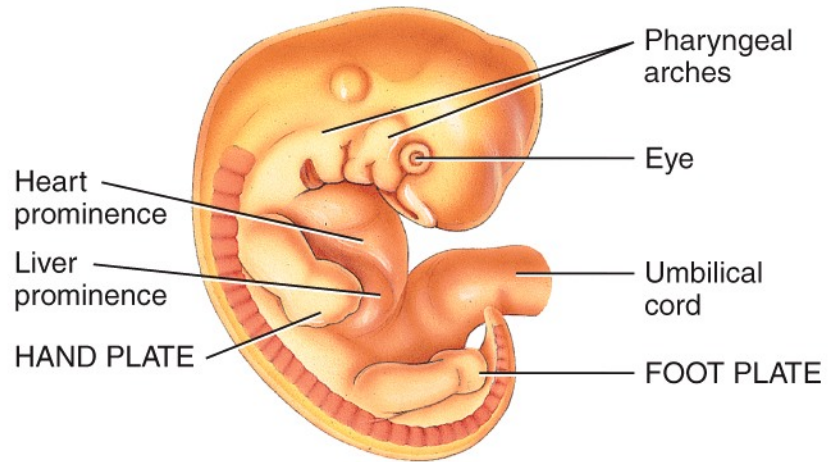
(a) Development of the skull



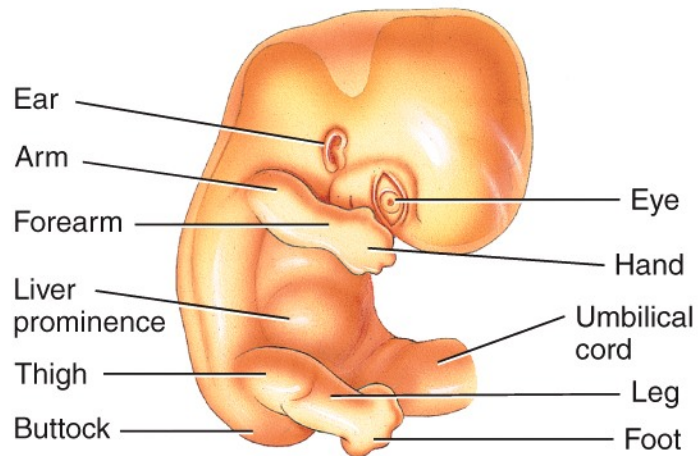
(b) Four-week embryo showing development of free limb buds



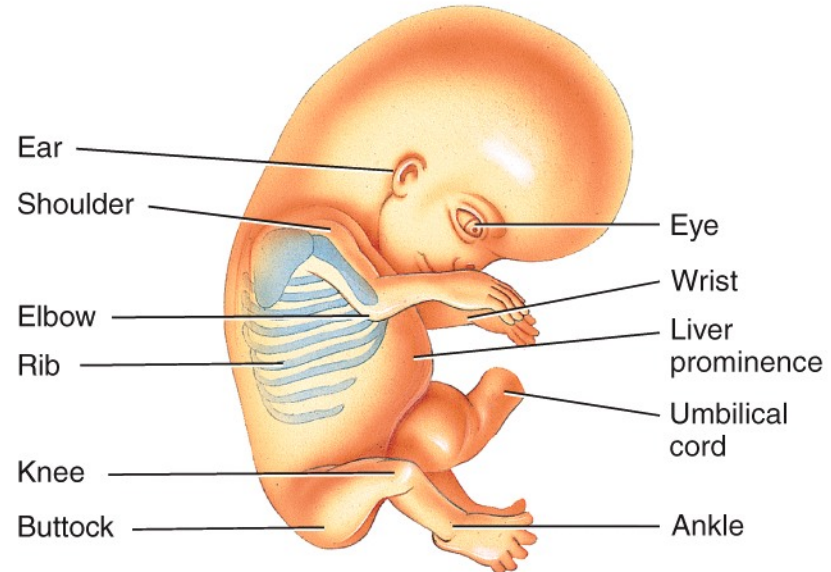
(b) Four-week embryo showing development of free limb buds



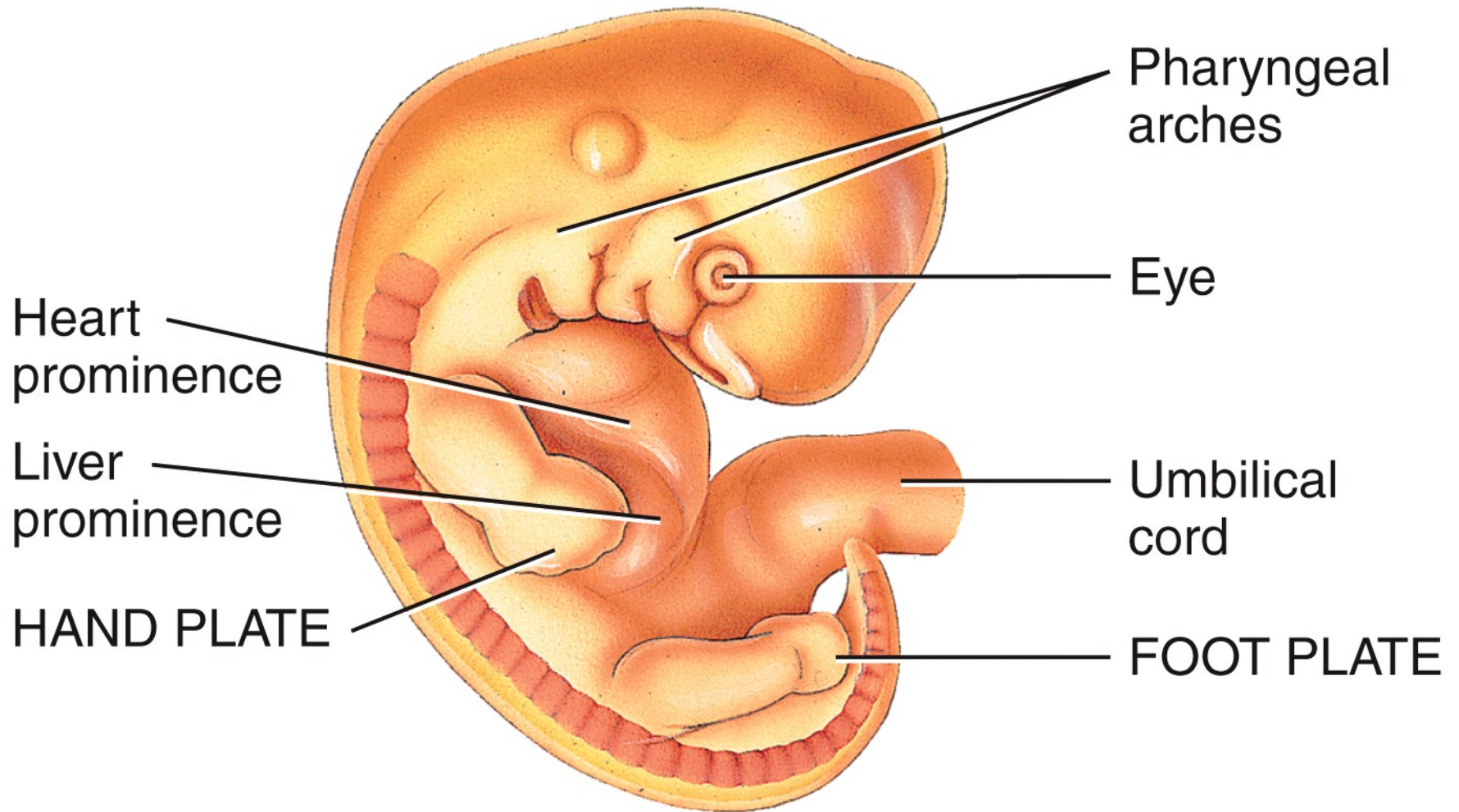
(c) Six-week embryo showing development of hand and foot plates



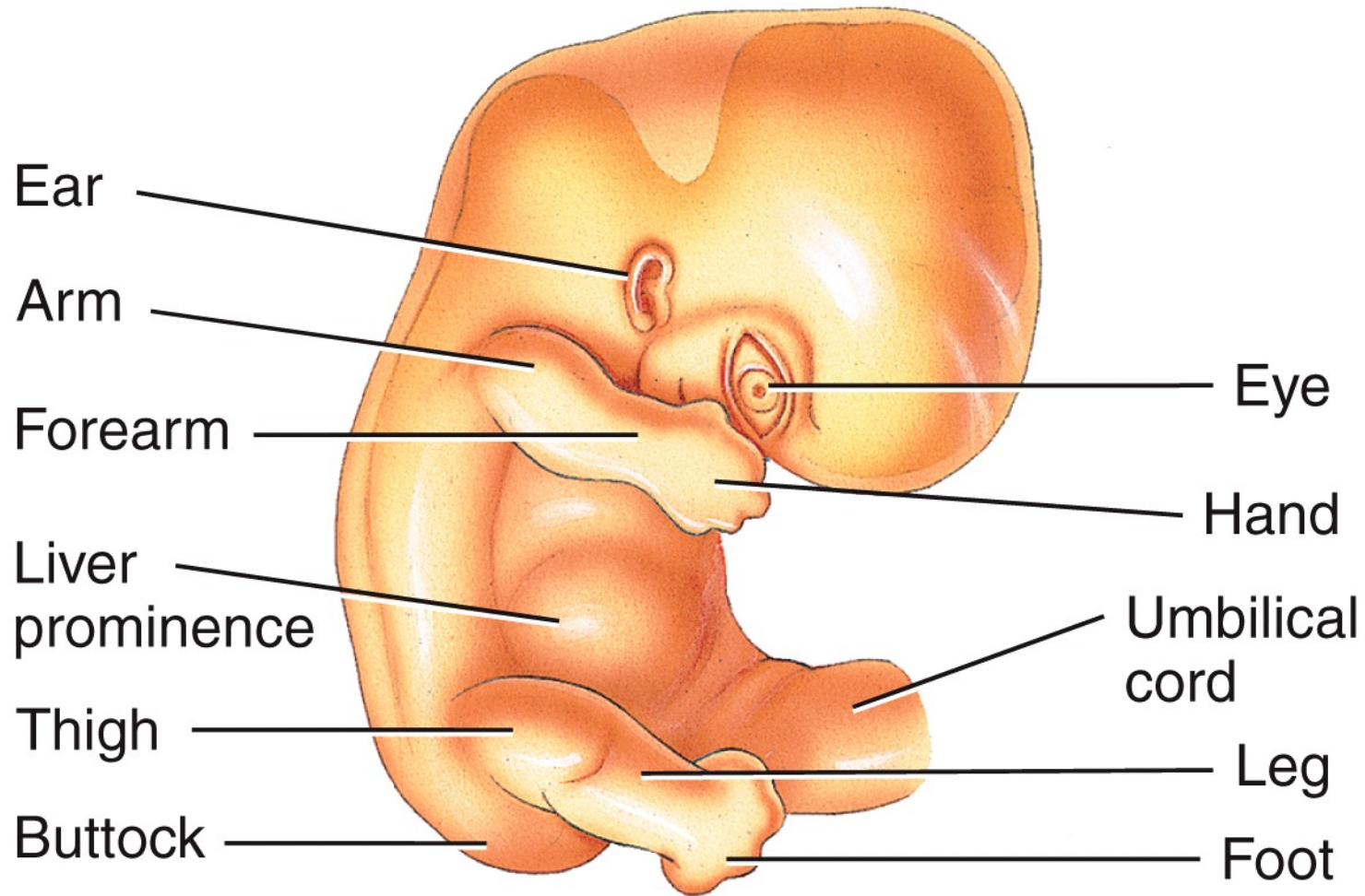
(d) Seven-week embryo showing development of arm, forearm, and hand in free upper limb bud and thigh, leg, and foot in free lower limb bud



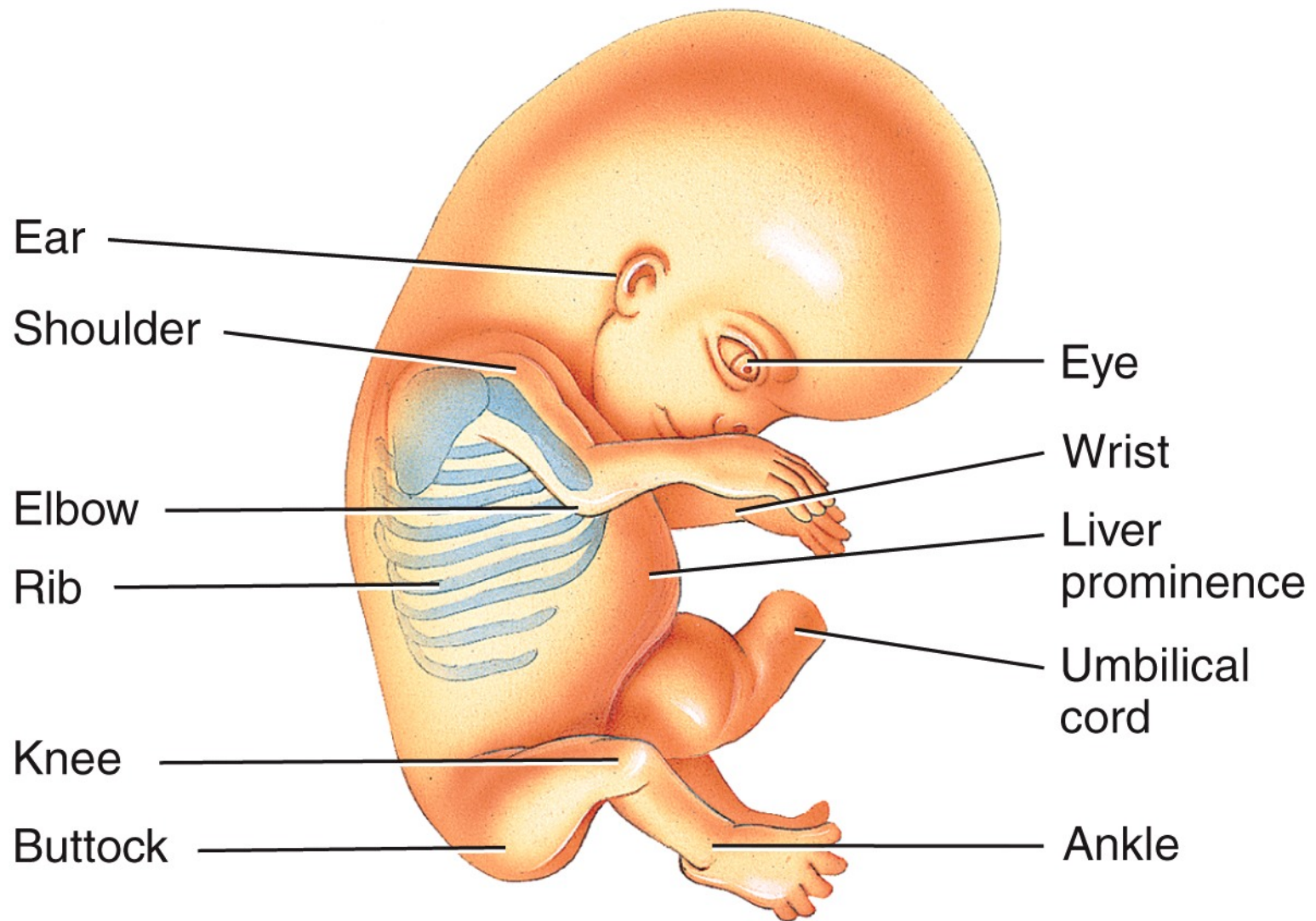
(e) Eight-week embryo in which free limb buds have developed into free upper and lower limbs



(c) Six-week embryo showing development of hand and foot plates



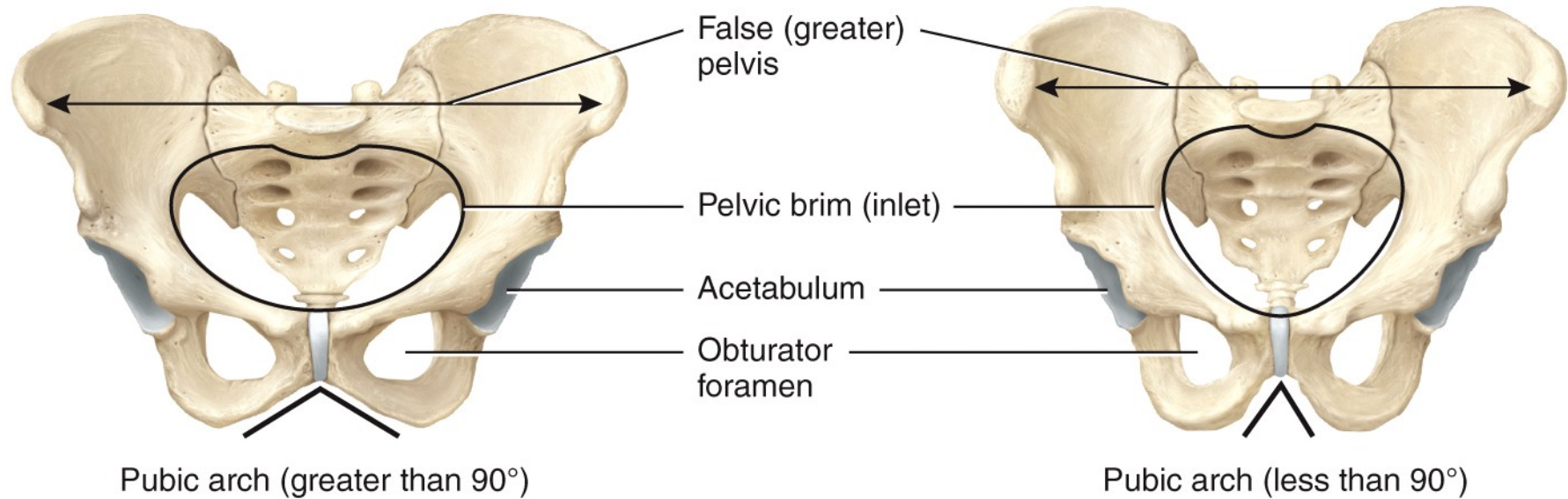
(d) Seven-week embryo showing development of arm, forearm, and hand in free upper limb bud and thigh, leg, and foot in free lower limb bud



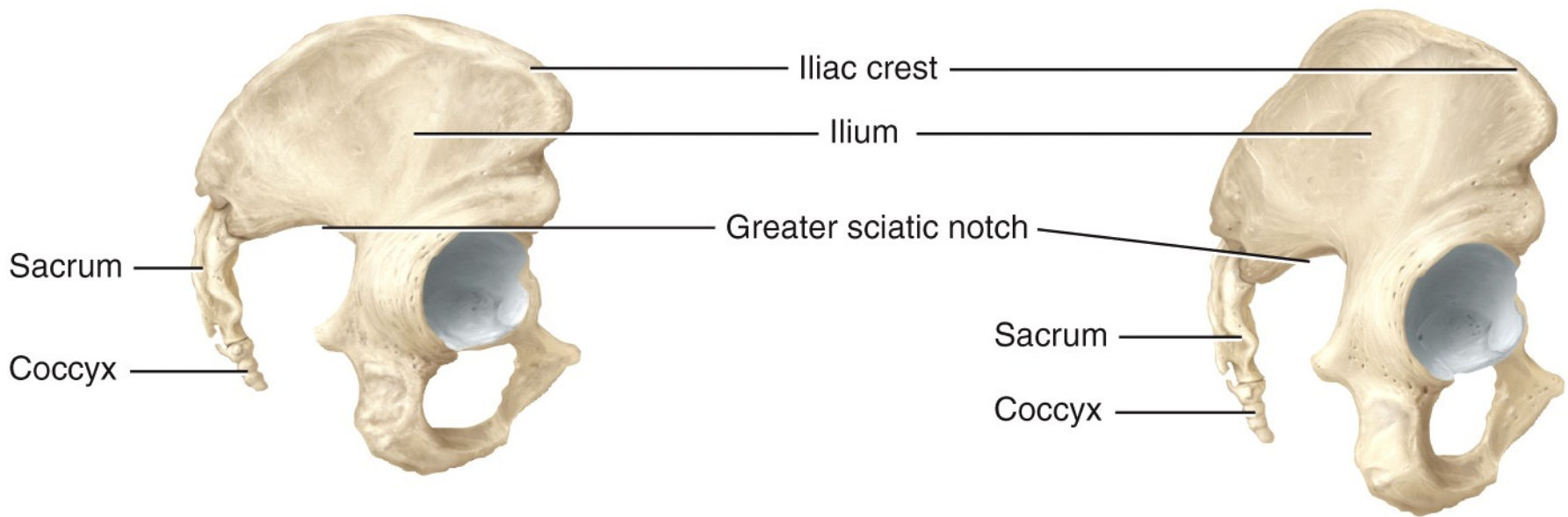
(e) Eight-week embryo in which free limb buds have developed into free upper and lower limbs



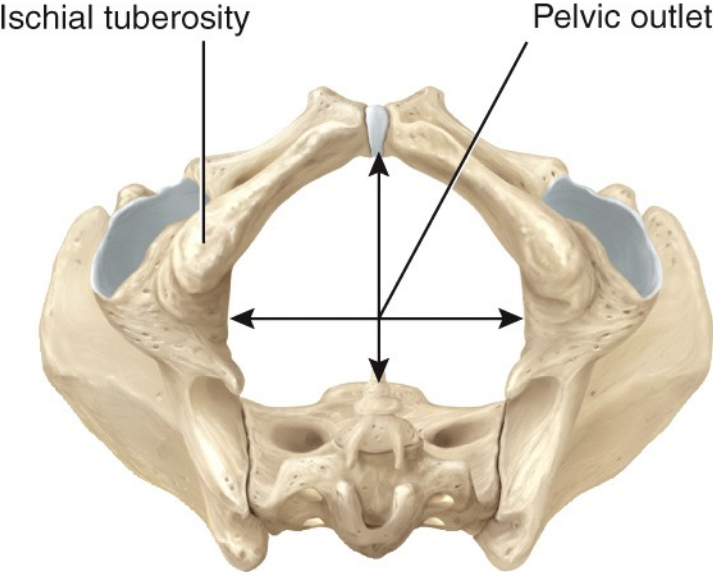
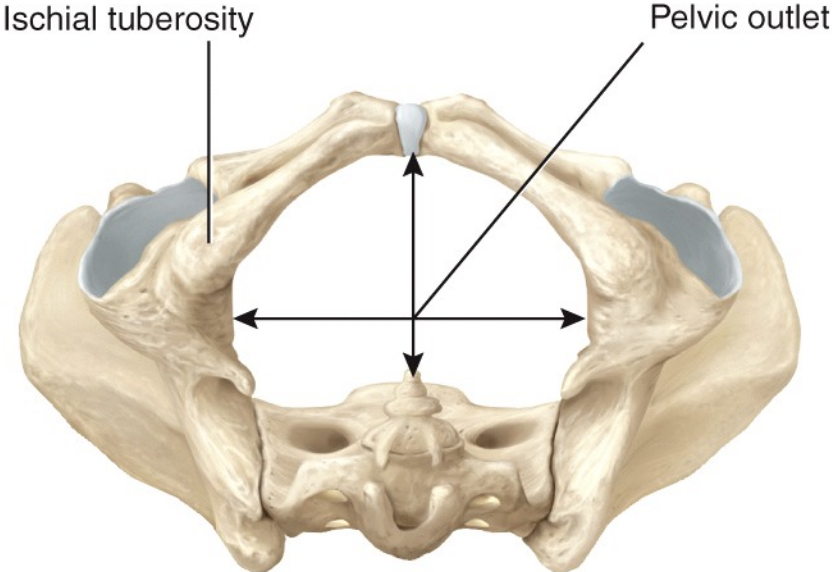
Stockbyte/Getty Images



Anterior views



Right lateral views



Inferior views