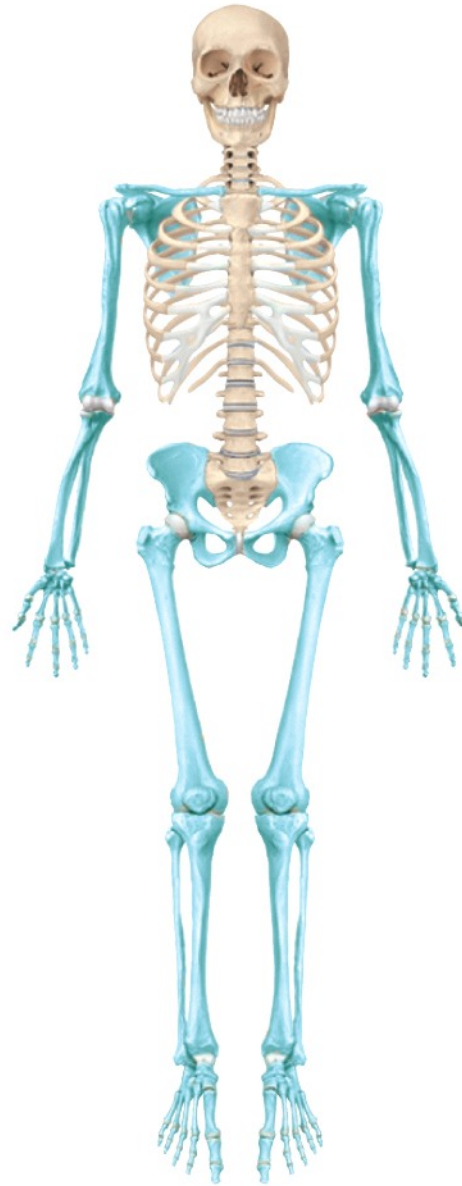

C7

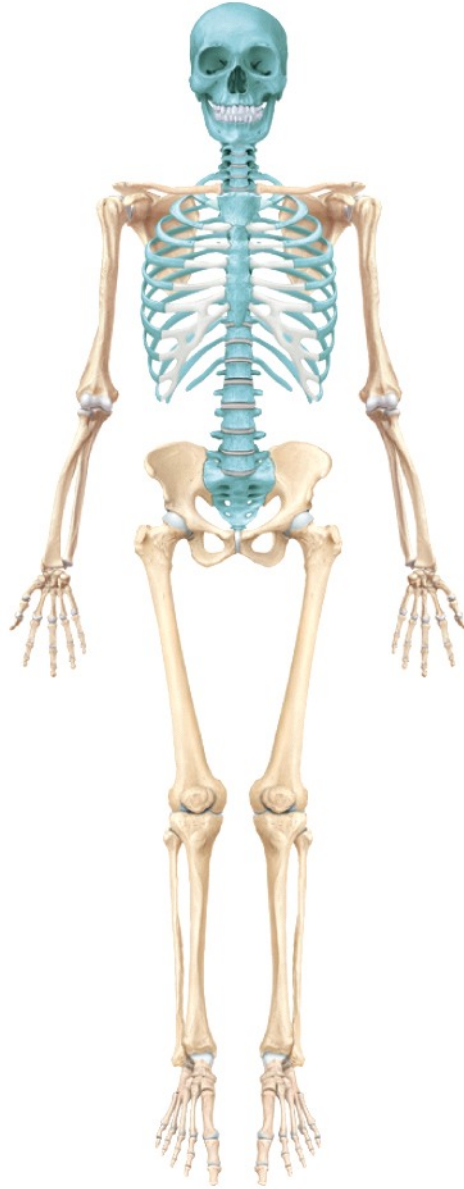The Axial Skeletal System

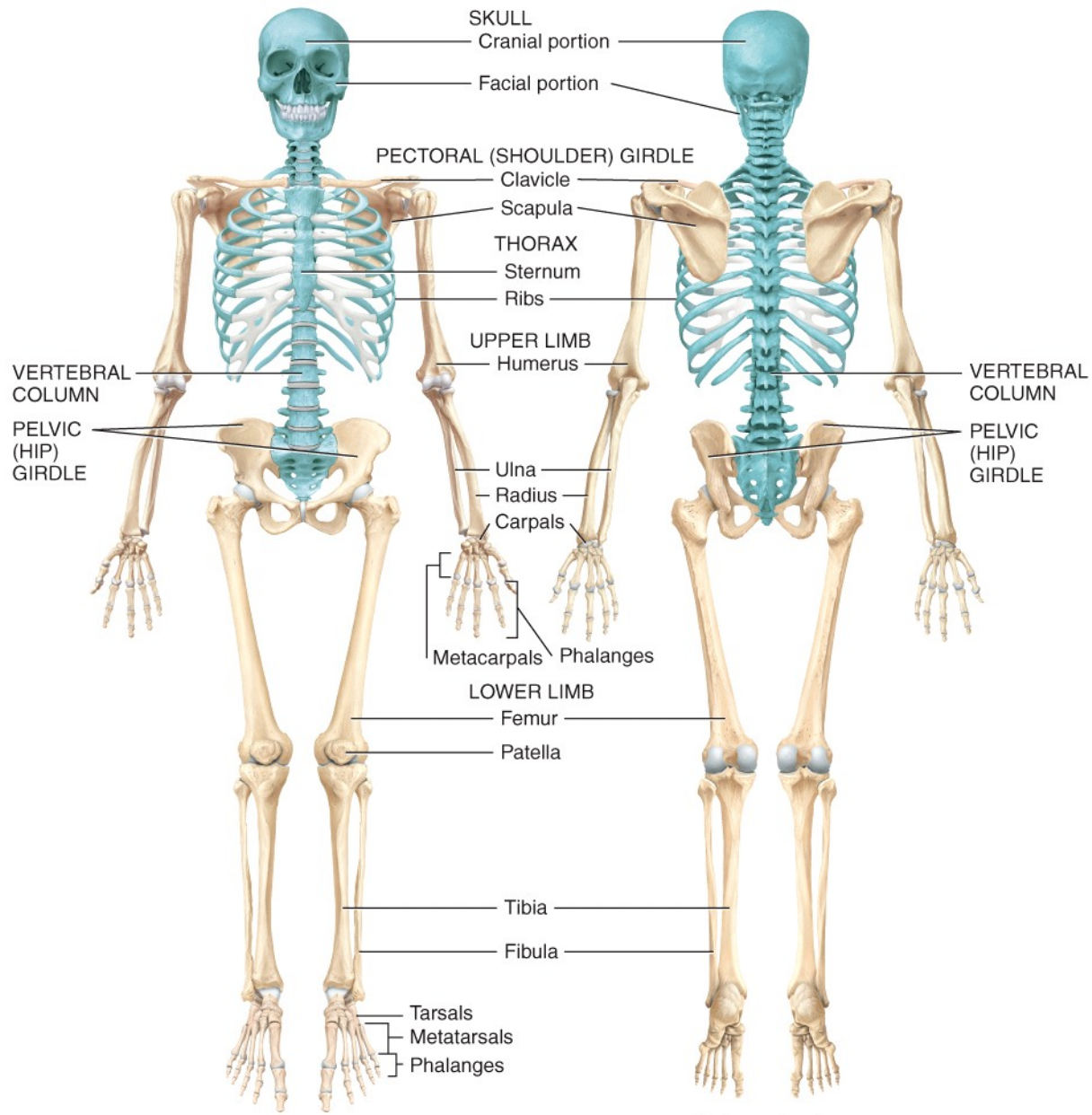
Images Only

Appendicular skeleton



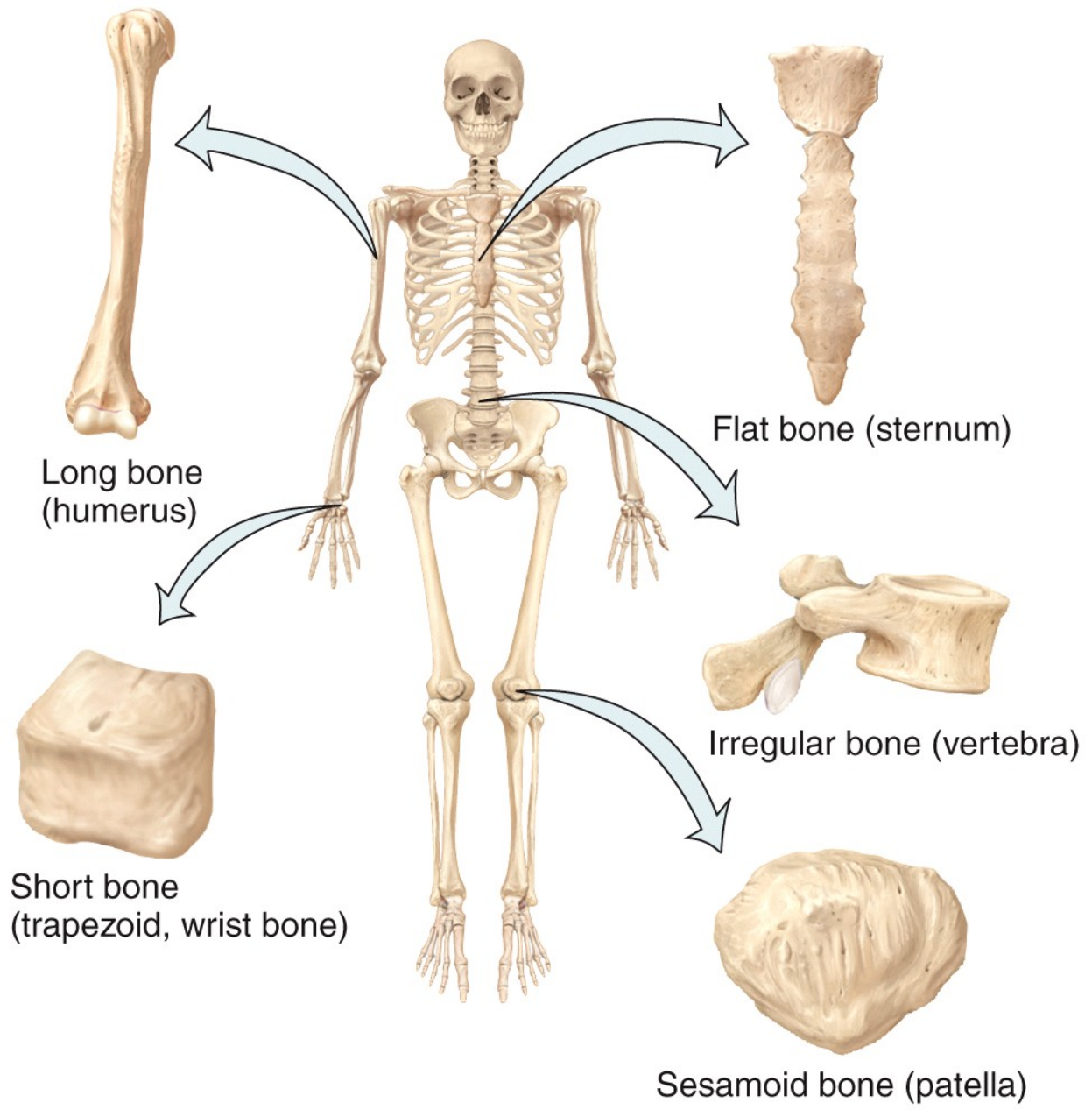
Axial skeleton





(a) Anterior view

(b) Posterior view



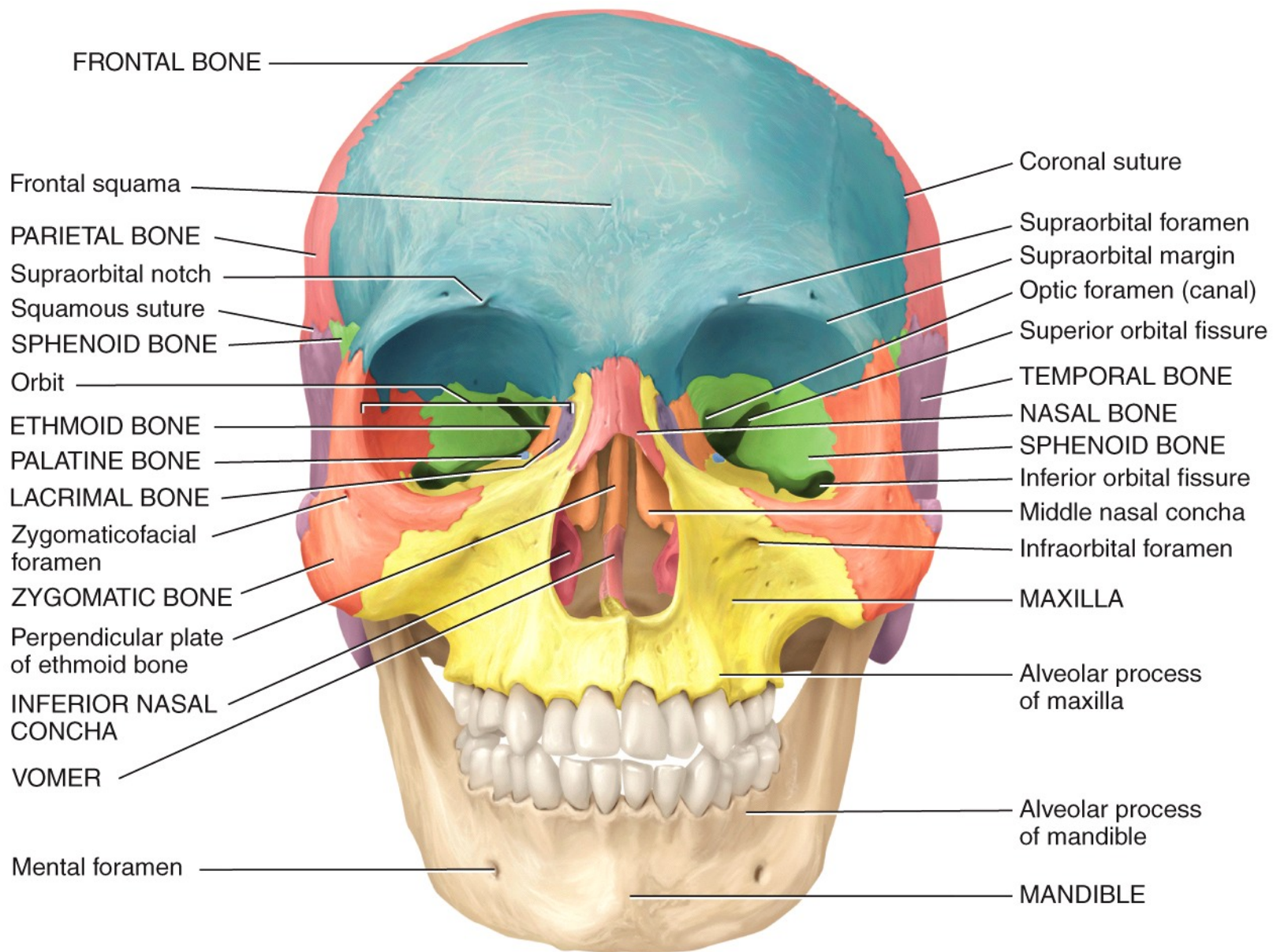
Long bone
(humerus)

Flat bone (sternum)

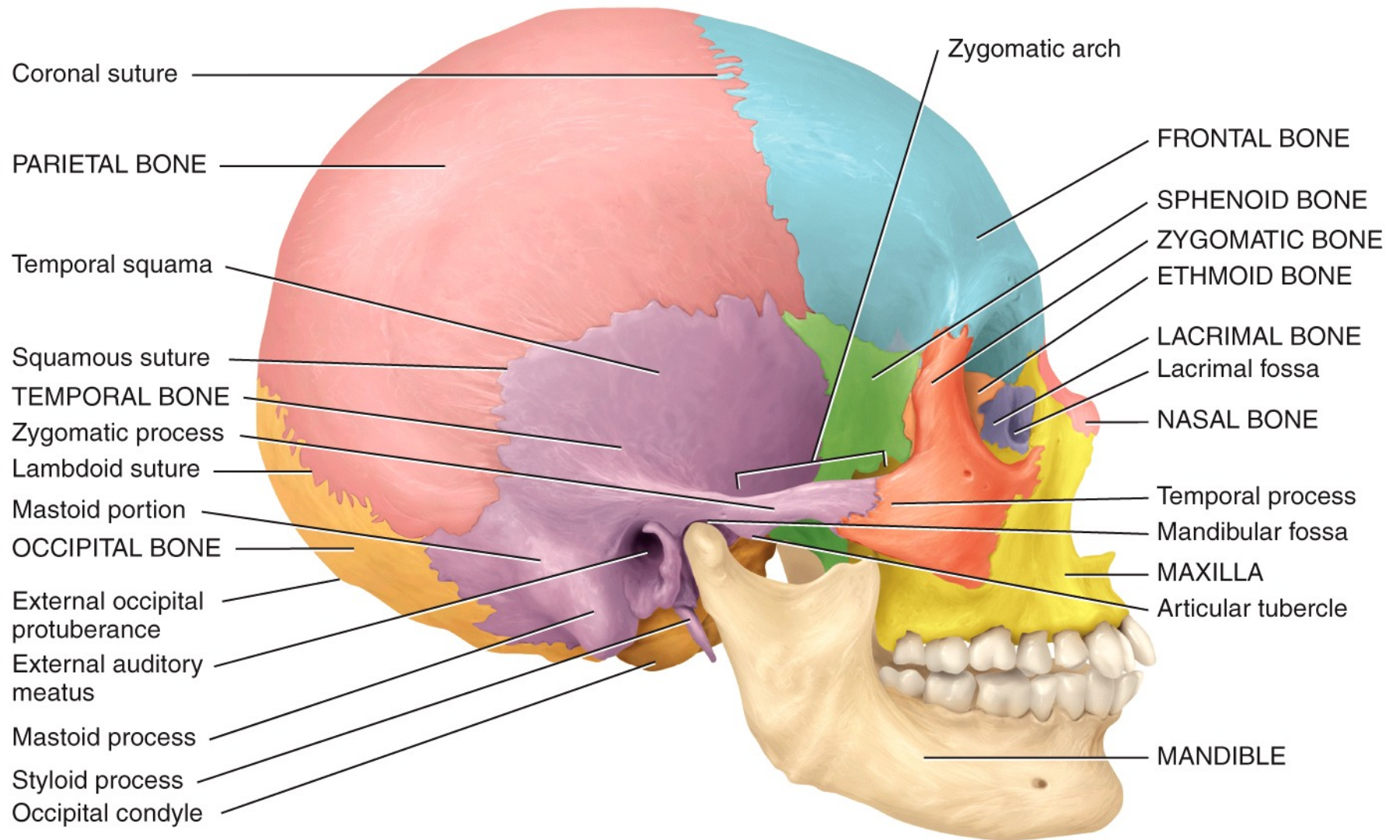
Short bone
(trapezoid, wrist bone)

Irregular bone (vertebra)

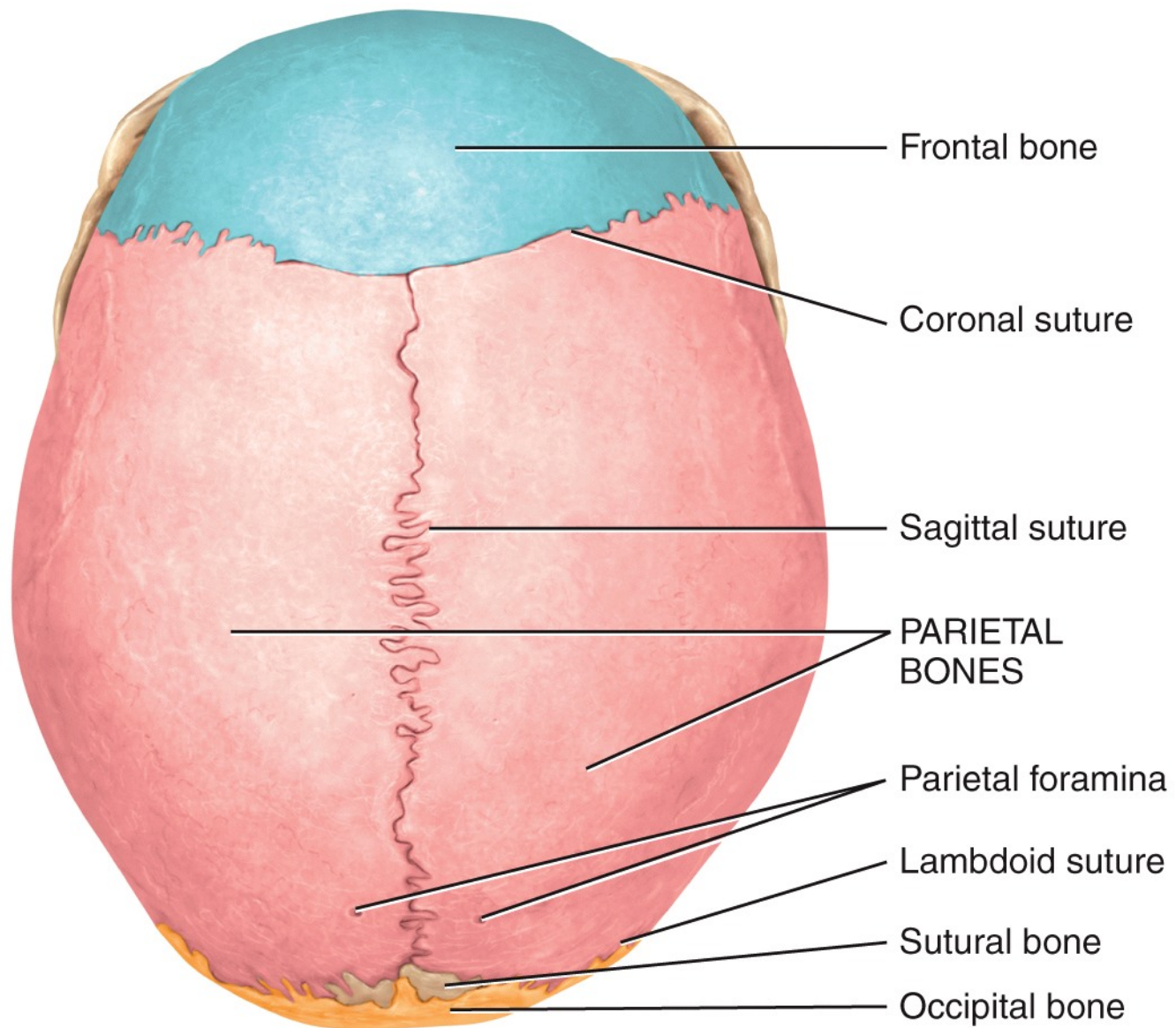
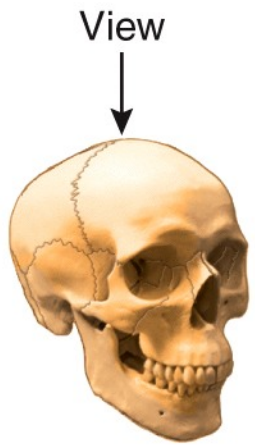
Sesamoid bone (patella)



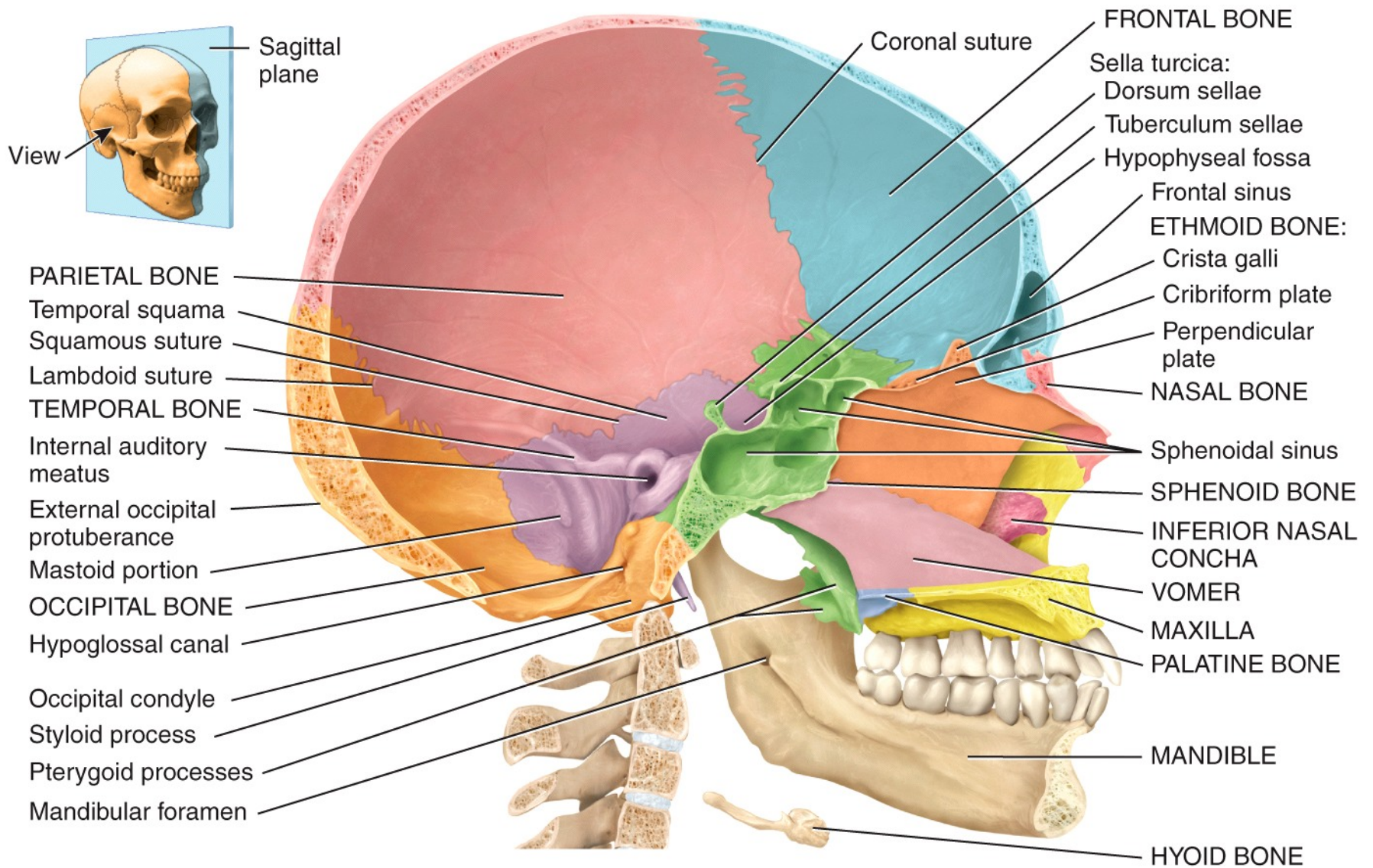
Anterior view



(a) Right lateral view



(b) Superior view



Medial view of sagittal section

Sagittal suture

PARIETAL BONES

Sutural bones

OCCIPITAL BONE

Lambdoid suture

External occipital protuberance

Superior nuchal line

TEMPORAL BONE

Inferior nuchal line

Mastoid process

Foramen magnum

Styloid process

Inferior nasal concha

Occipital condyle

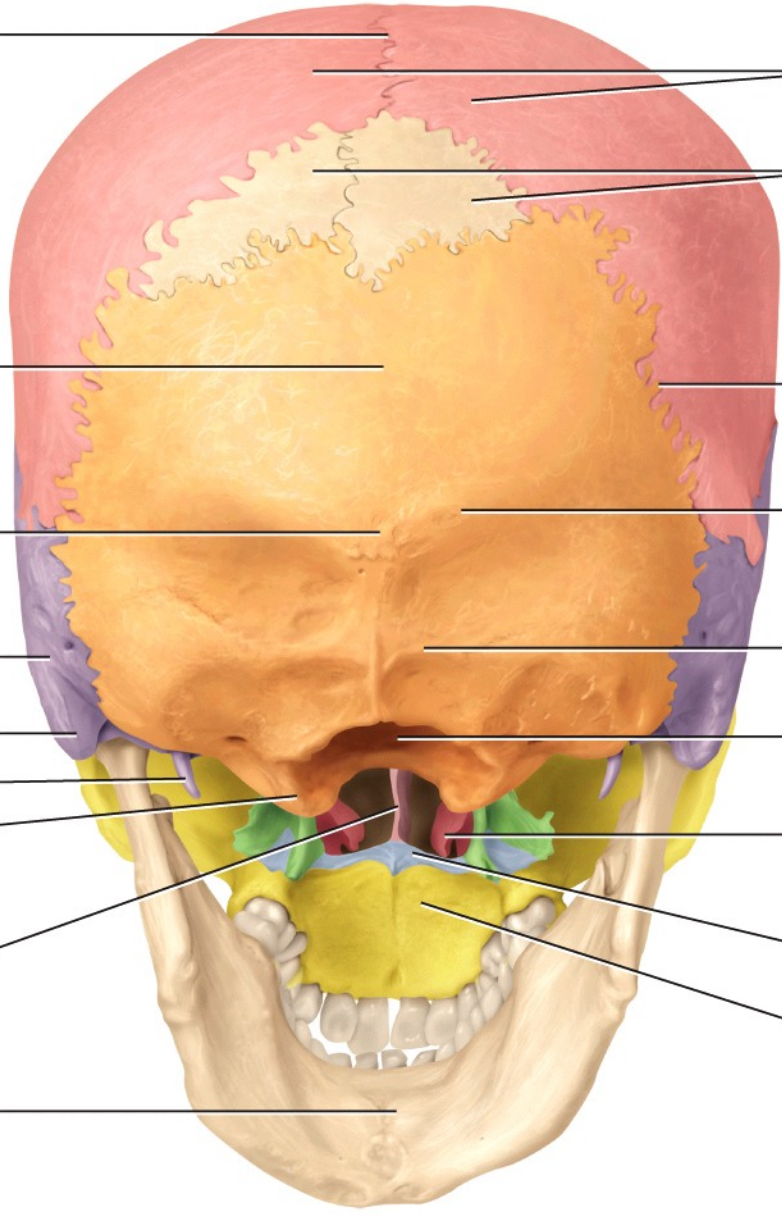
Hard palate:

VOMER

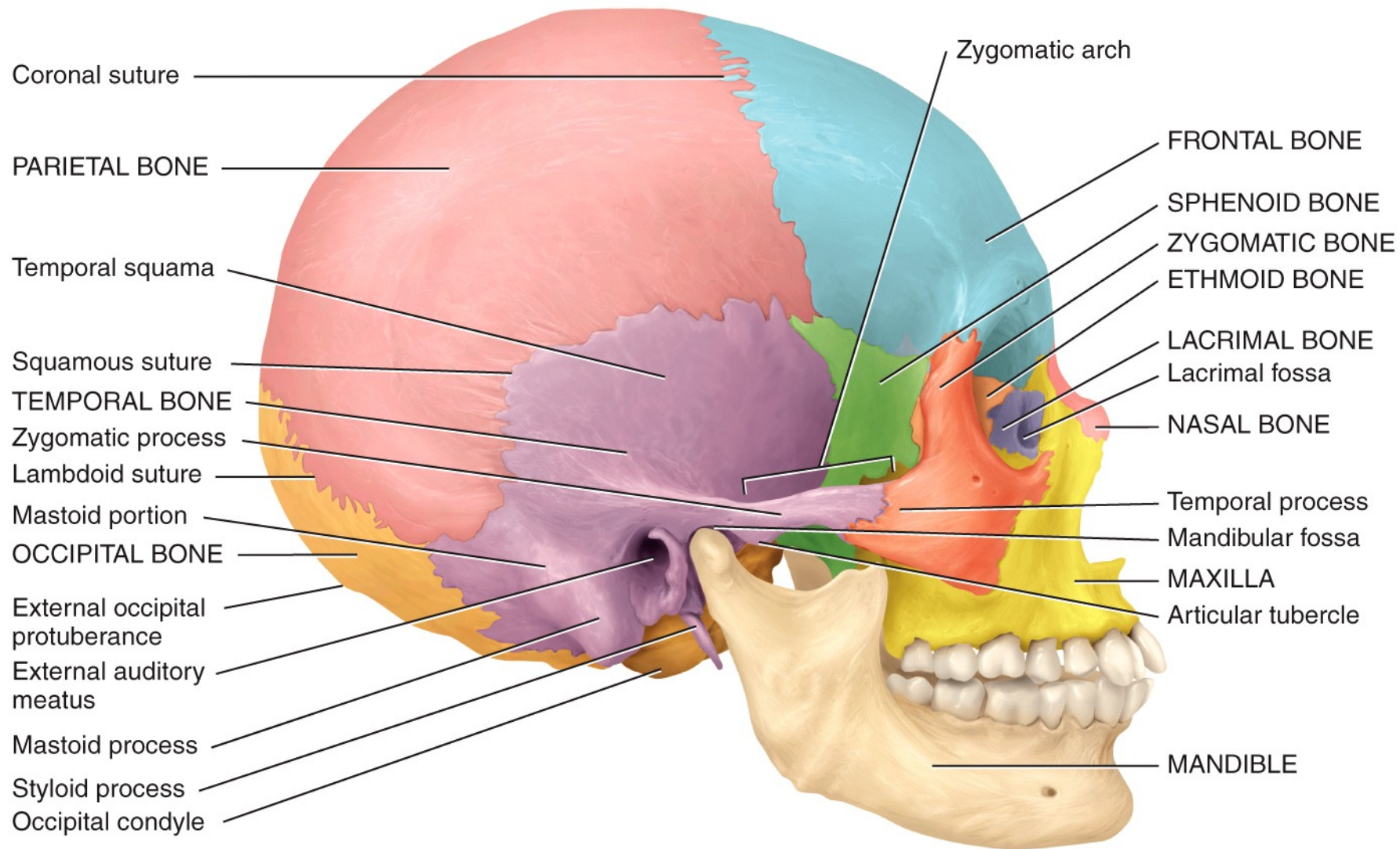
Horizontal plate of palatine bone

Palatine process of maxilla

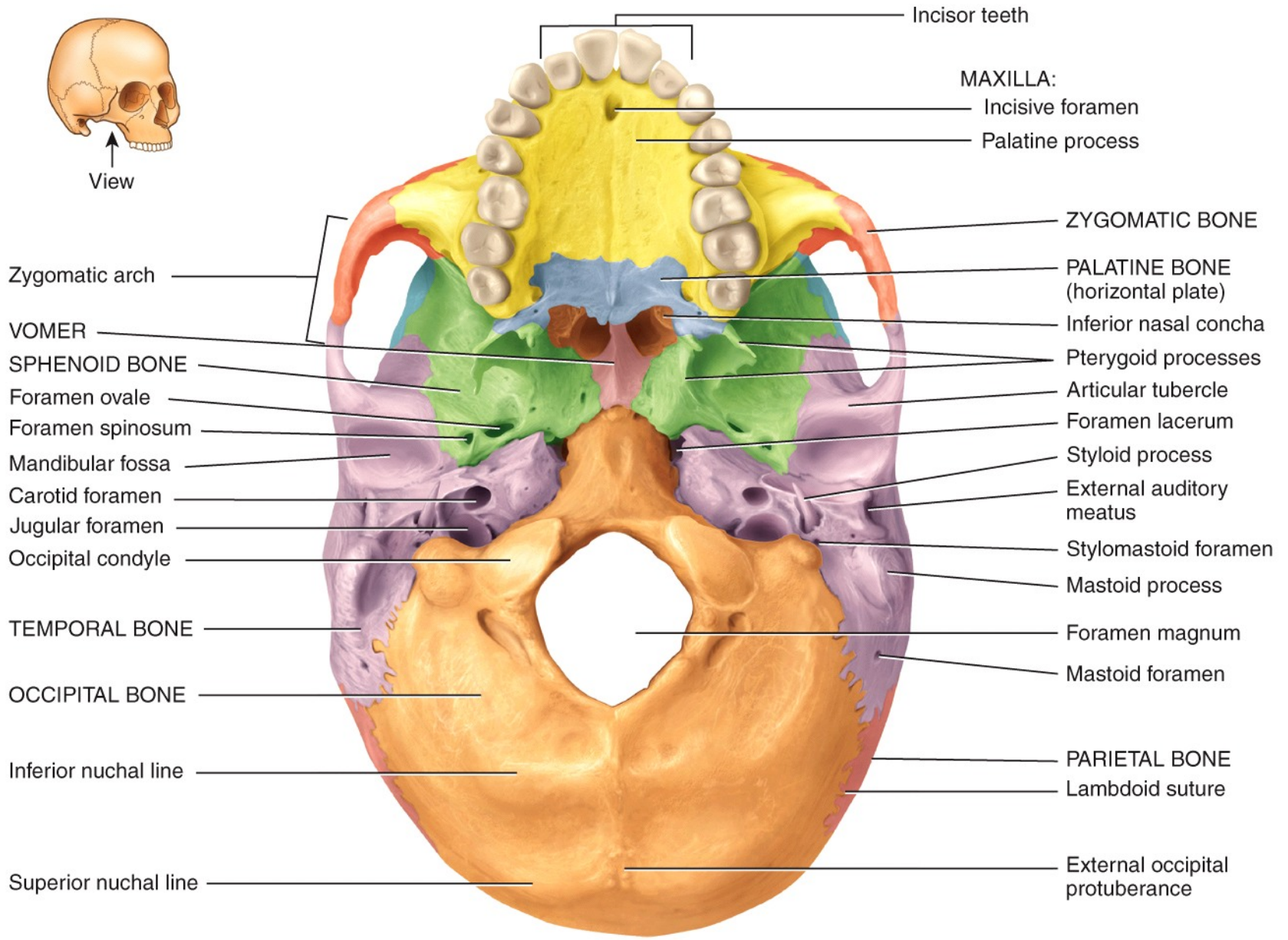
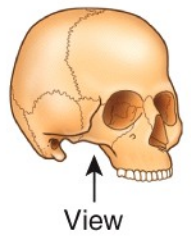
MANDIBLE



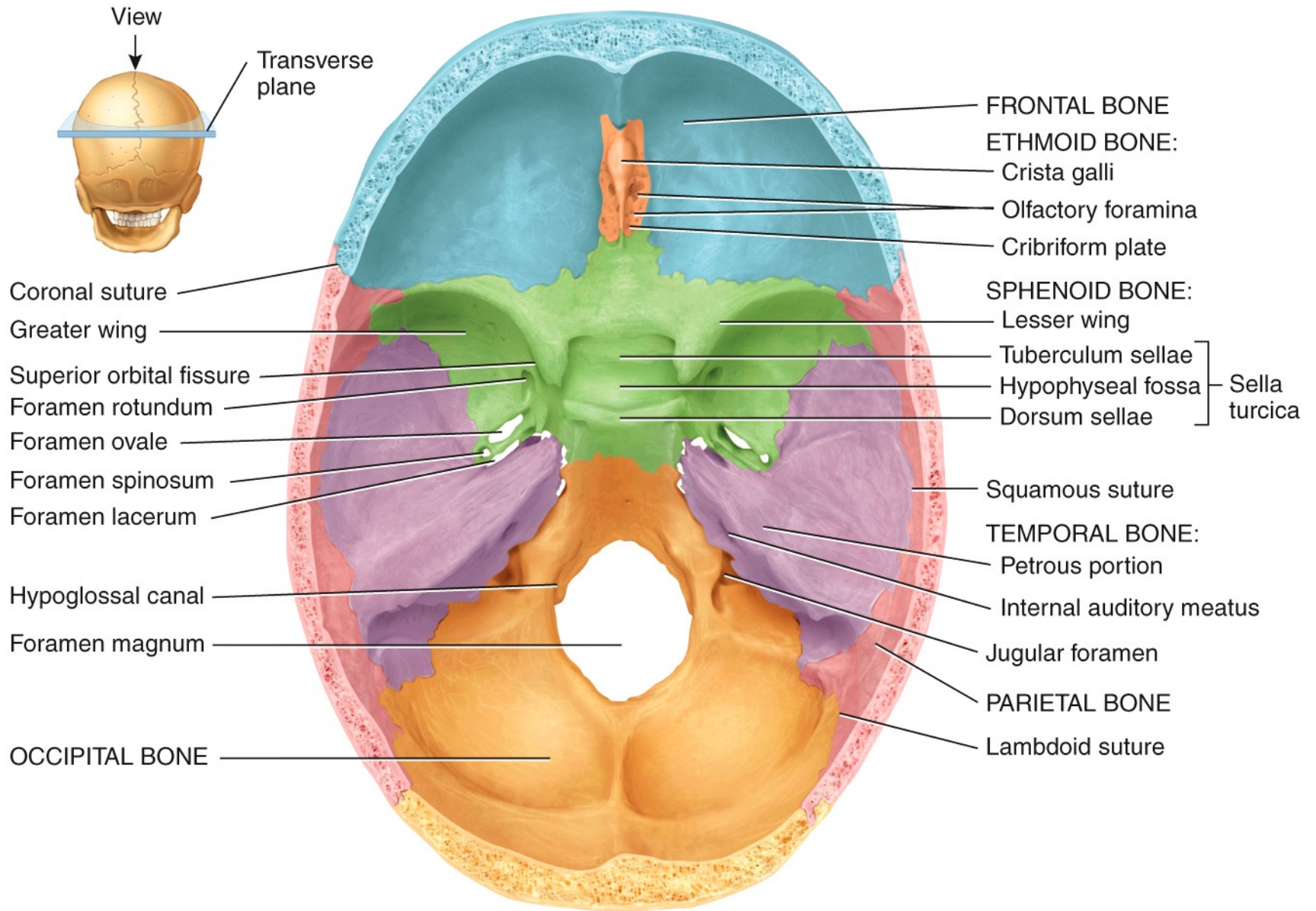
Posteroinferior view



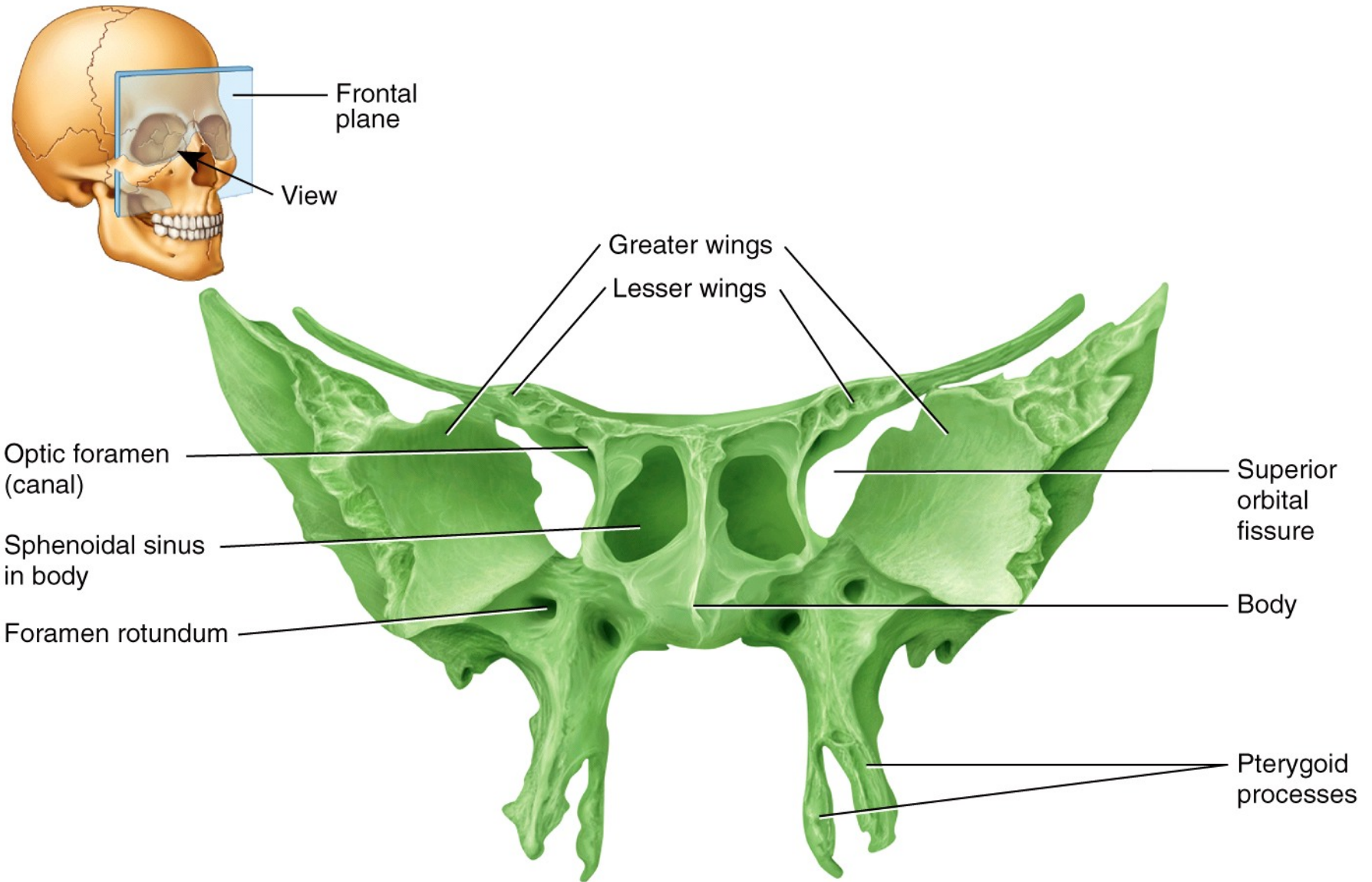
(a) Right lateral view



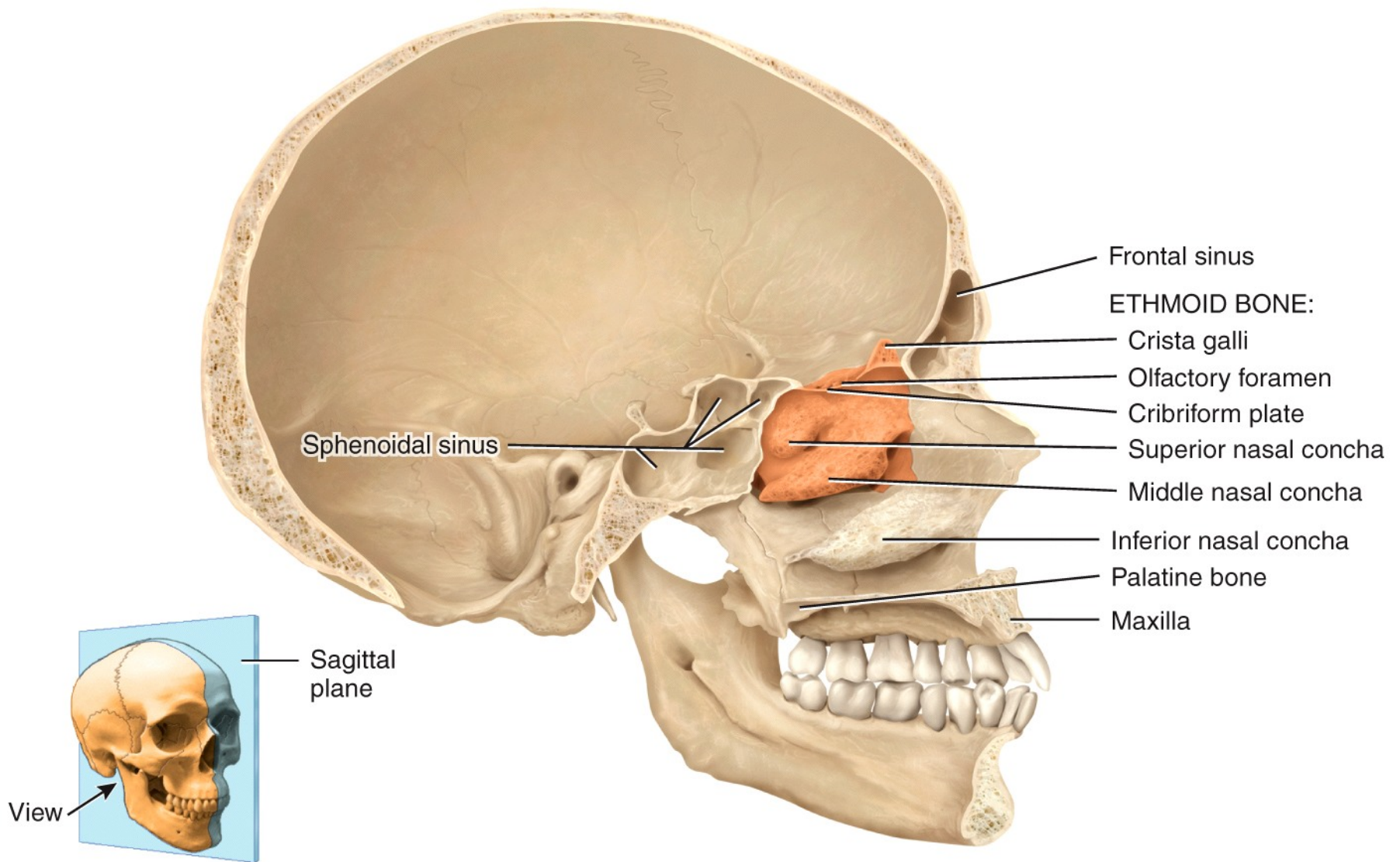
Inferior view



(a) Superior view of sphenoid bone in floor of cranium

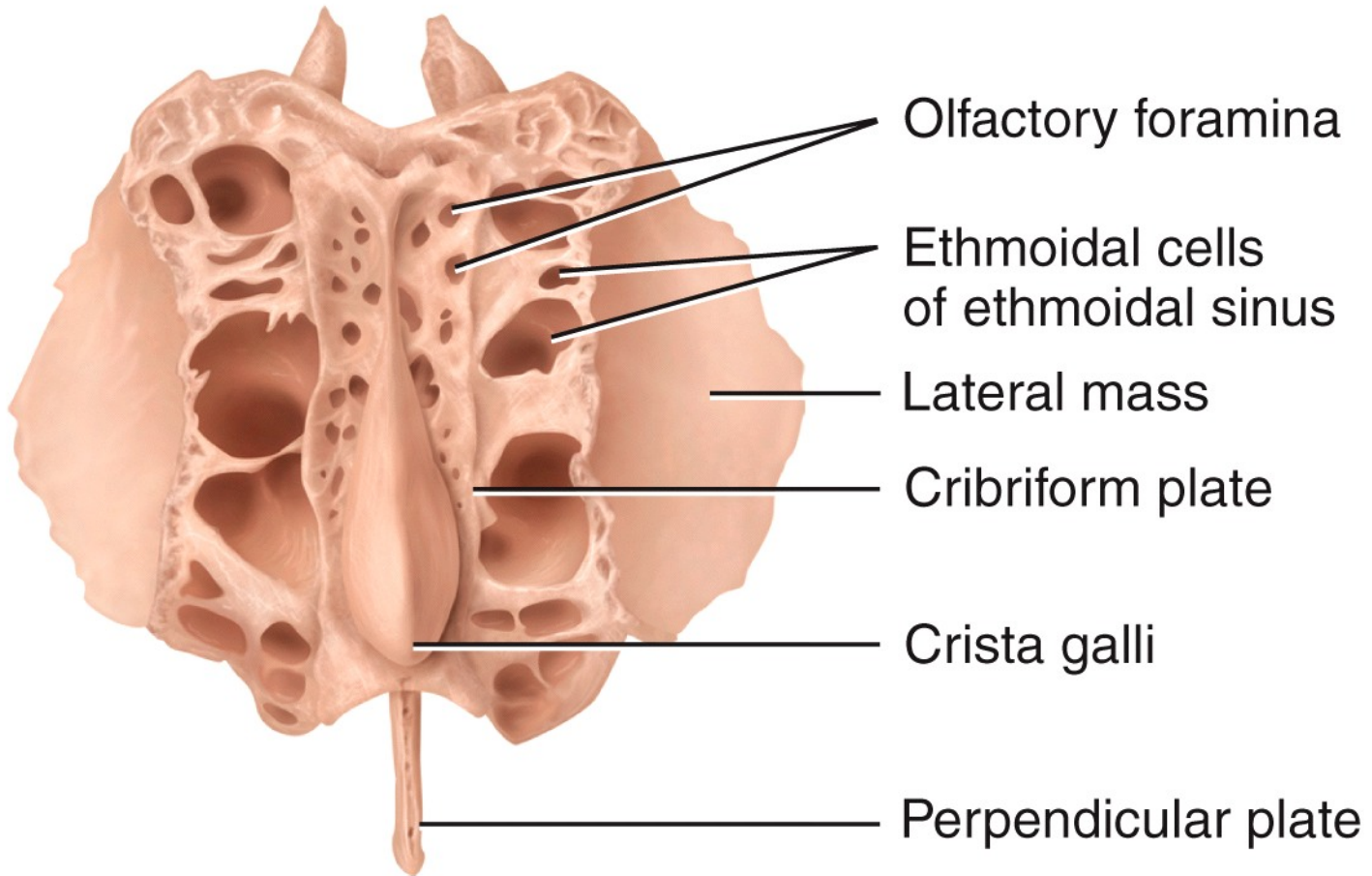


(b) Anterior view of sphenoid bone



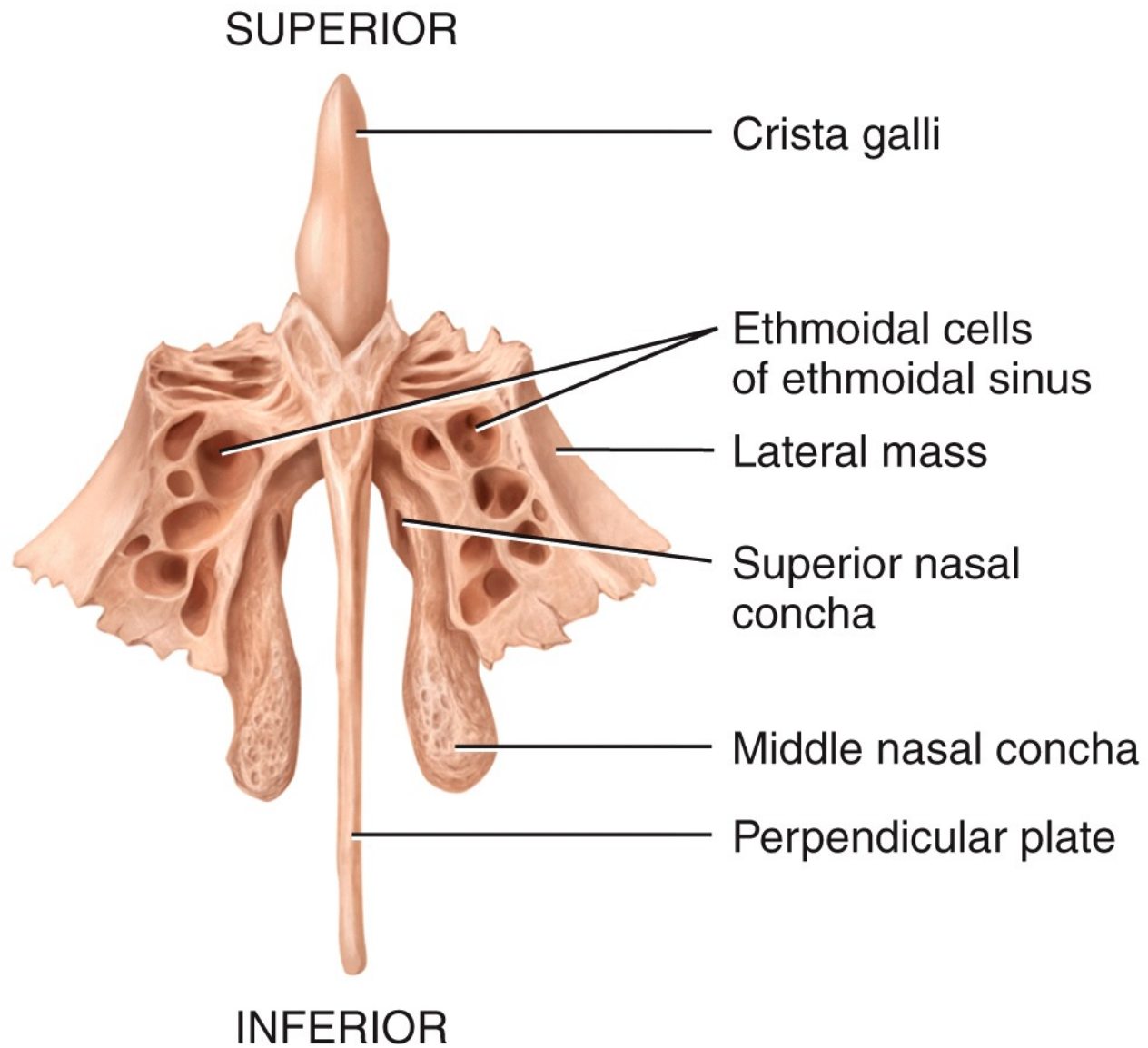
(a) Medial view of sagittal section

POSTERIOR

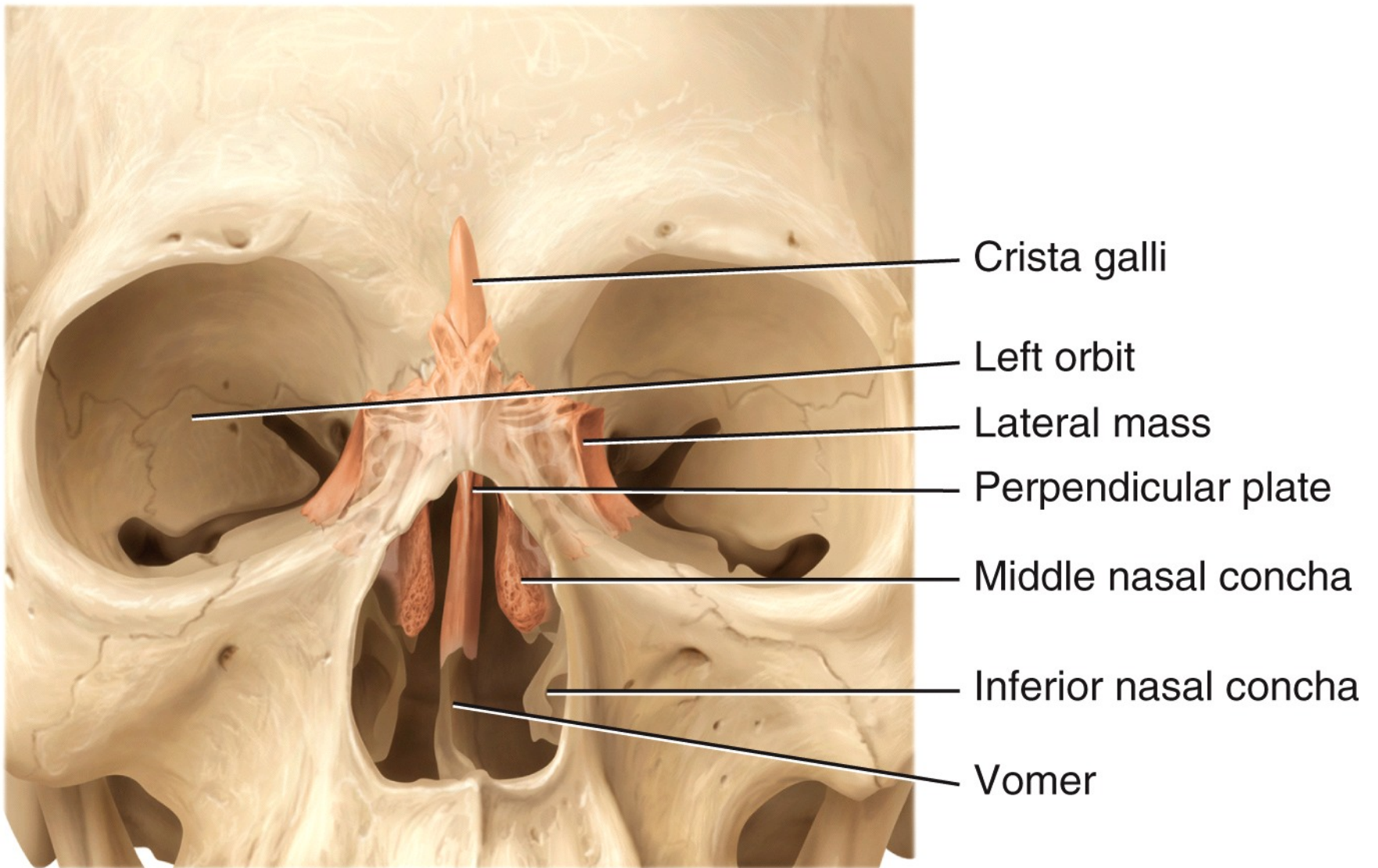


ANTERIOR

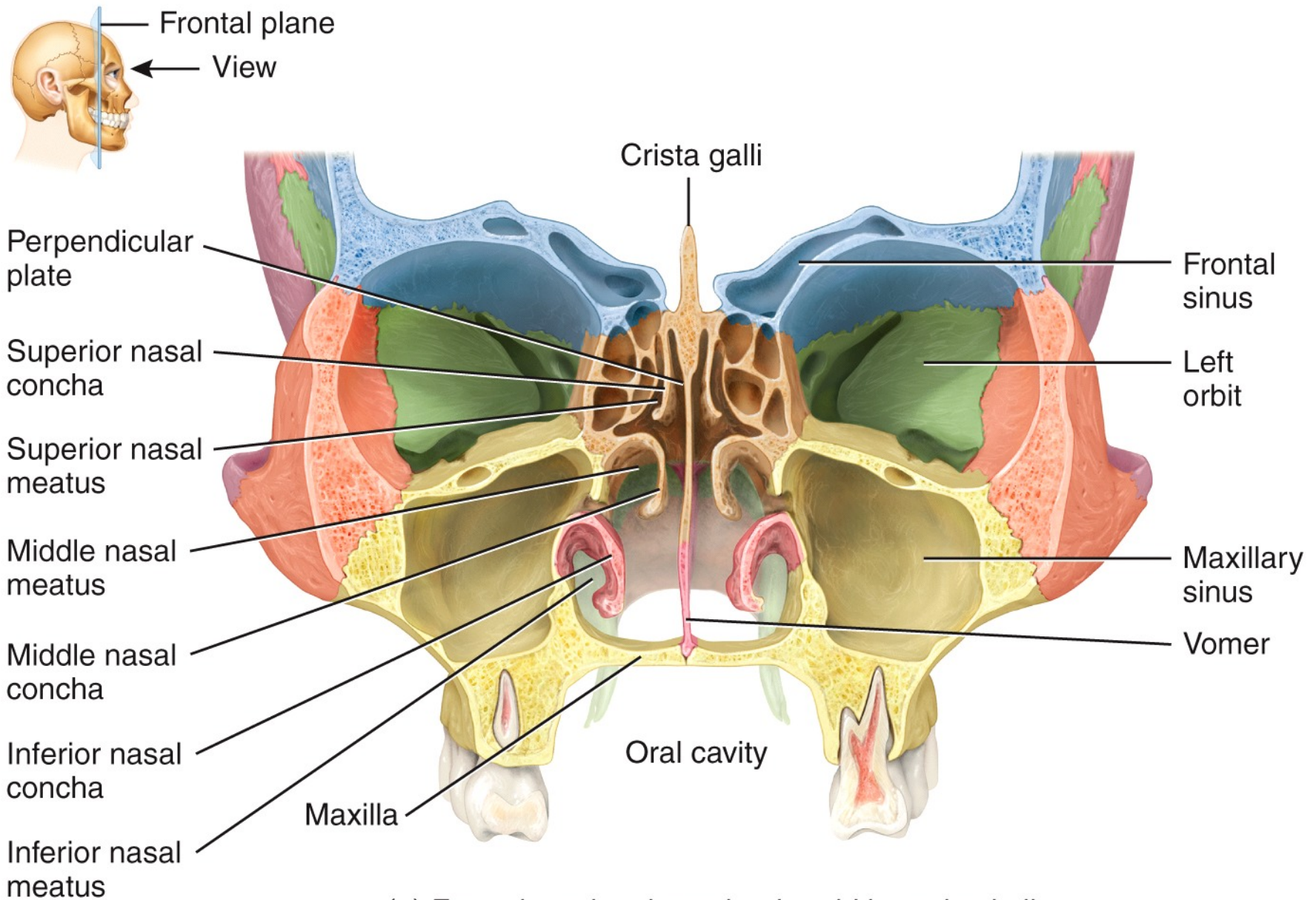
(b) Superior view



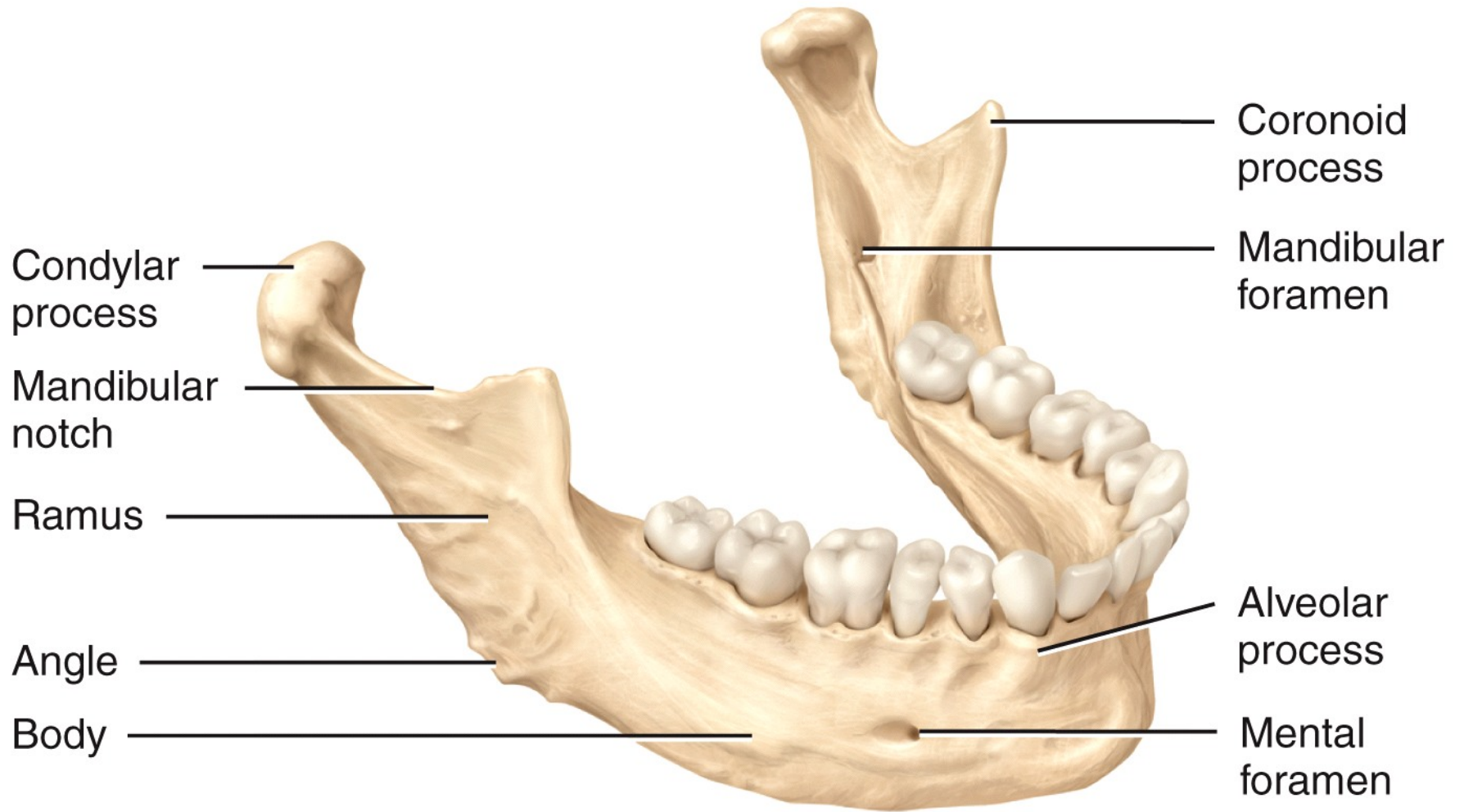
(c) Anterior view



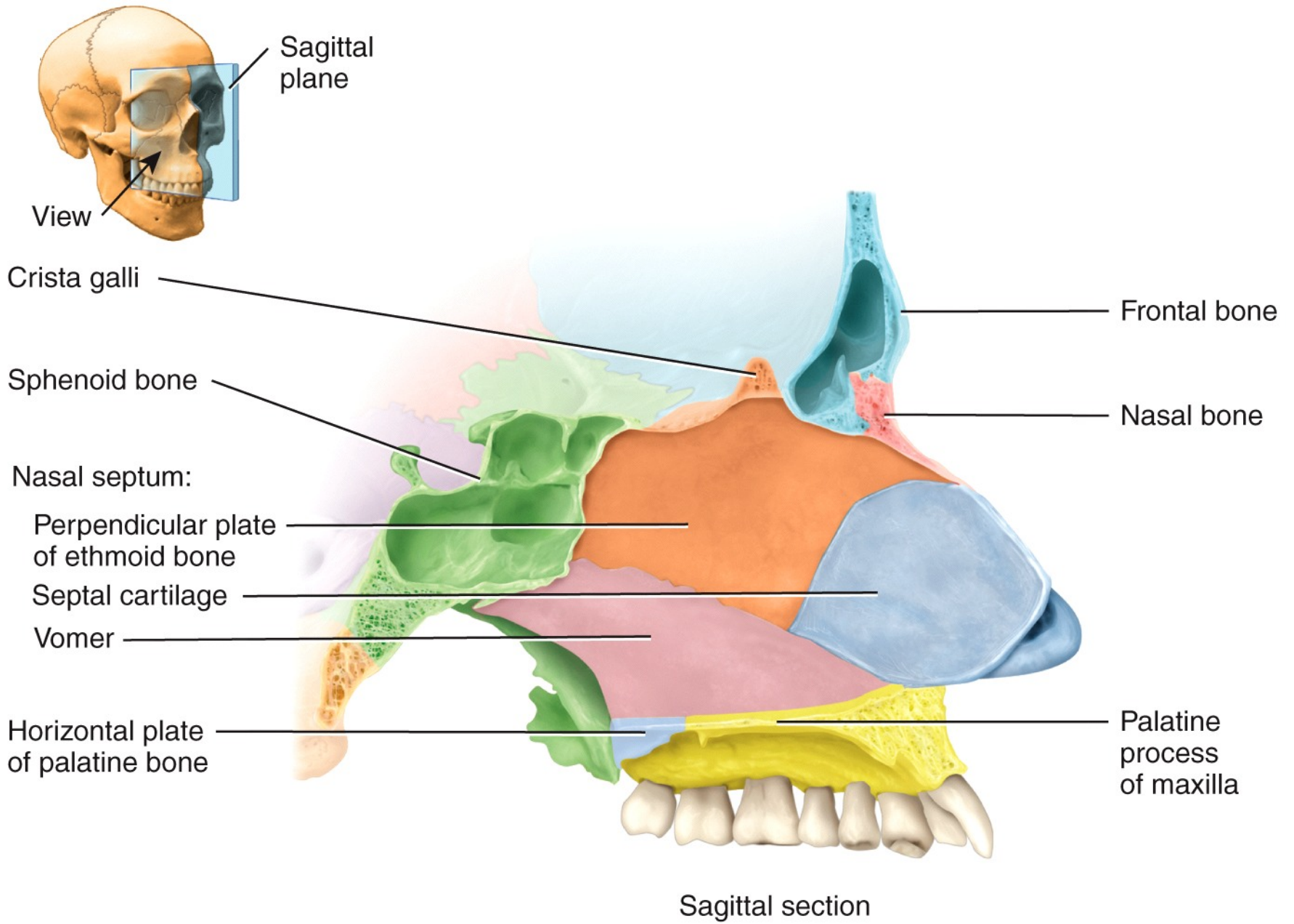
(d) Anterior view of position of ethmoid bone in skull
(projected to the surface)

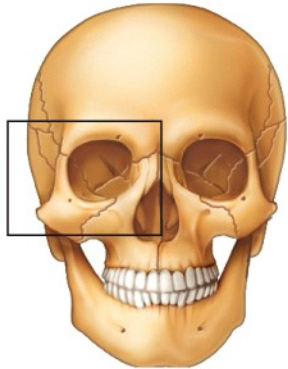
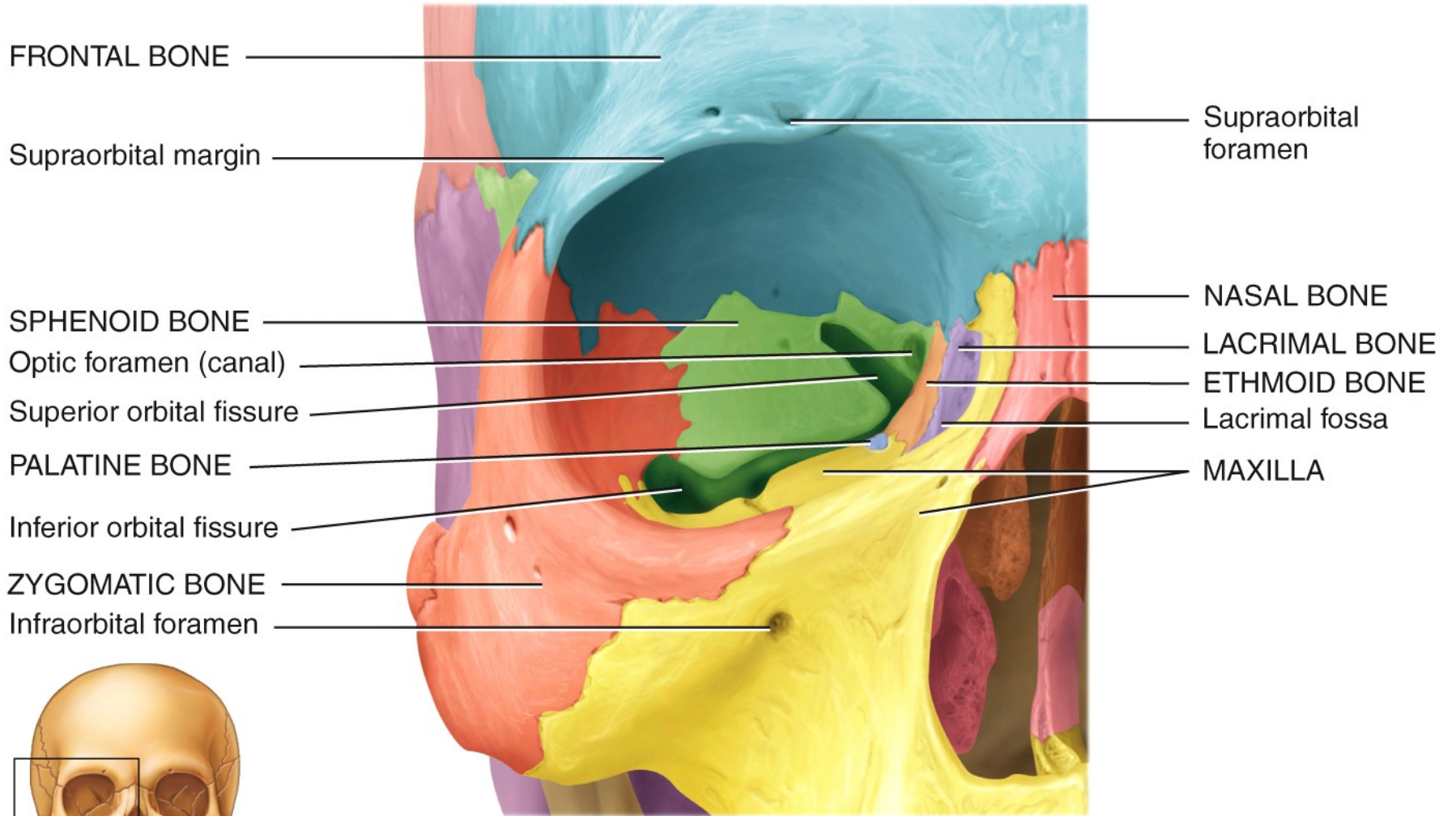


(e) Frontal section through ethmoid bone in skull

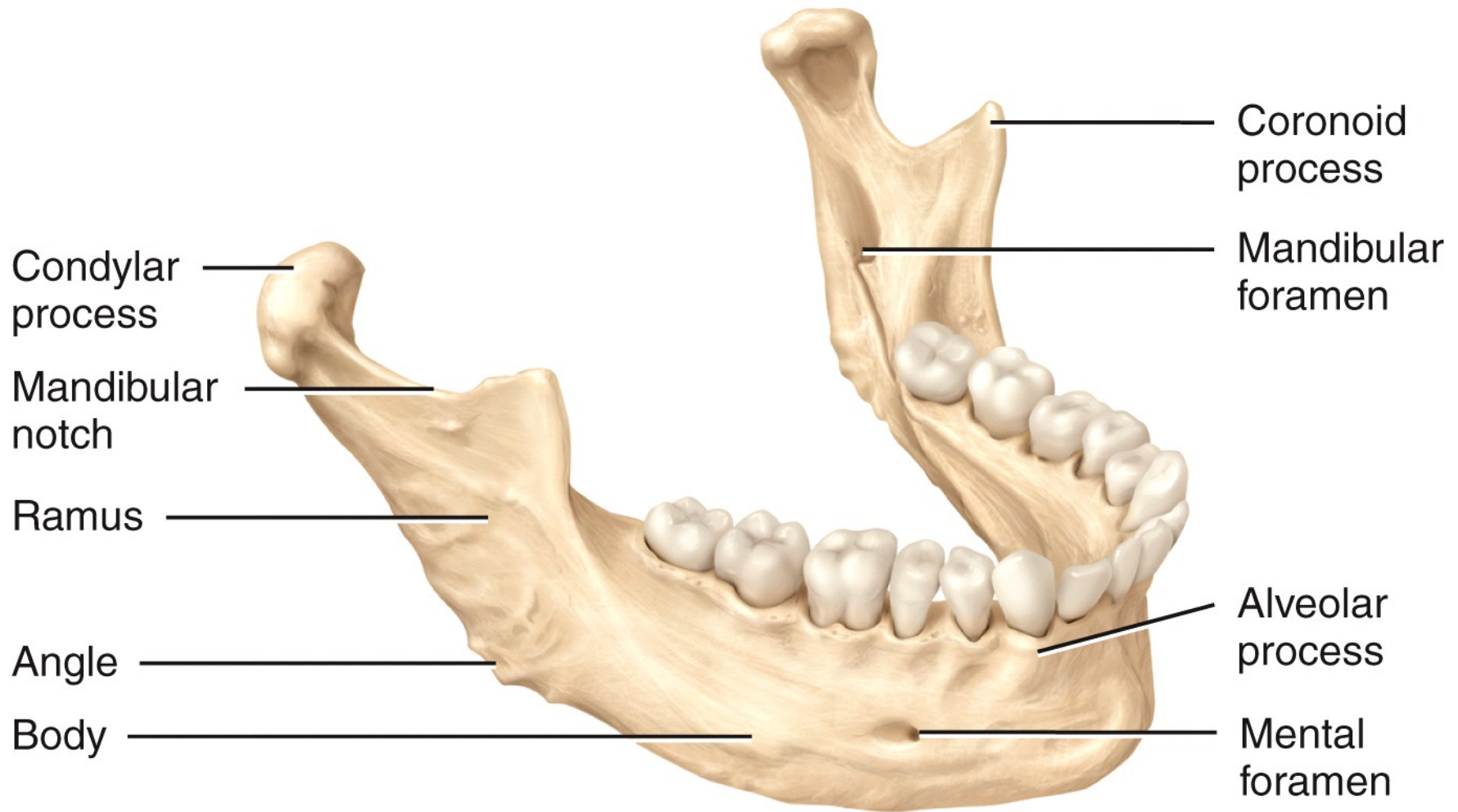


Right lateral view

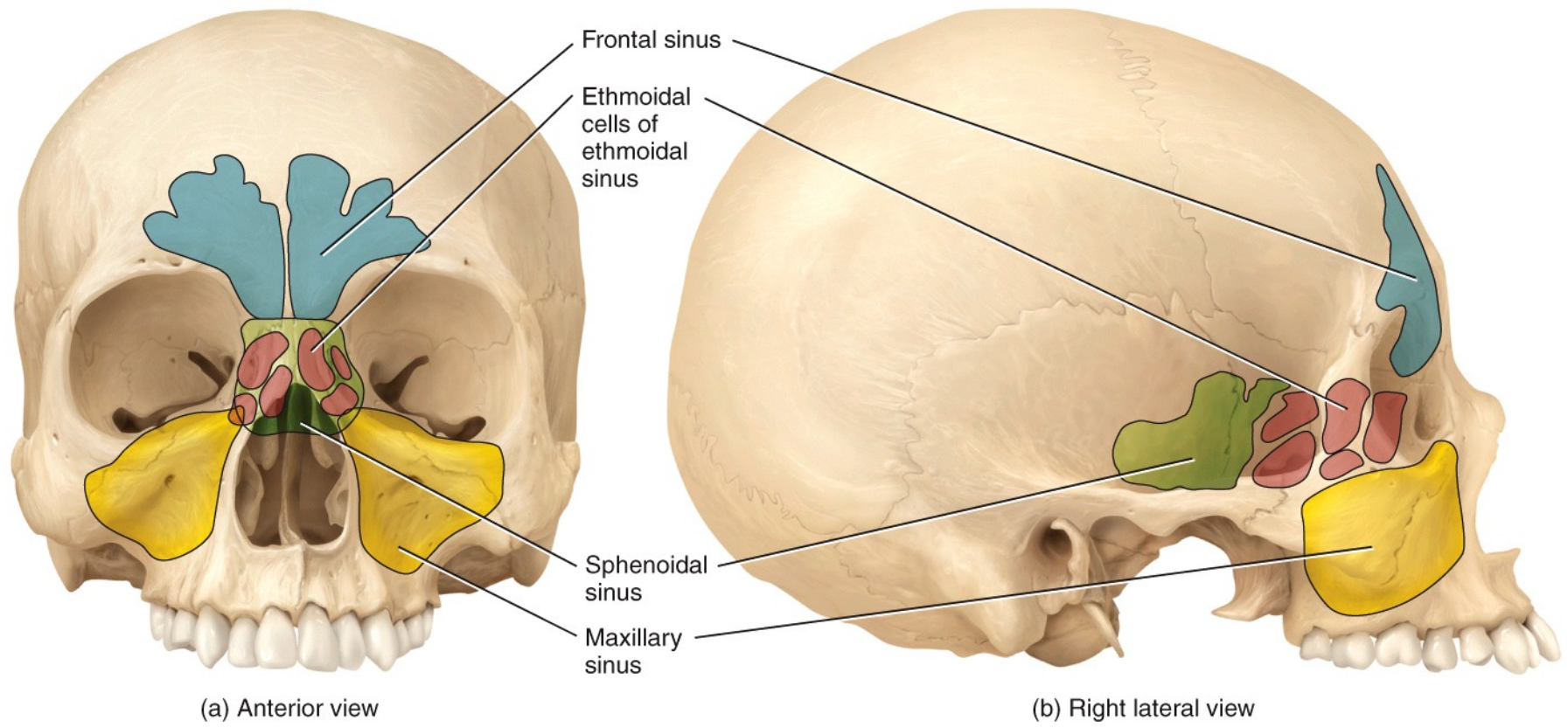


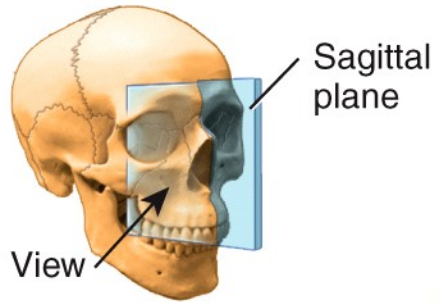


Anterior view showing the bones of the right orbit



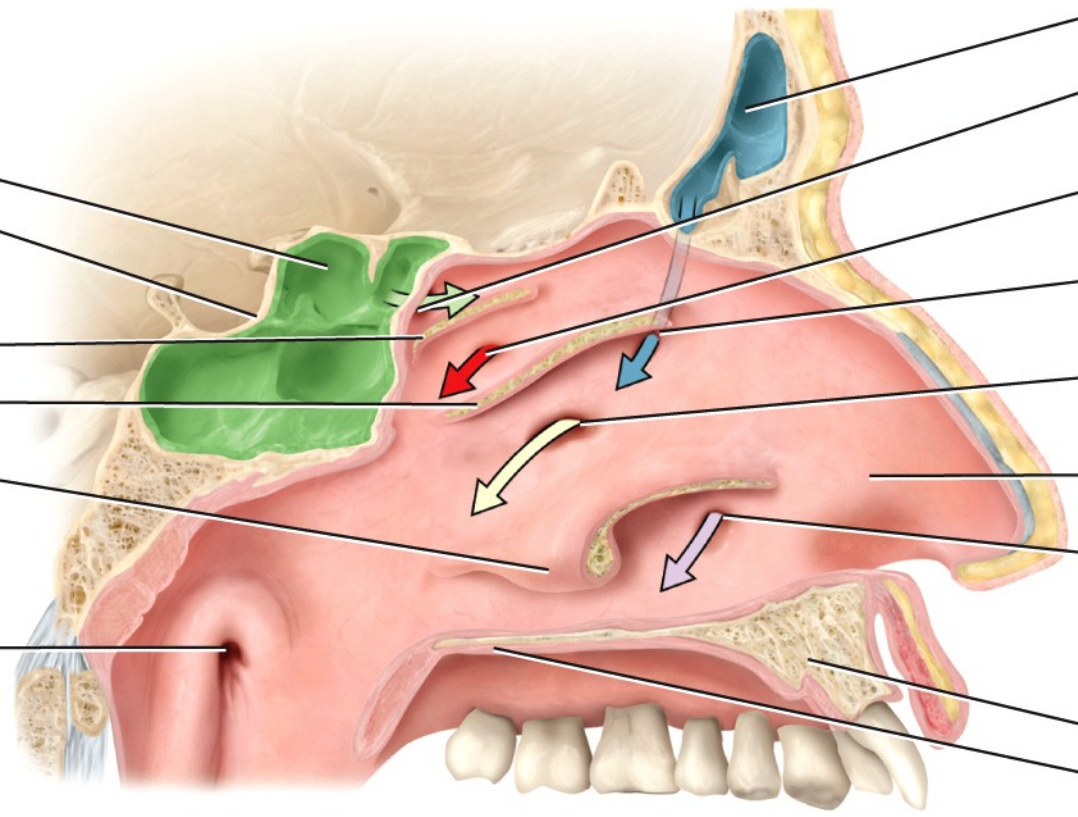
Right lateral view





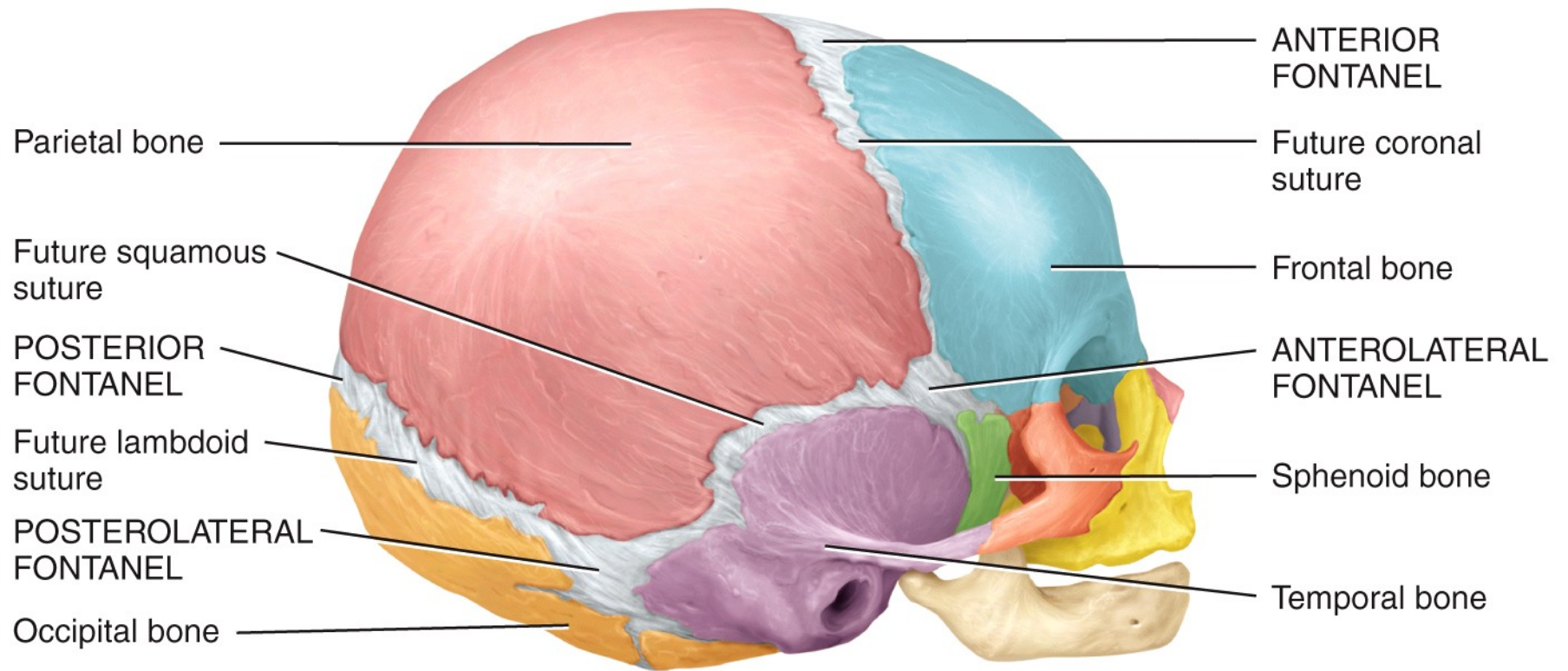
Sphenoidal sinus
 Hypophyseal fossa
 Nasal conchae (cut):
 Superior
 Middle
 Inferior

Orifice of auditory (eustachian) tube

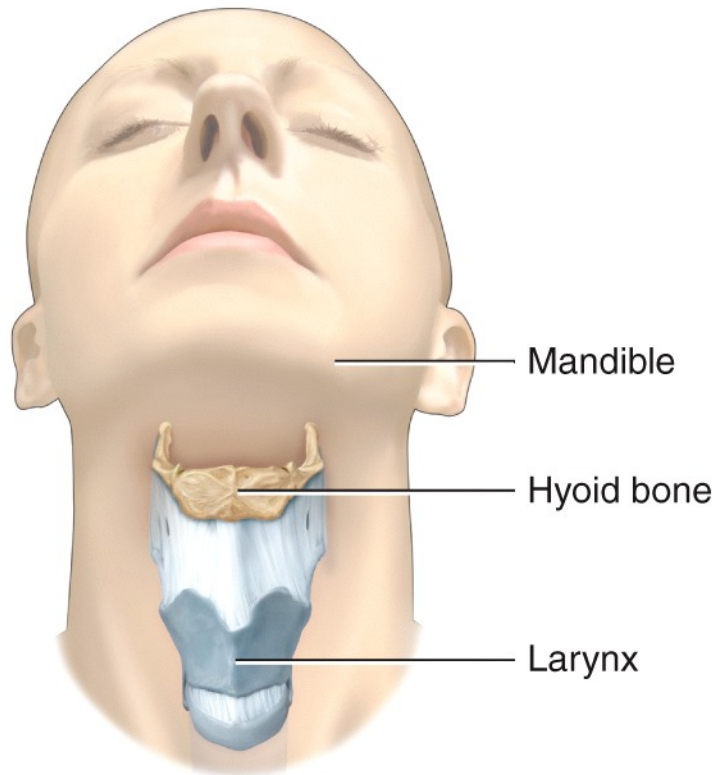


Frontal sinus
 Opening of sphenoidal sinus
 Opening of posterior ethmoidal cells
 Opening of frontal sinus
 Opening of maxillary sinus
 Nasal cavity
 Opening of nasolacrimal duct
 Hard palate:
 Maxilla
 Palatine bone

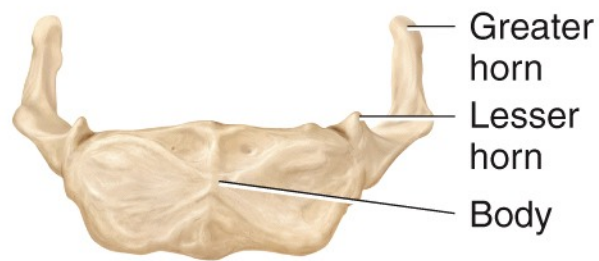
(c) Sagittal section



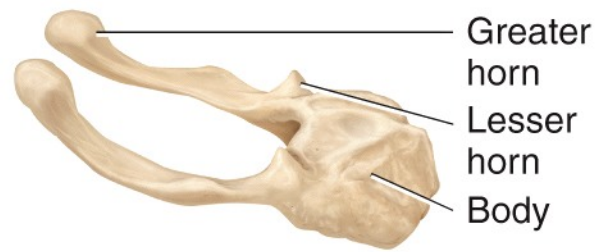
Right lateral view



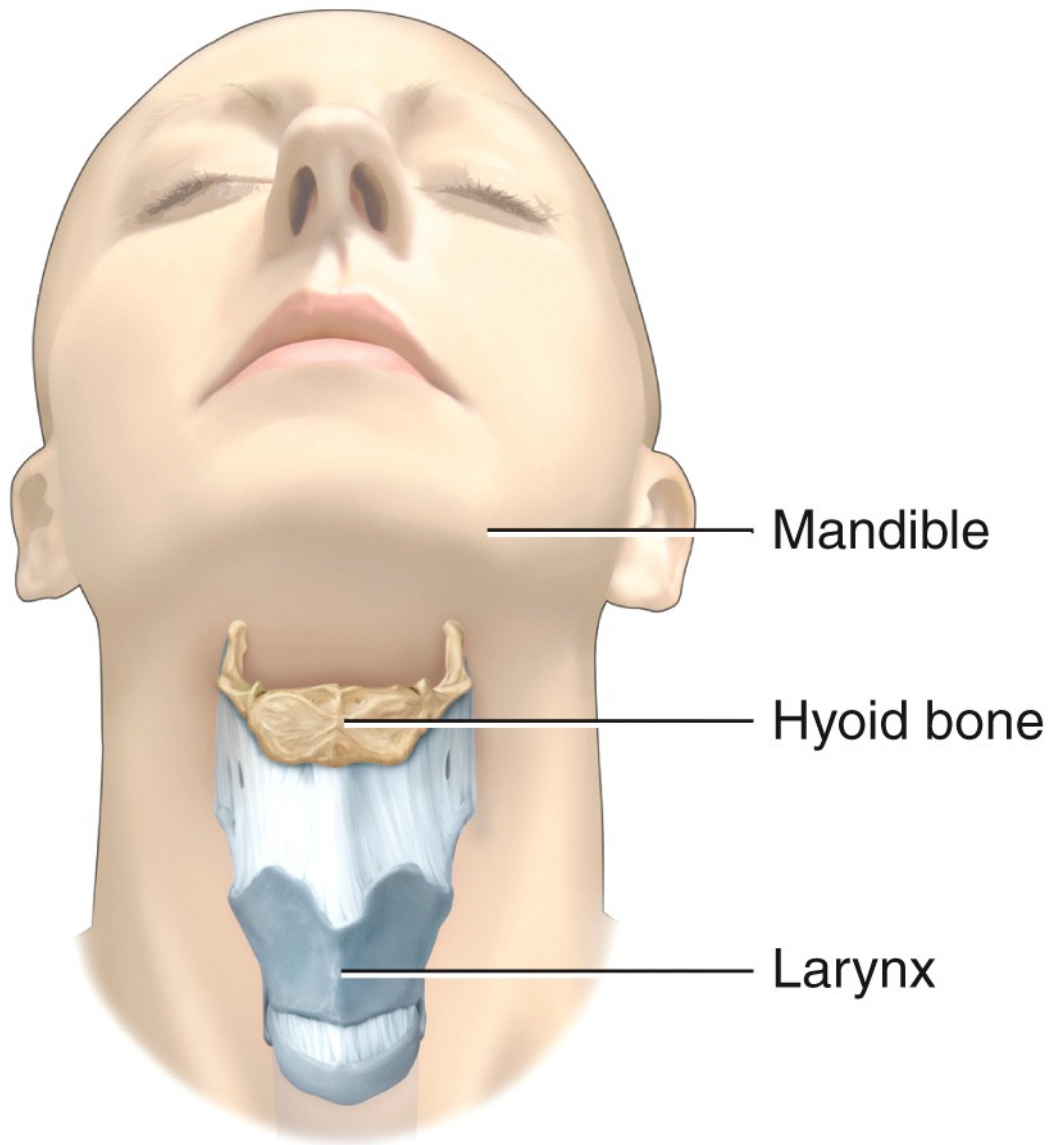
(a) Position of hyoid bone



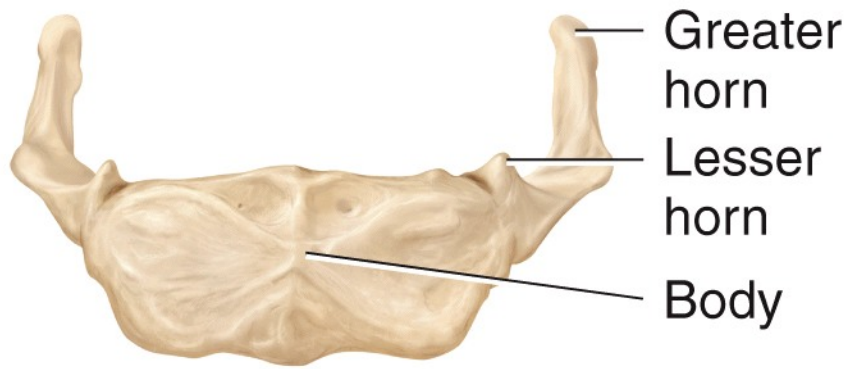
(b) Anterior view



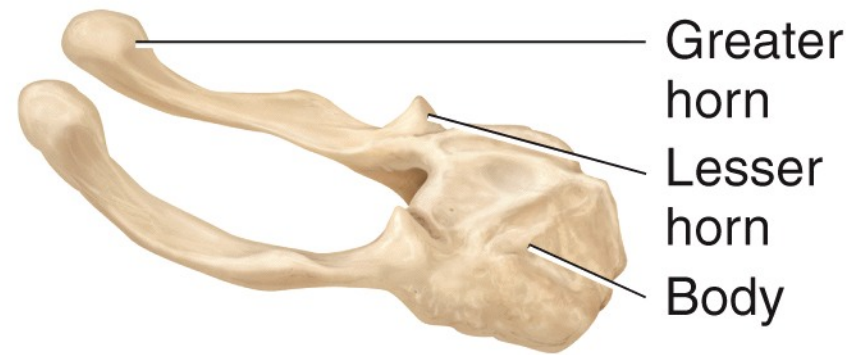
(c) Right lateral view



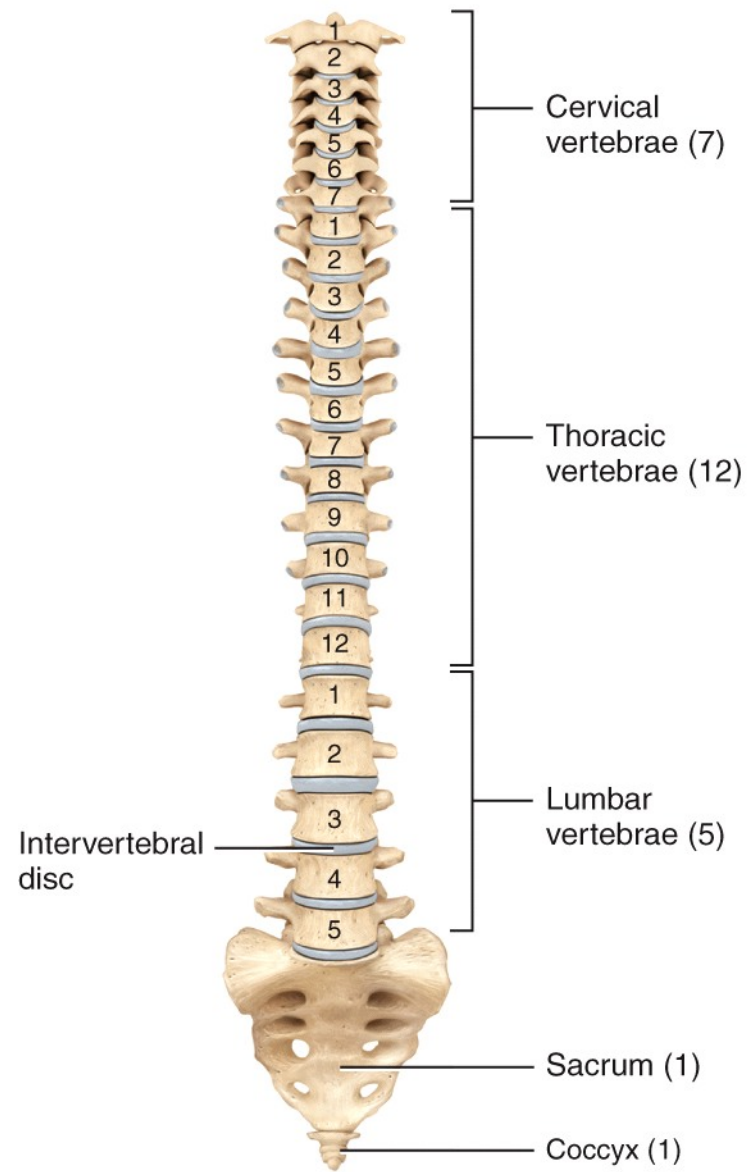
(a) Position of hyoid bone



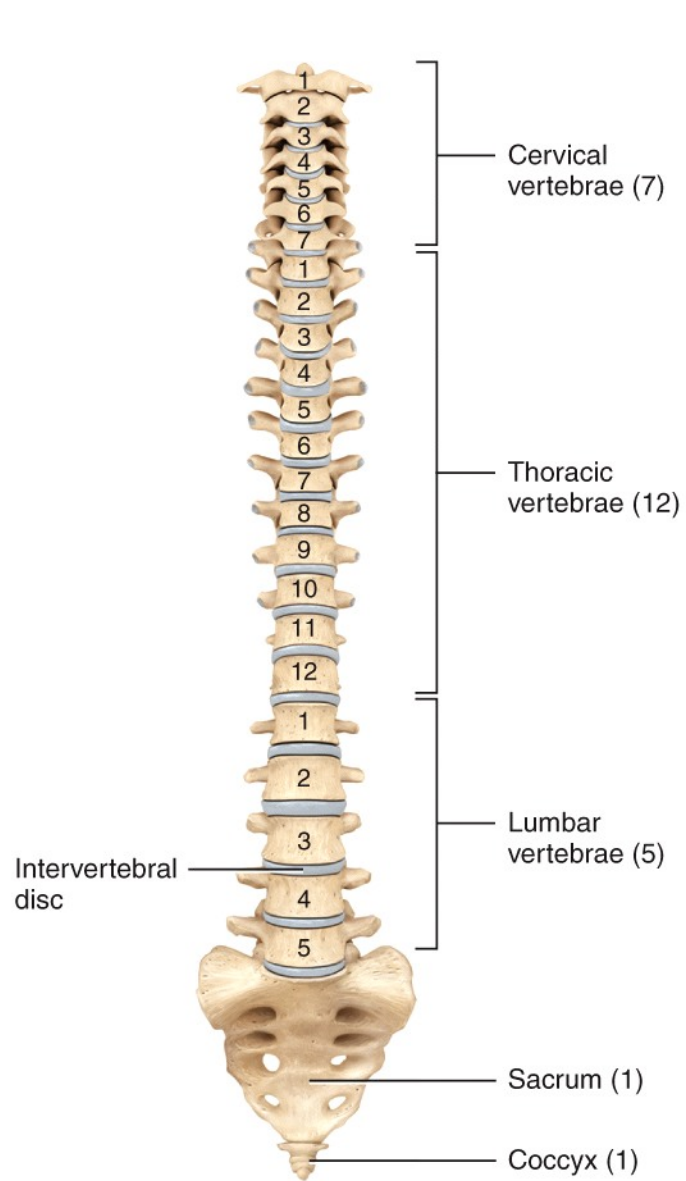
(b) Anterior view



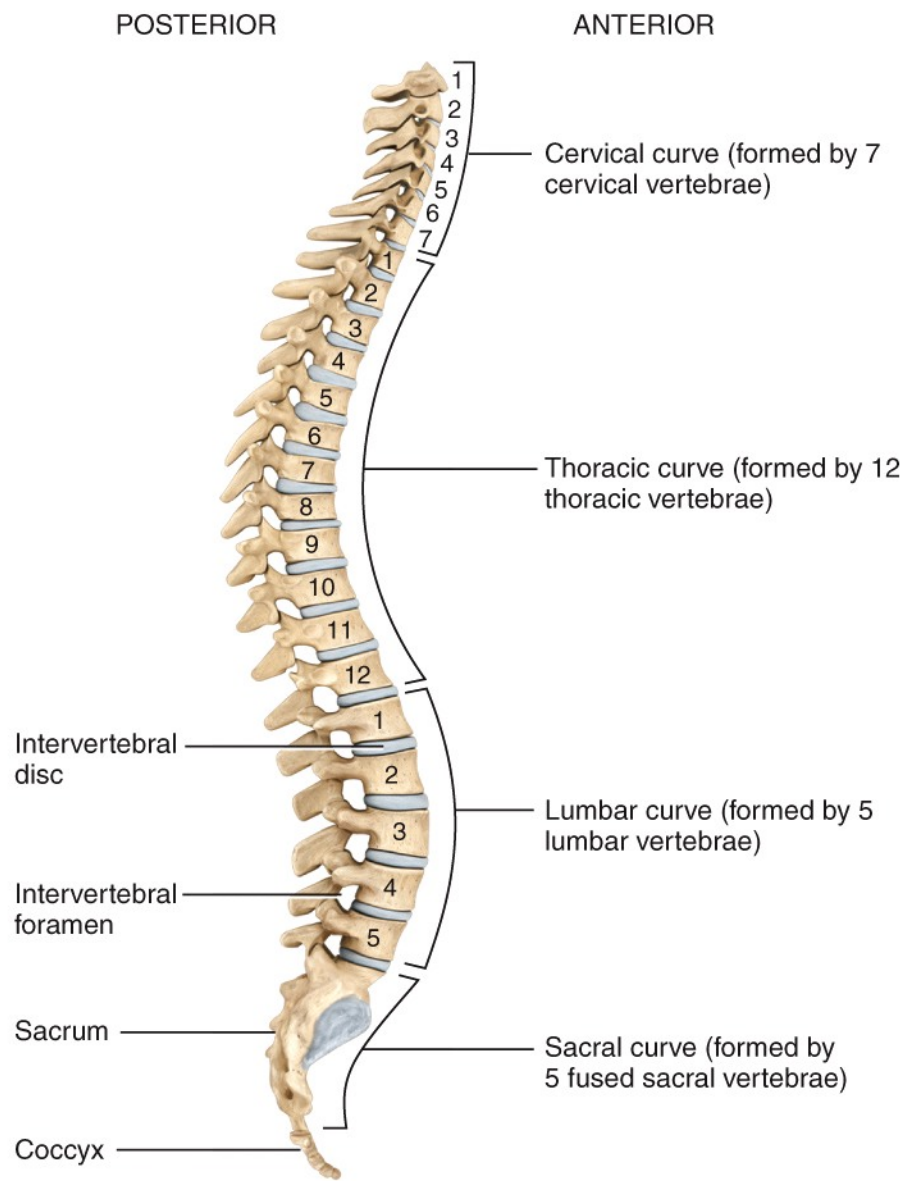
(c) Right lateral view



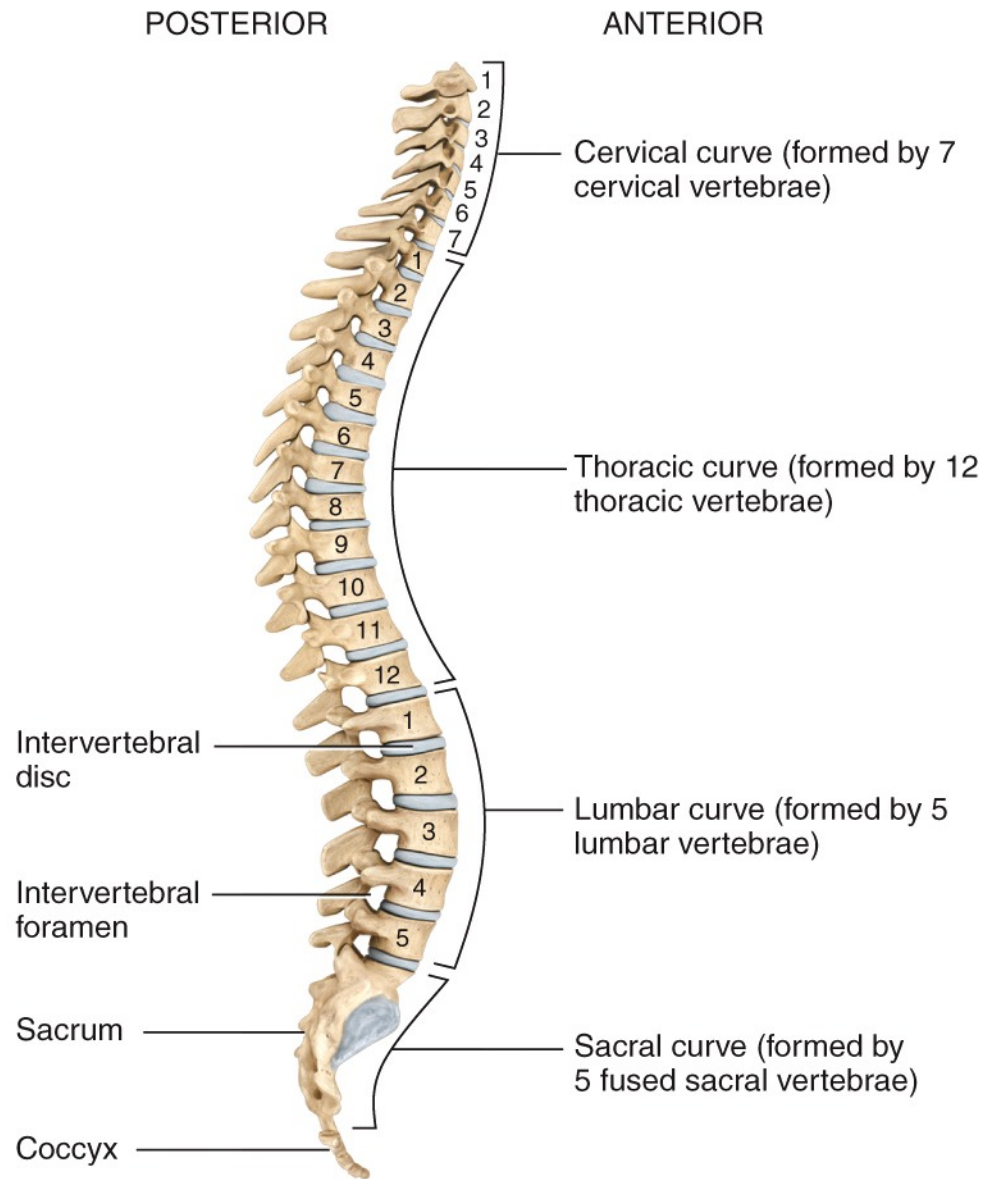
(a) Anterior view showing regions of the vertebral column



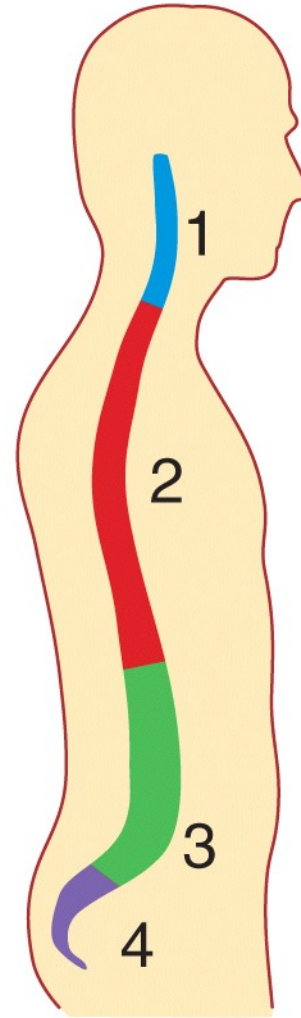
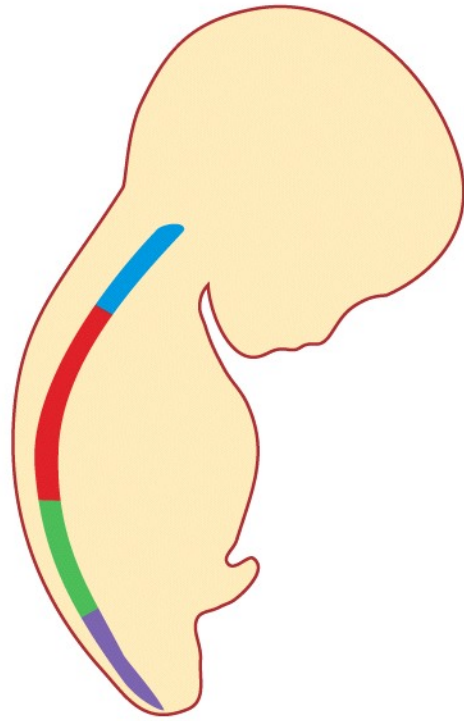
(a) Anterior view showing regions of the vertebral column



(b) Right lateral view showing four normal curves

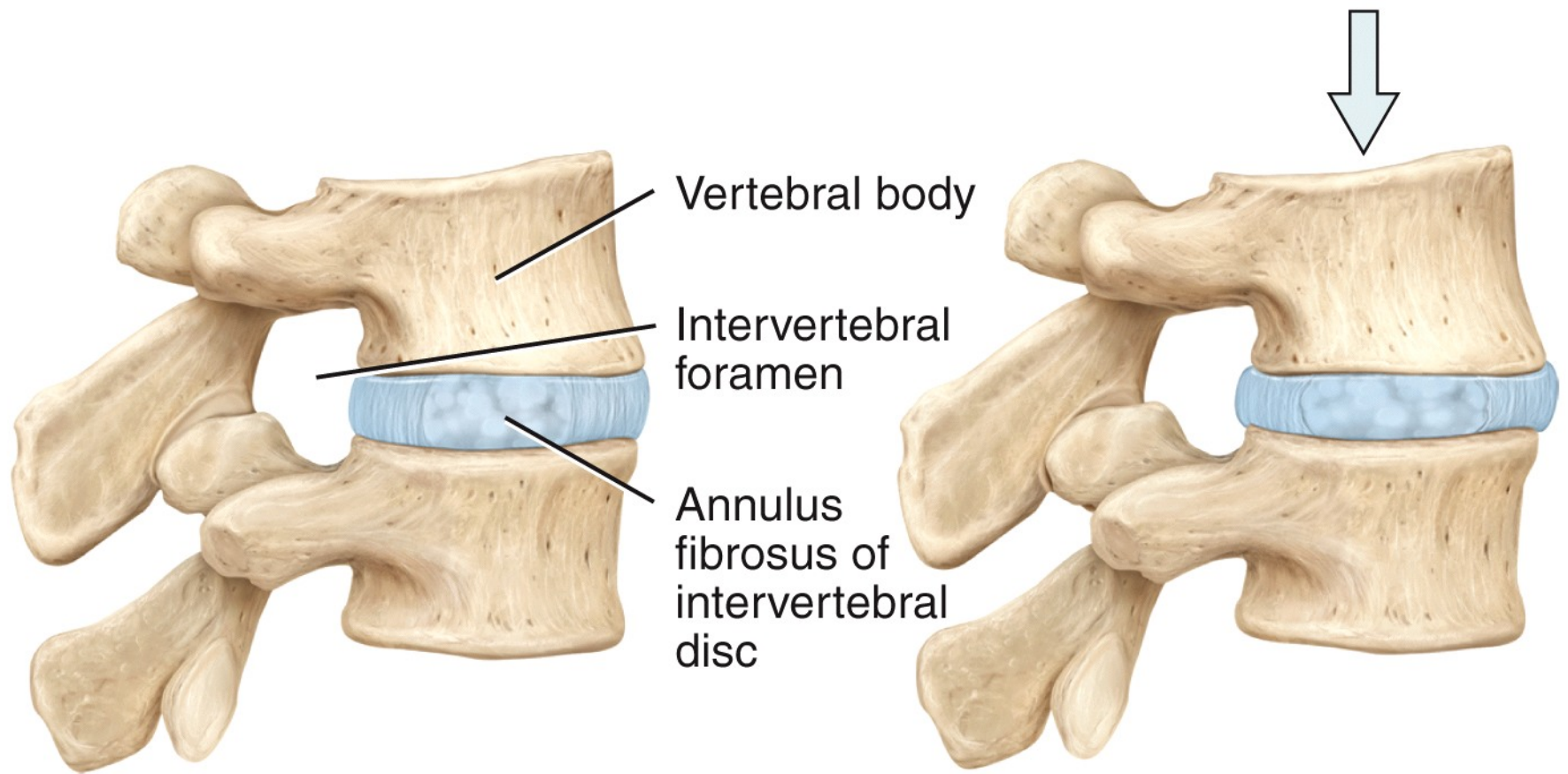


(b) Right lateral view showing four normal curves



Single curve in fetus Four curves in adult

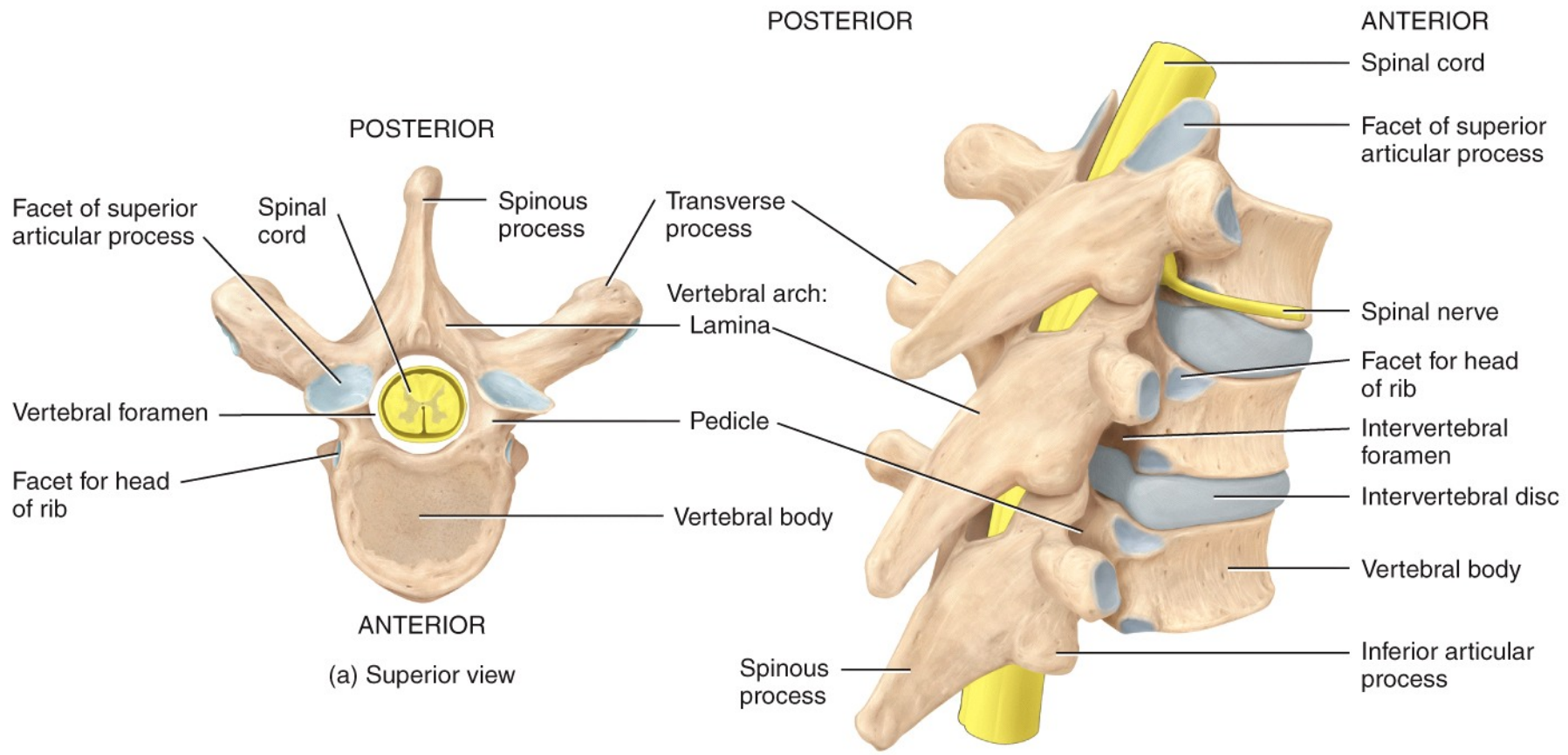
(c) Fetal and adult curves



Normal intervertebral disc

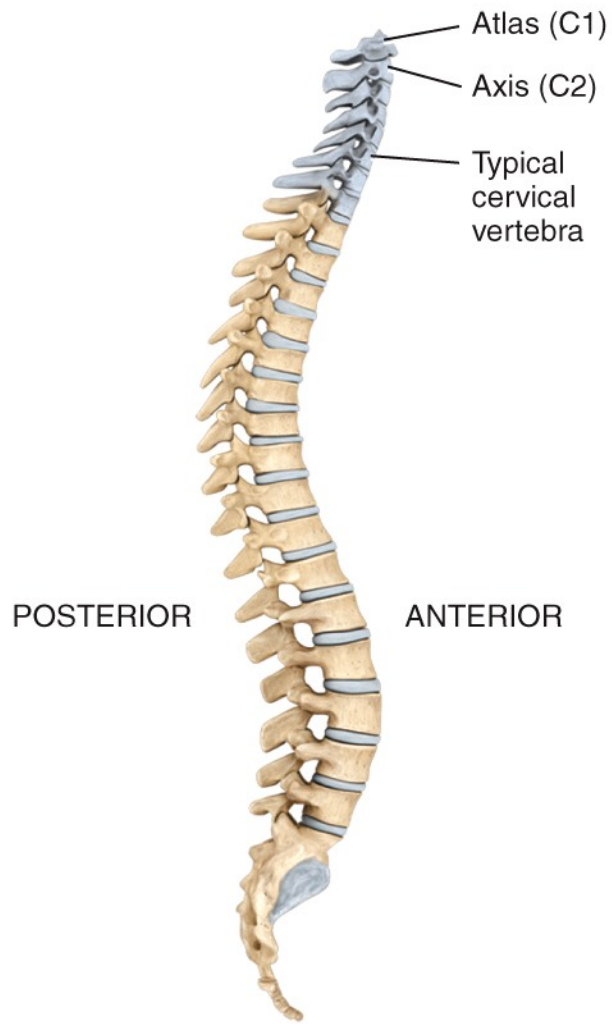
Compressed intervertebral disc
in a weight-bearing situation

(d) Intervertebral disc

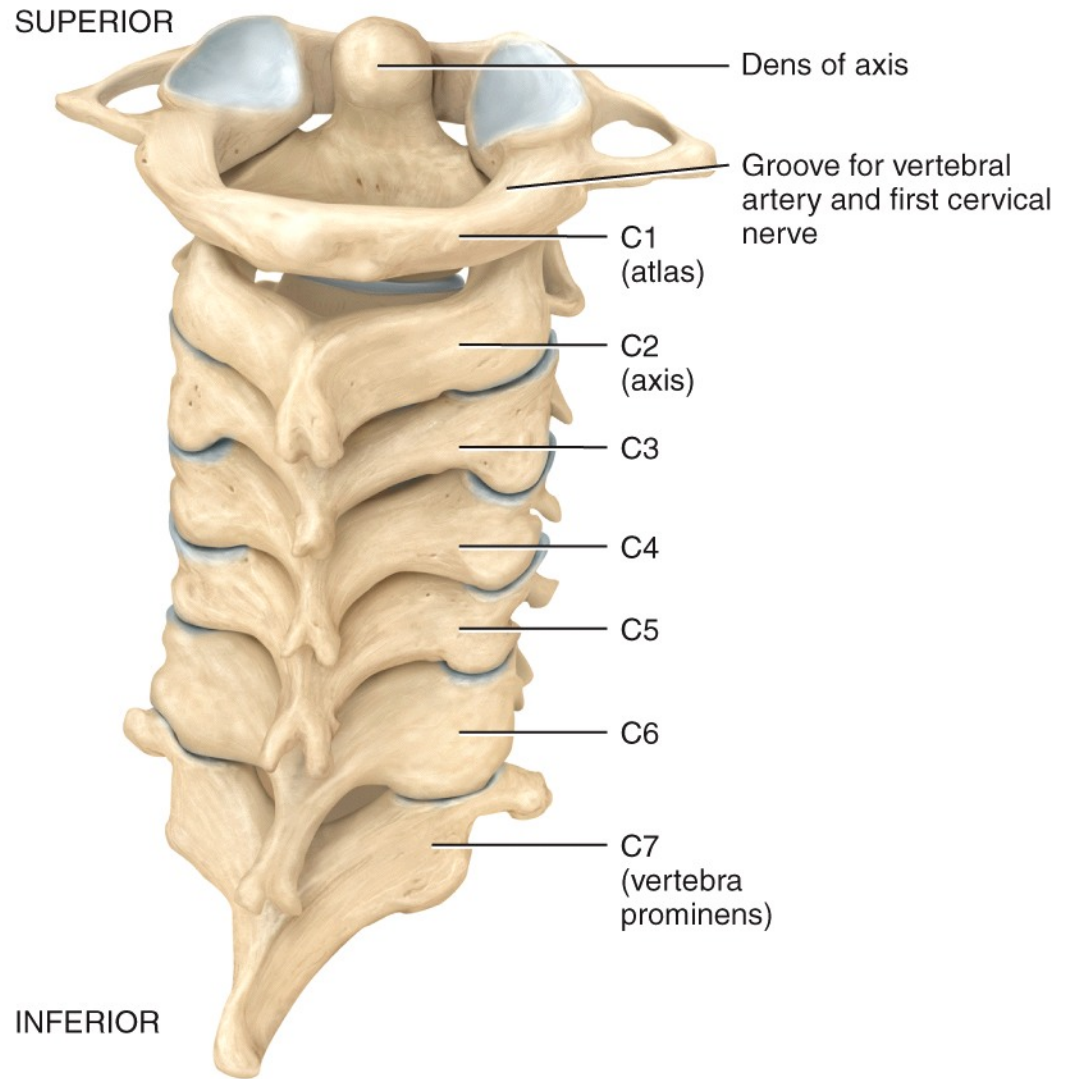


(a) Superior view

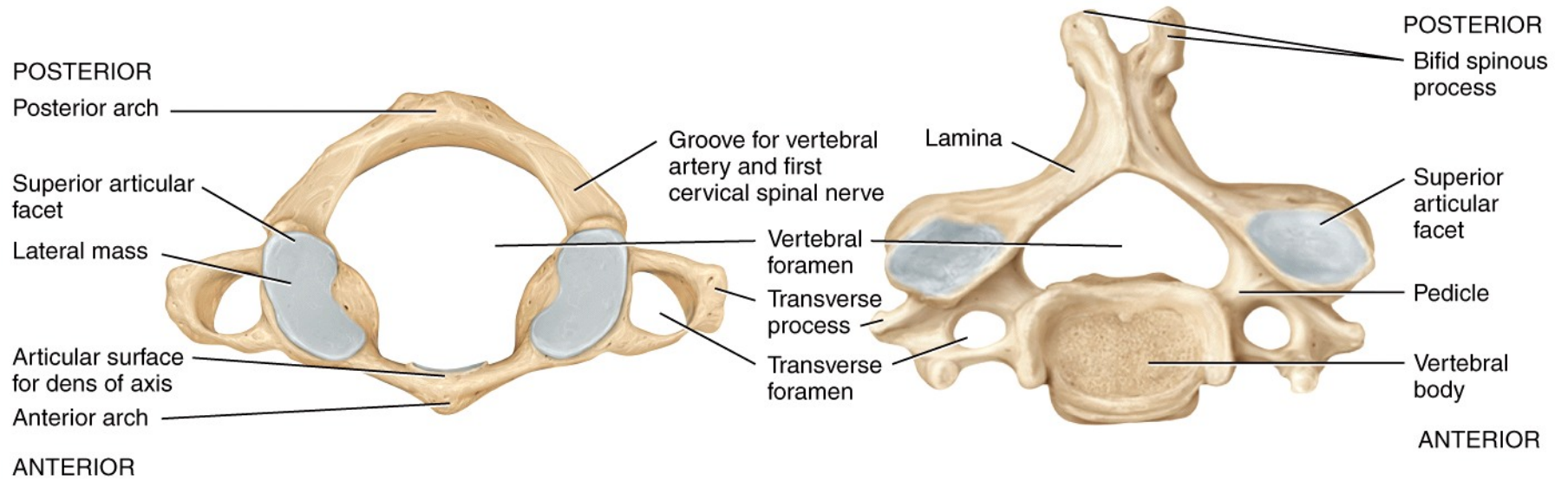
(b) Right posterolateral view of articulated vertebrae



Location of cervical vertebrae

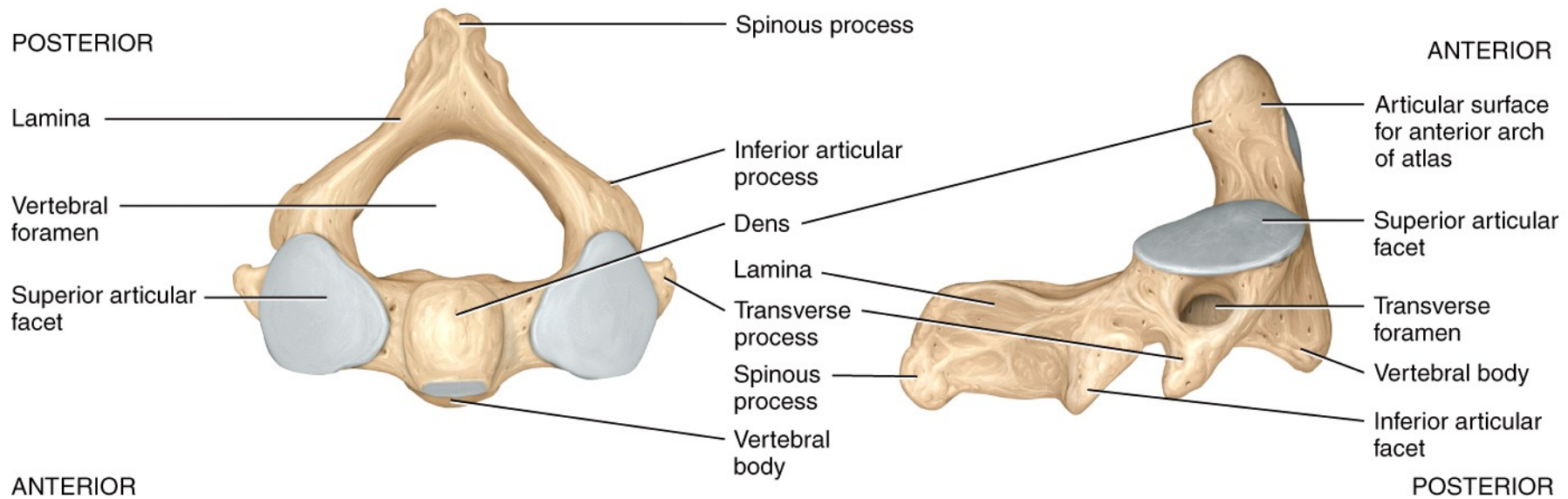


(a) Posterior view of articulated cervical vertebrae



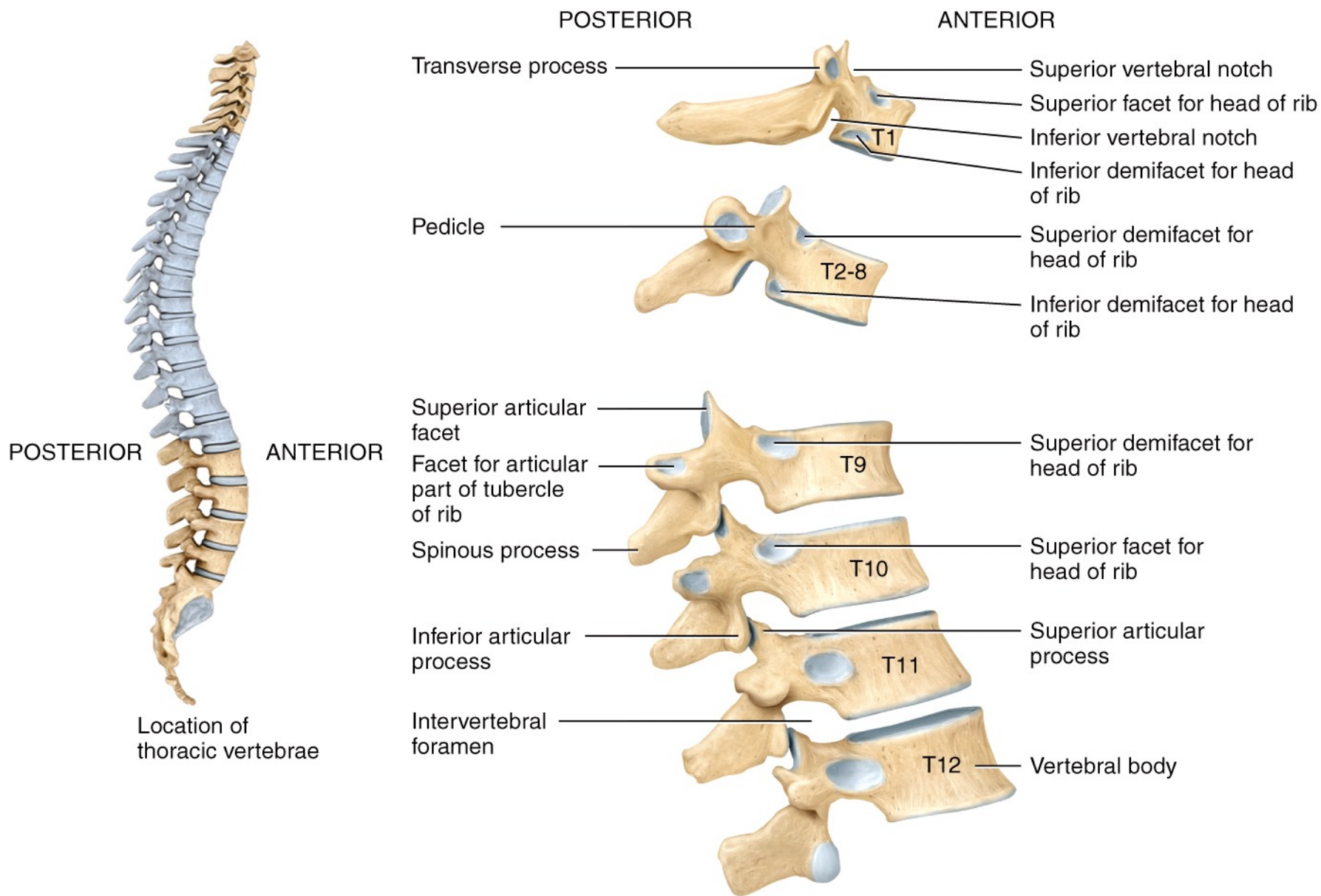
(b) Superior view of atlas (C1)

(c) Superior view of a typical cervical vertebra

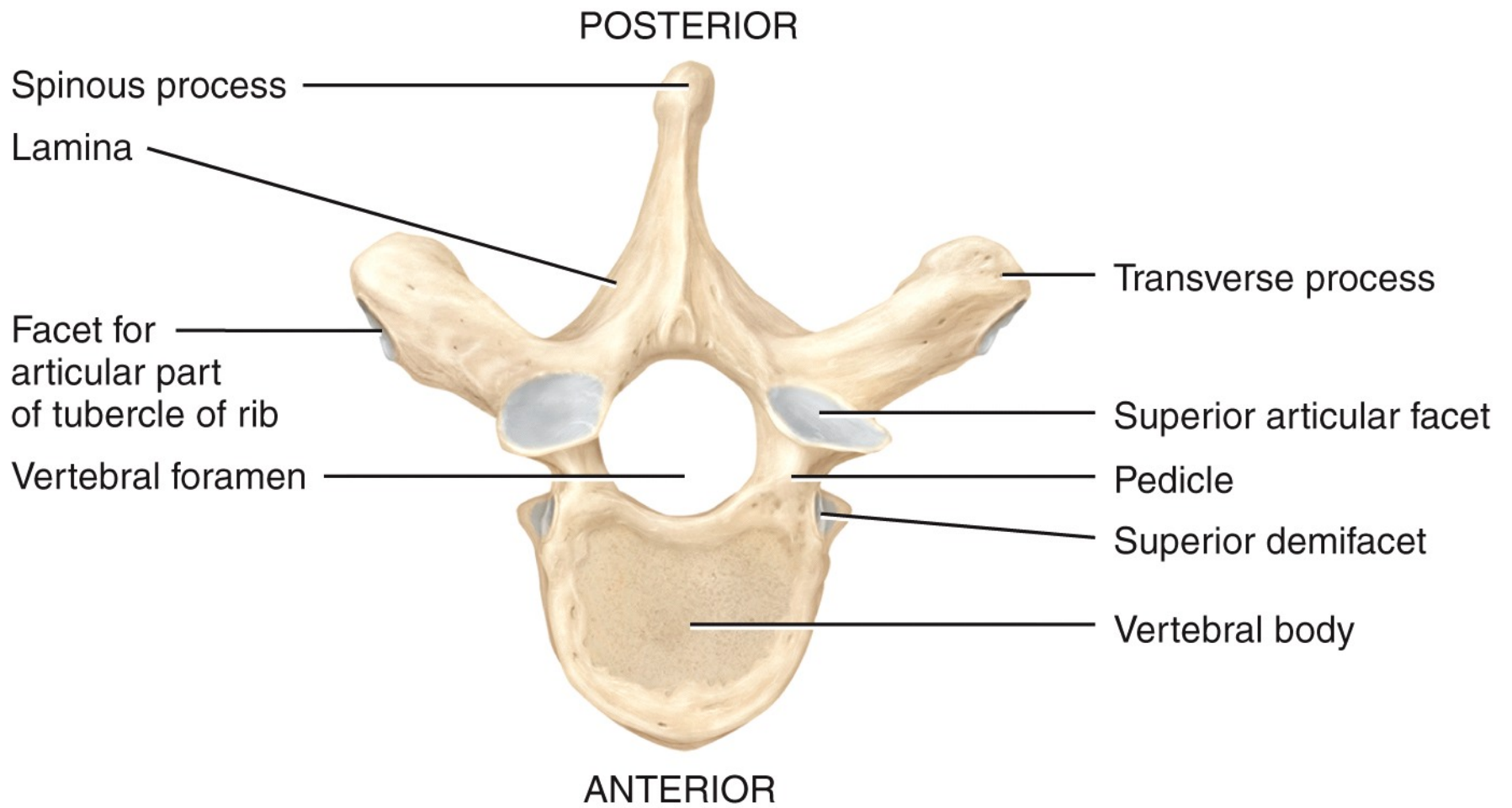


(d) Superior view of axis (C2)

(e) Right lateral view of axis (C2)



(a) Right lateral view of several articulated thoracic vertebrae



(b) Superior view

POSTERIOR

ANTERIOR

Superior articular facet

Transverse process

Facet for articular part of tubercle of rib

Pedicle

Inferior articular facet

Spinous process

Superior vertebral notch

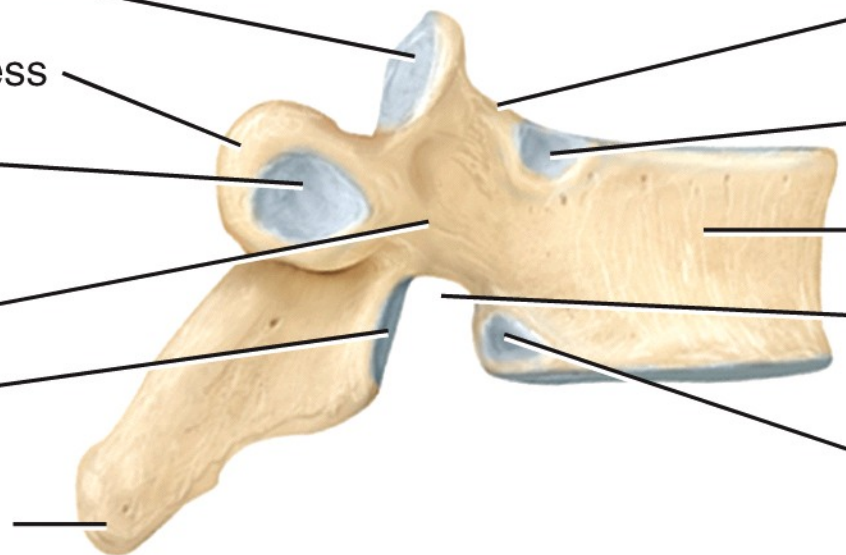
Superior demifacet

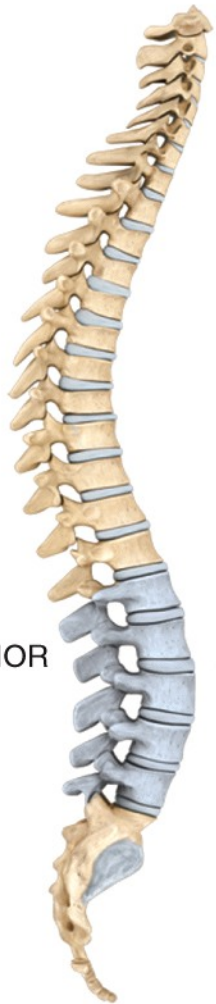Vertebral body

Inferior vertebral notch

Inferior demifacet

(c) Right lateral view

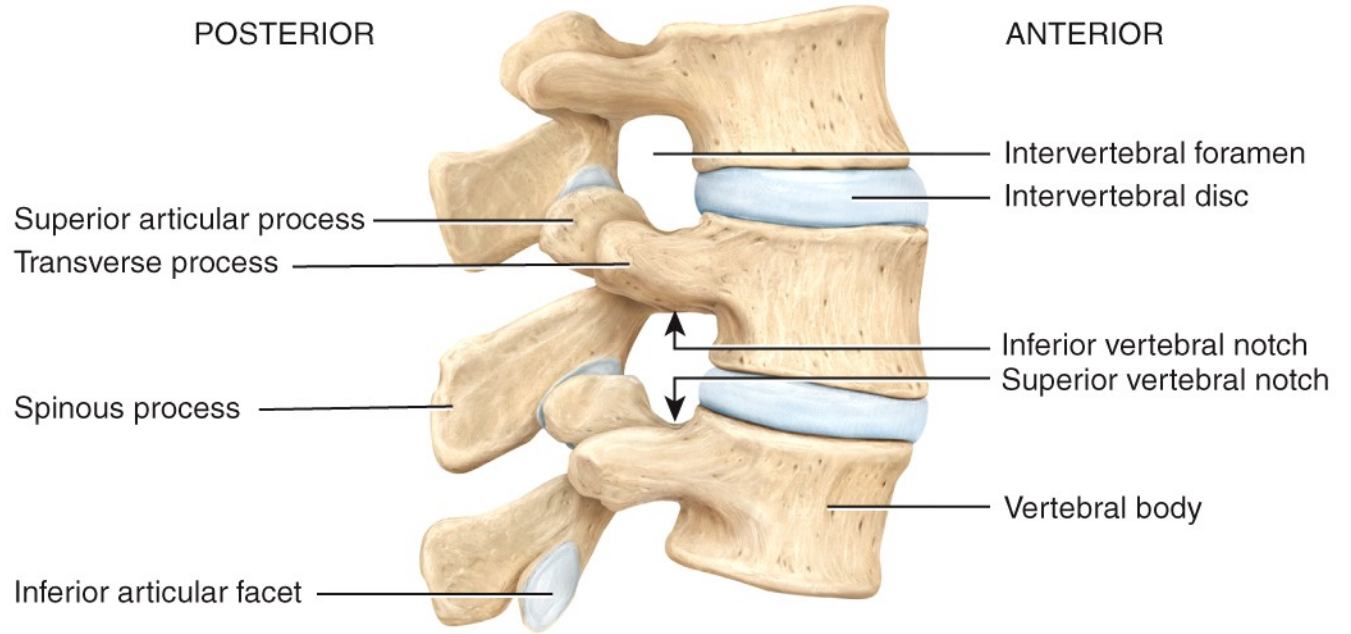




POSTERIOR

ANTERIOR

Location of lumbar vertebrae



POSTERIOR

ANTERIOR

Superior articular process

Transverse process

Spinous process

Inferior articular facet

Intervertebral foramen

Intervertebral disc

Inferior vertebral notch

Superior vertebral notch

Vertebral body

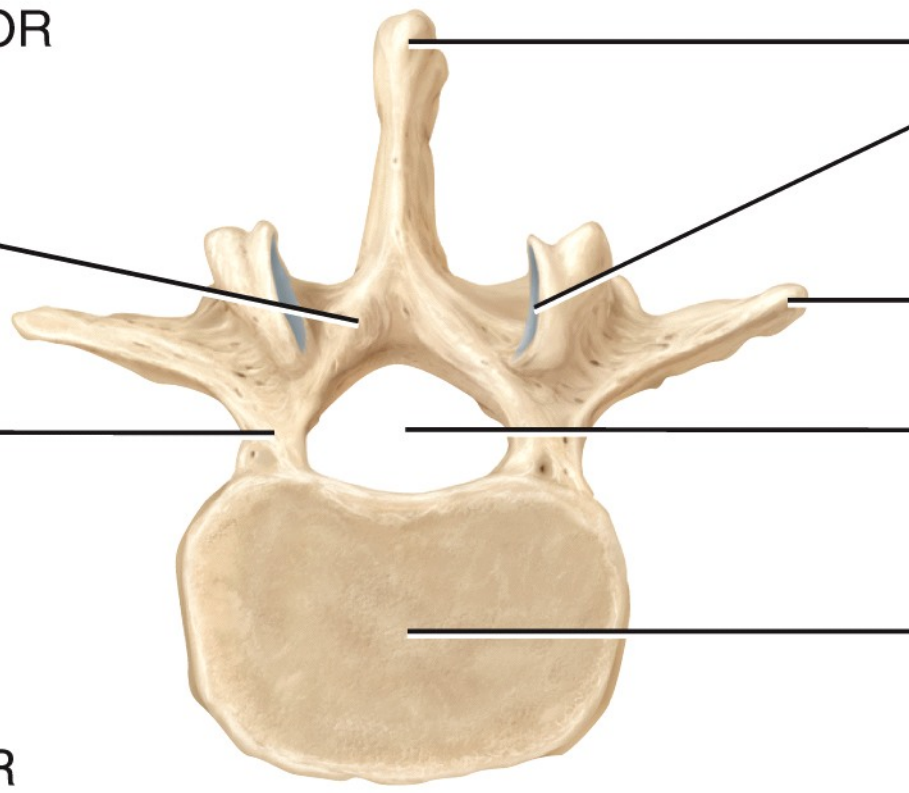
(a) Right lateral view of articulated lumbar vertebrae

POSTERIOR

Lamina

Pedicle

ANTERIOR



Spinous process

Superior articular process

Transverse process

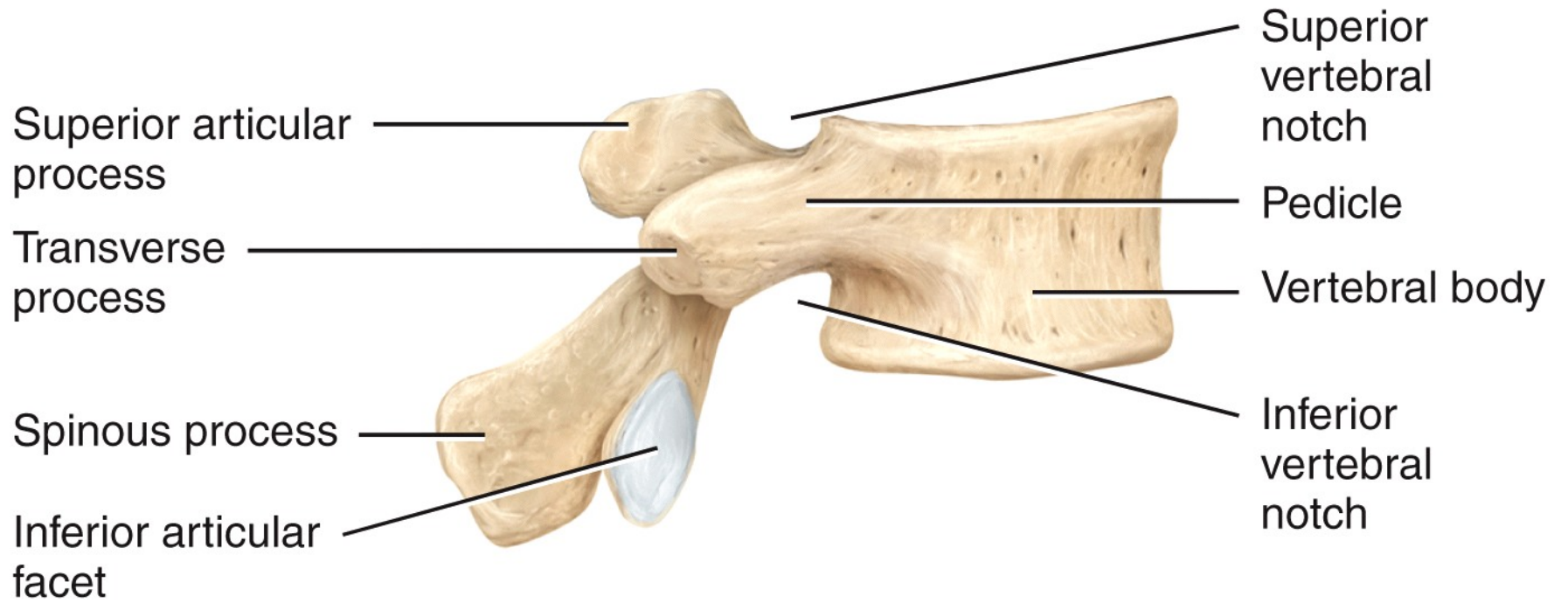
Vertebral foramen

Vertebral body

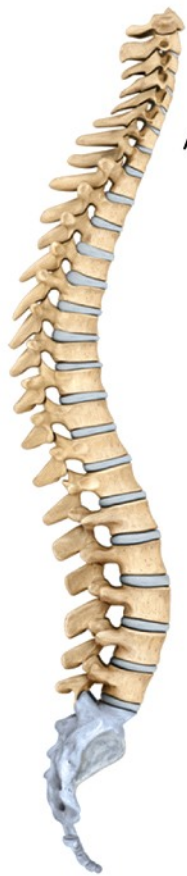(b) Superior view

POSTERIOR

ANTERIOR

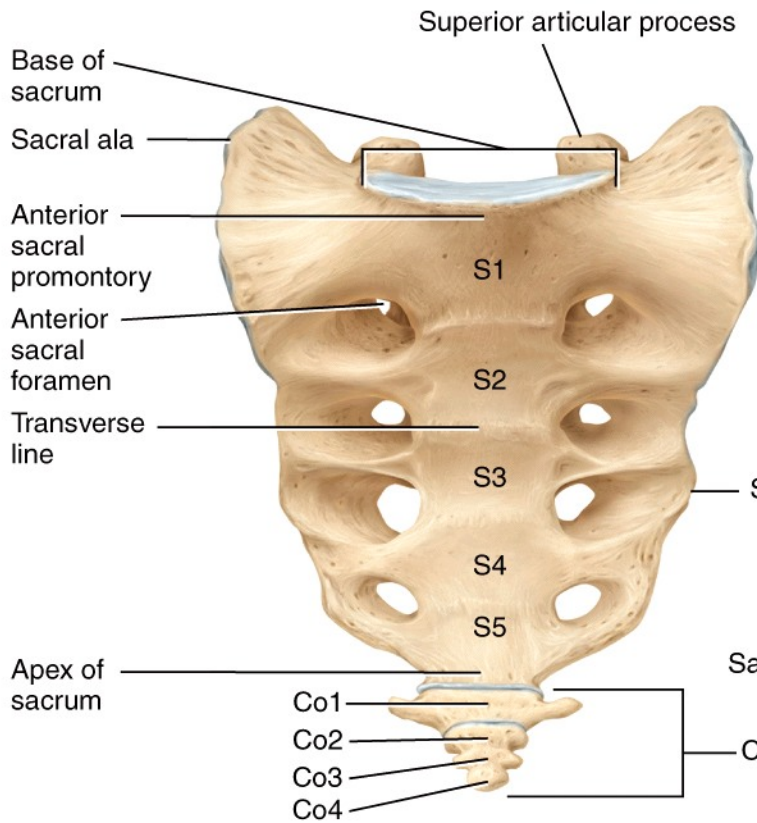


(c) Right lateral view

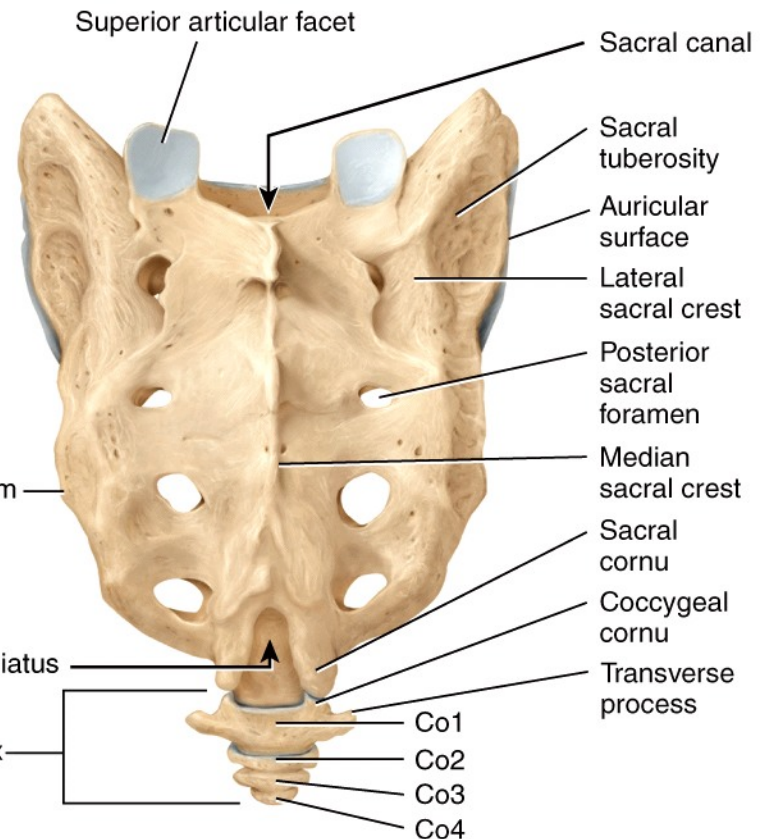


Location of sacrum and coccyx

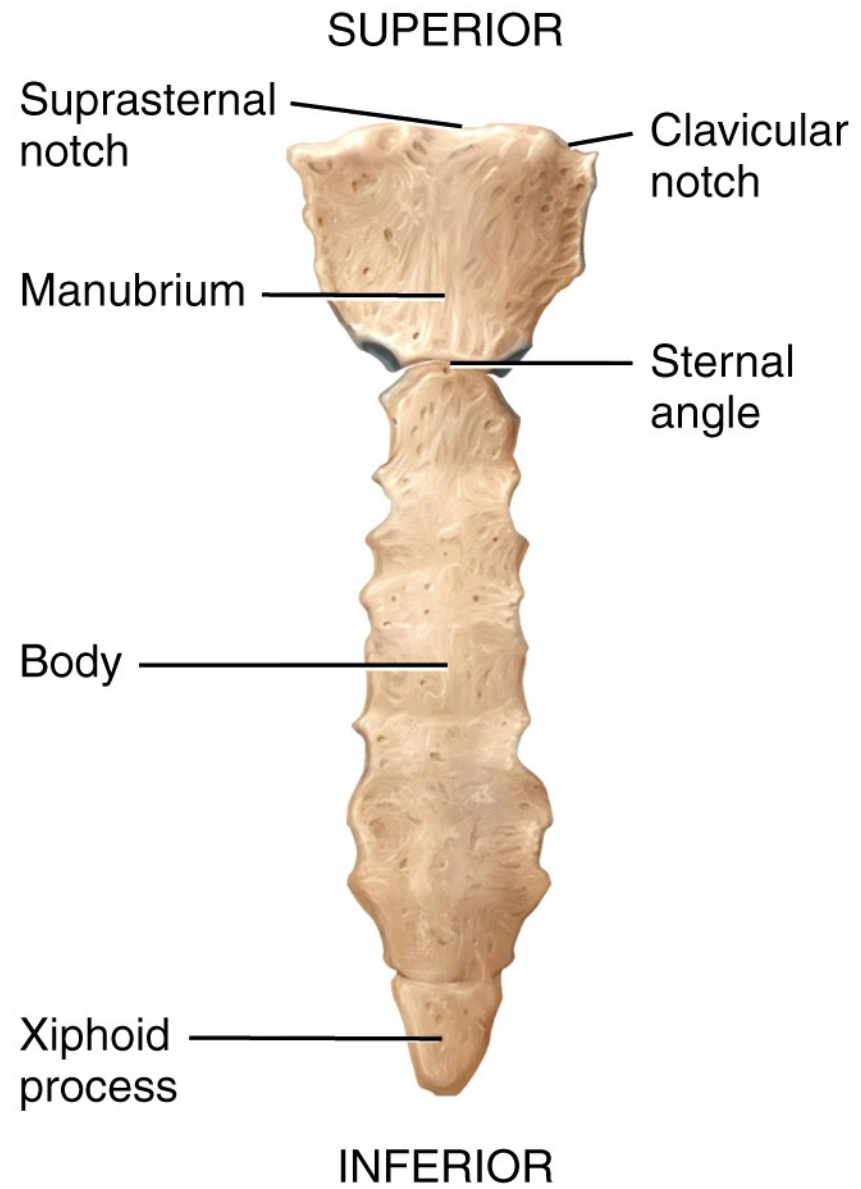
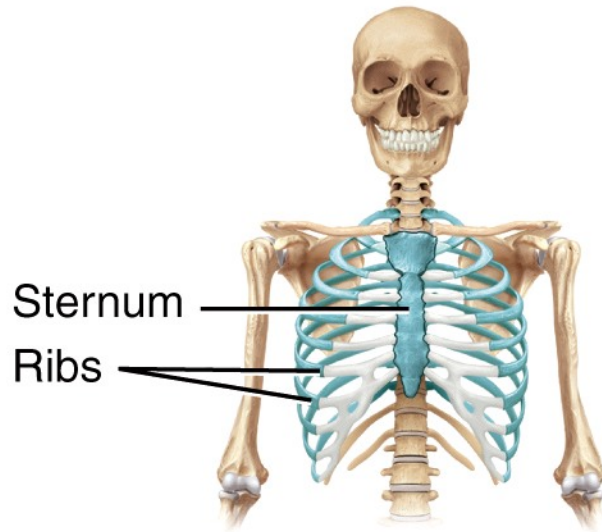
ANTERIOR



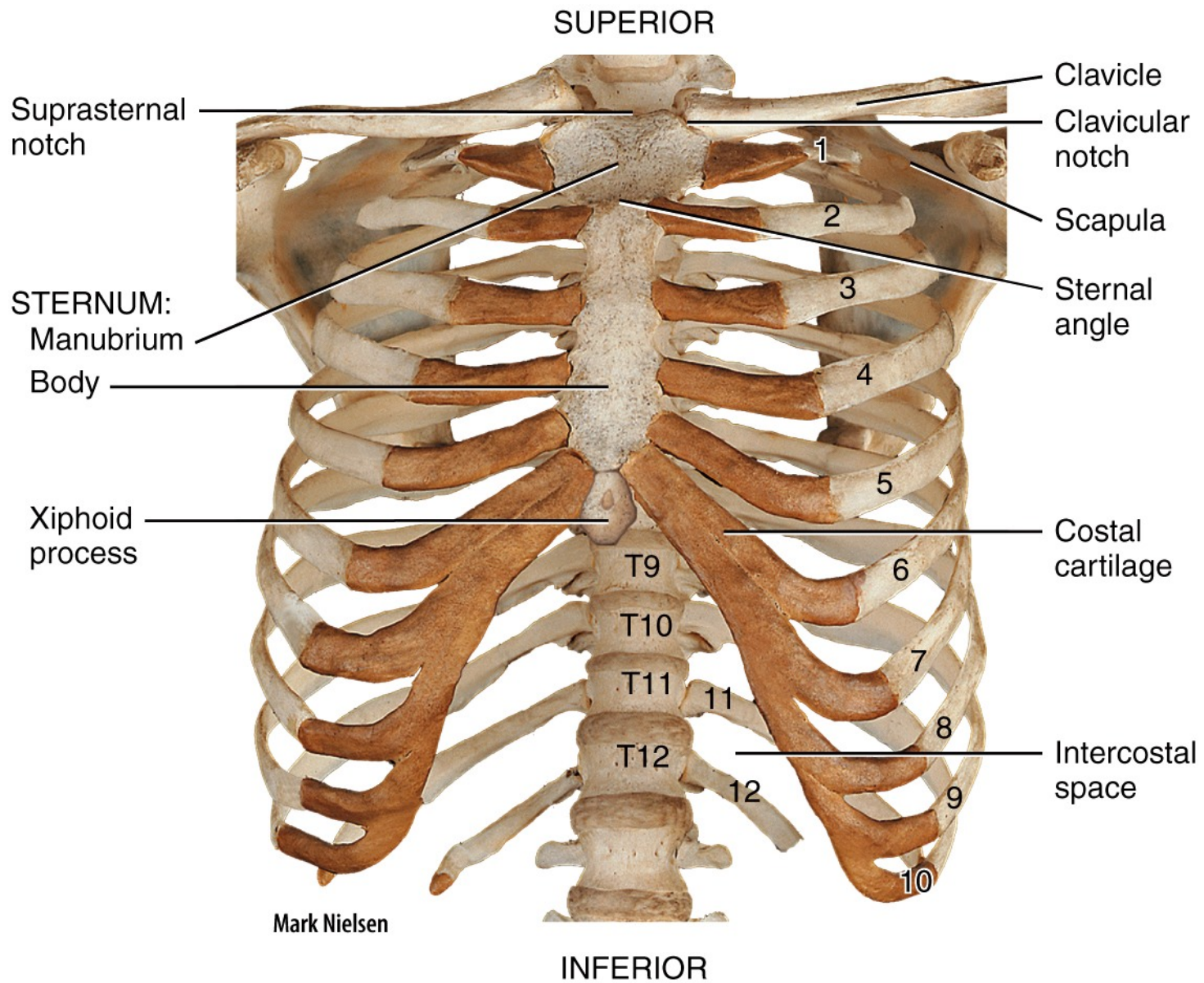
(a) Anterior view



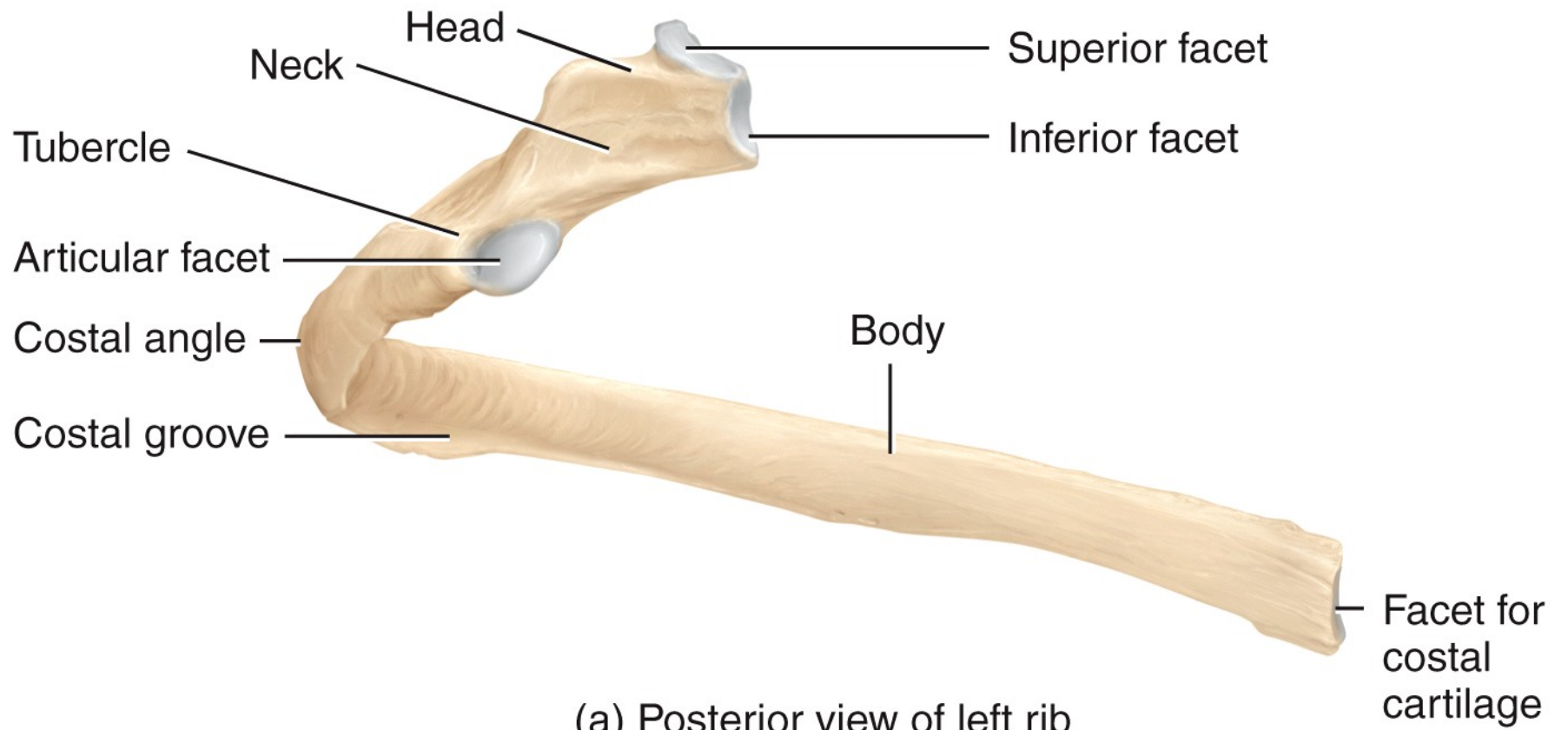
(b) Posterior view

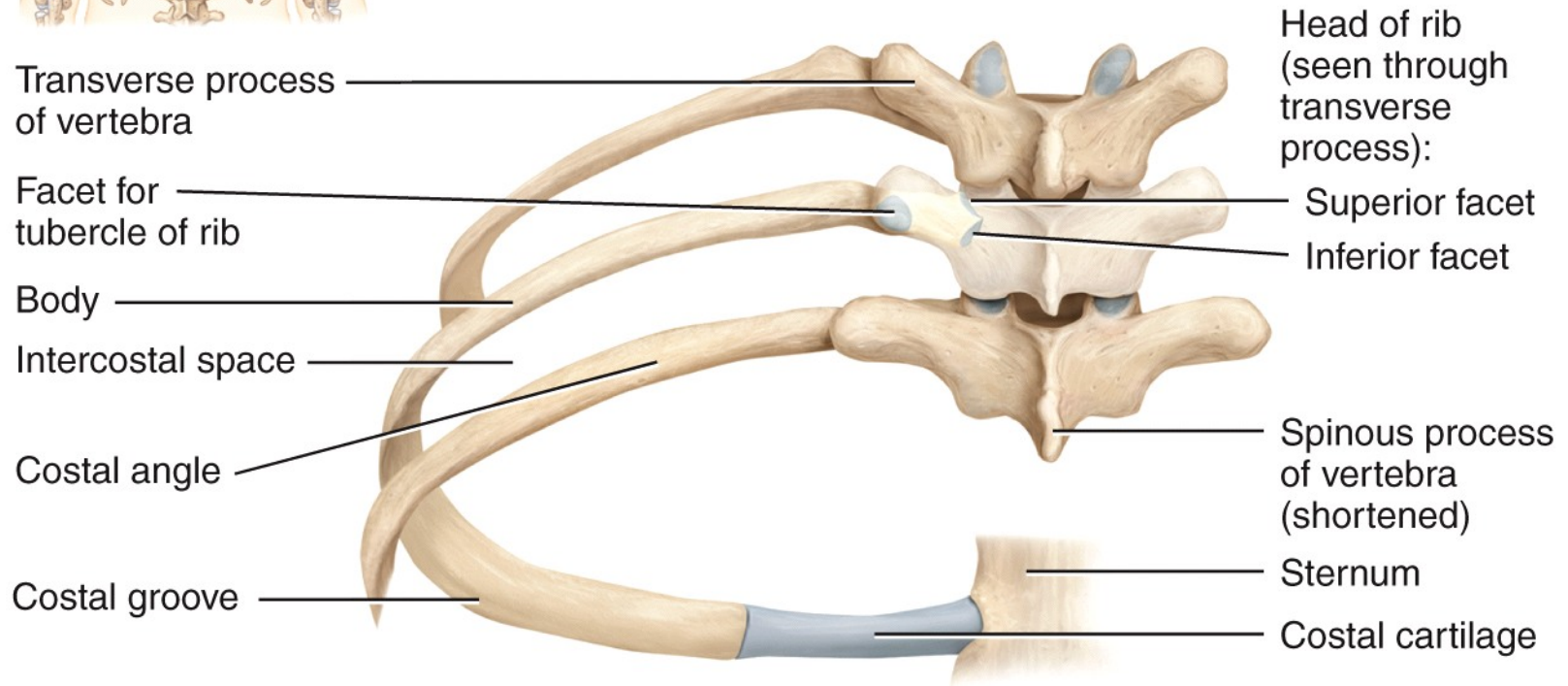
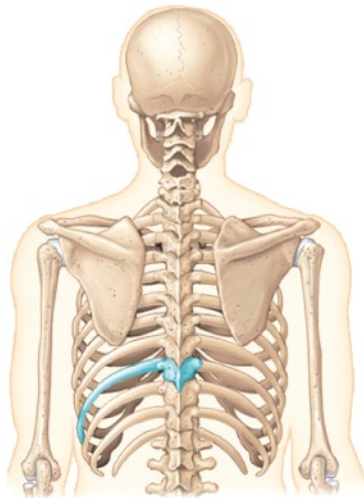


(a) Anterior view of sternum

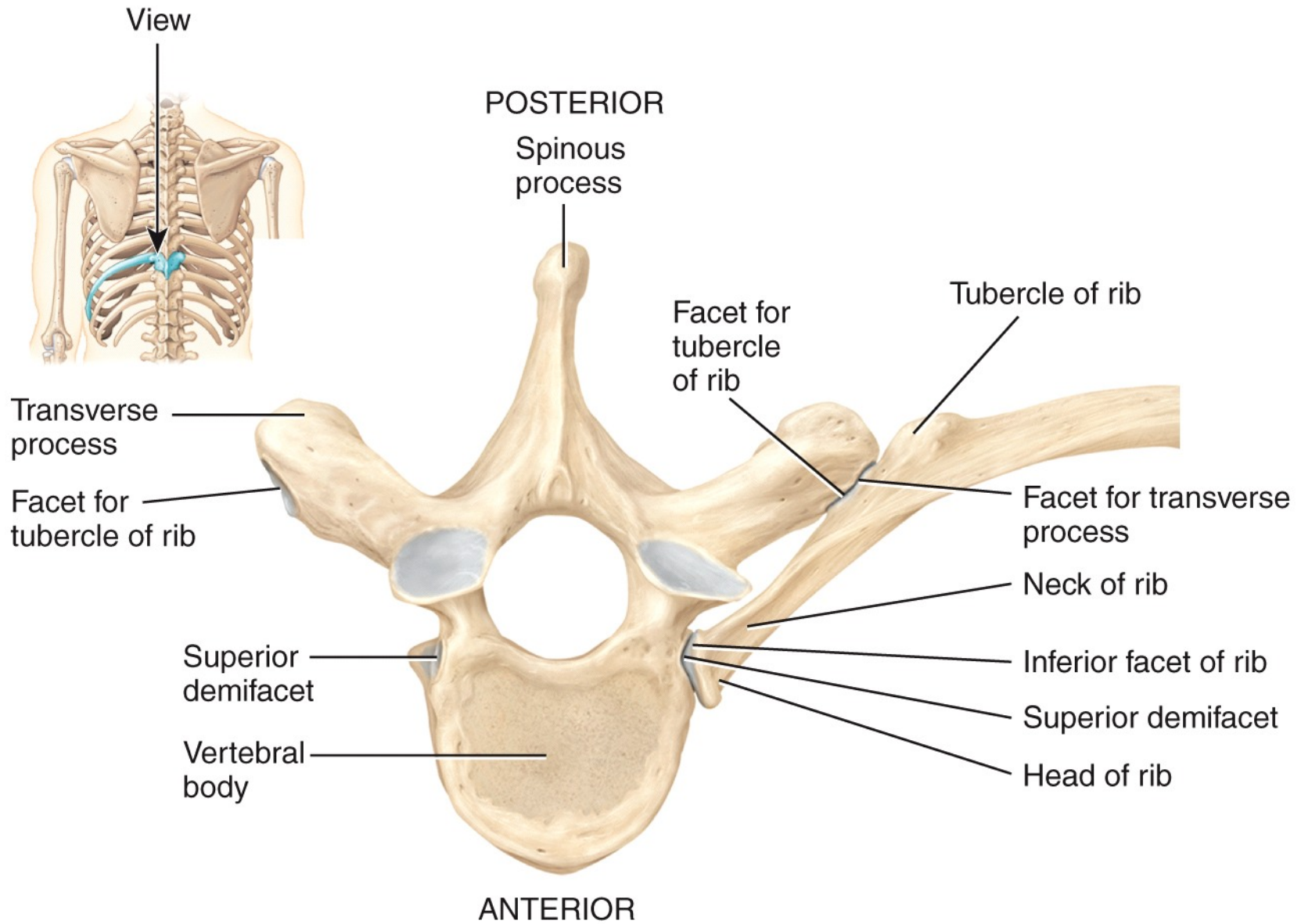


(b) Anterior view of skeleton of thorax



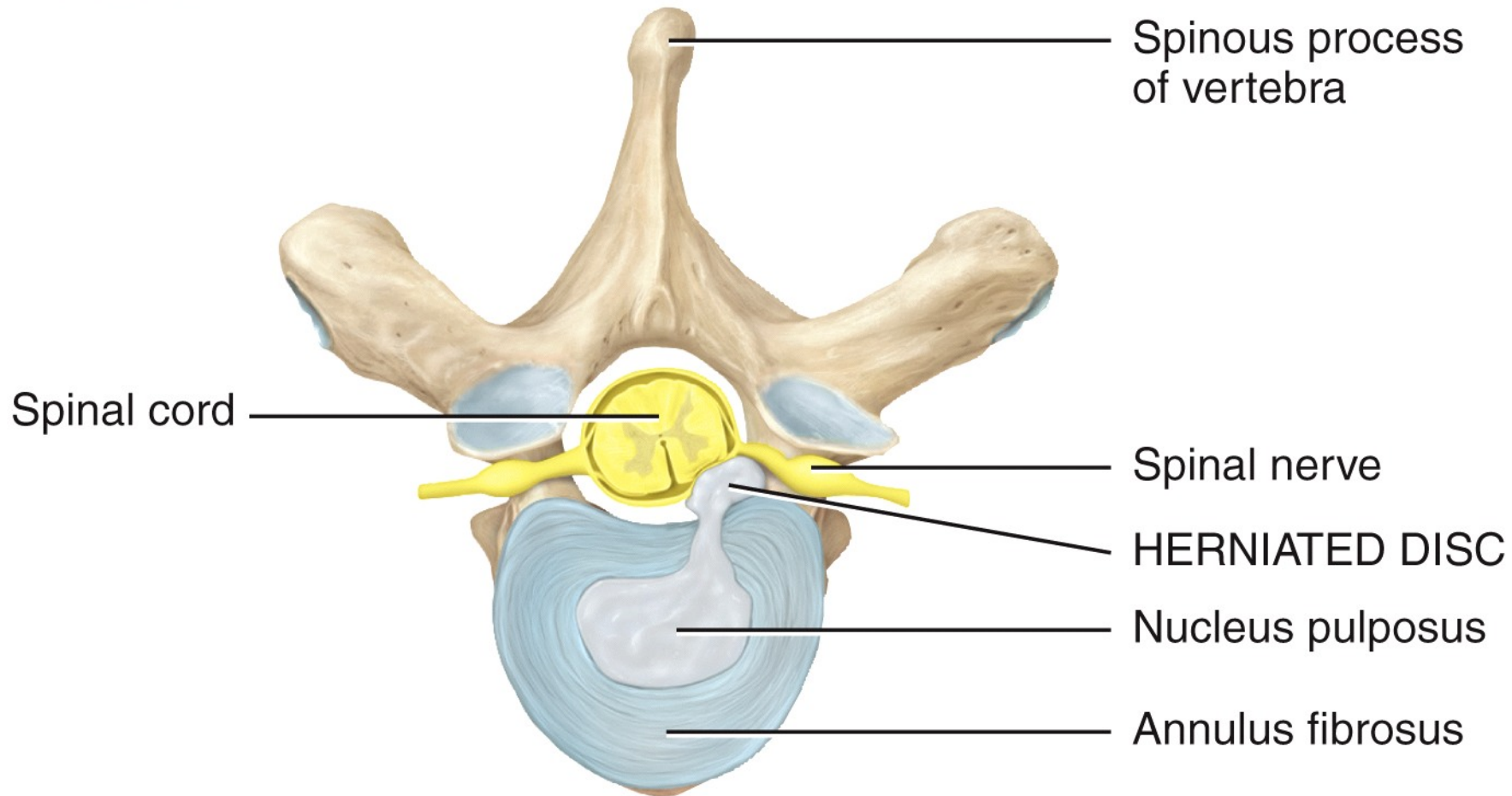


(b) Posterior view of left ribs articulated with thoracic vertebrae and sternum



(c) Superior view of left rib articulated with thoracic vertebra

POSTERIOR



Spinous process of vertebra

Spinal cord

Spinal nerve

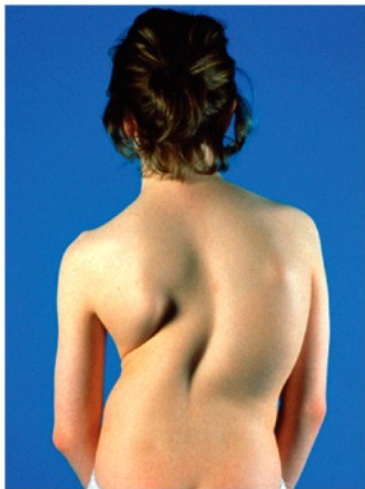
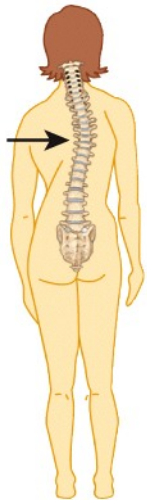HERNIATED DISC

Nucleus pulposus

Annulus fibrosus

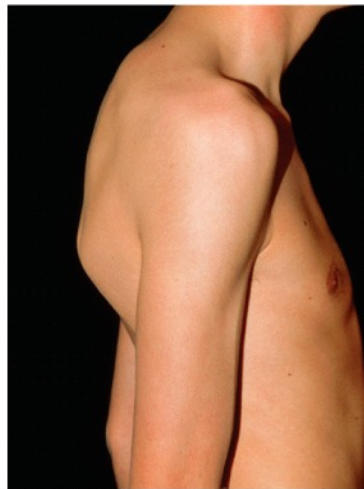
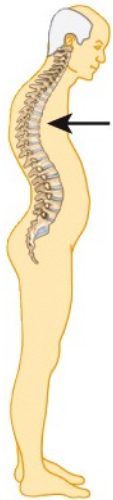ANTERIOR

Superior view



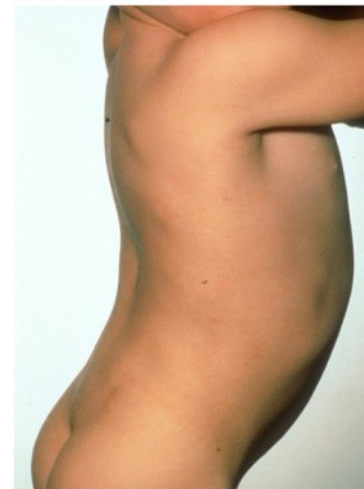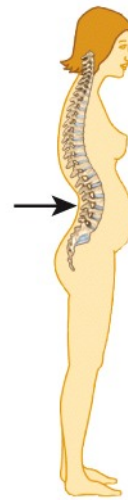Princess Margaret Rose Orthopaedic
Hospital/Photo Researchers, Inc.

(a) Scoliosis



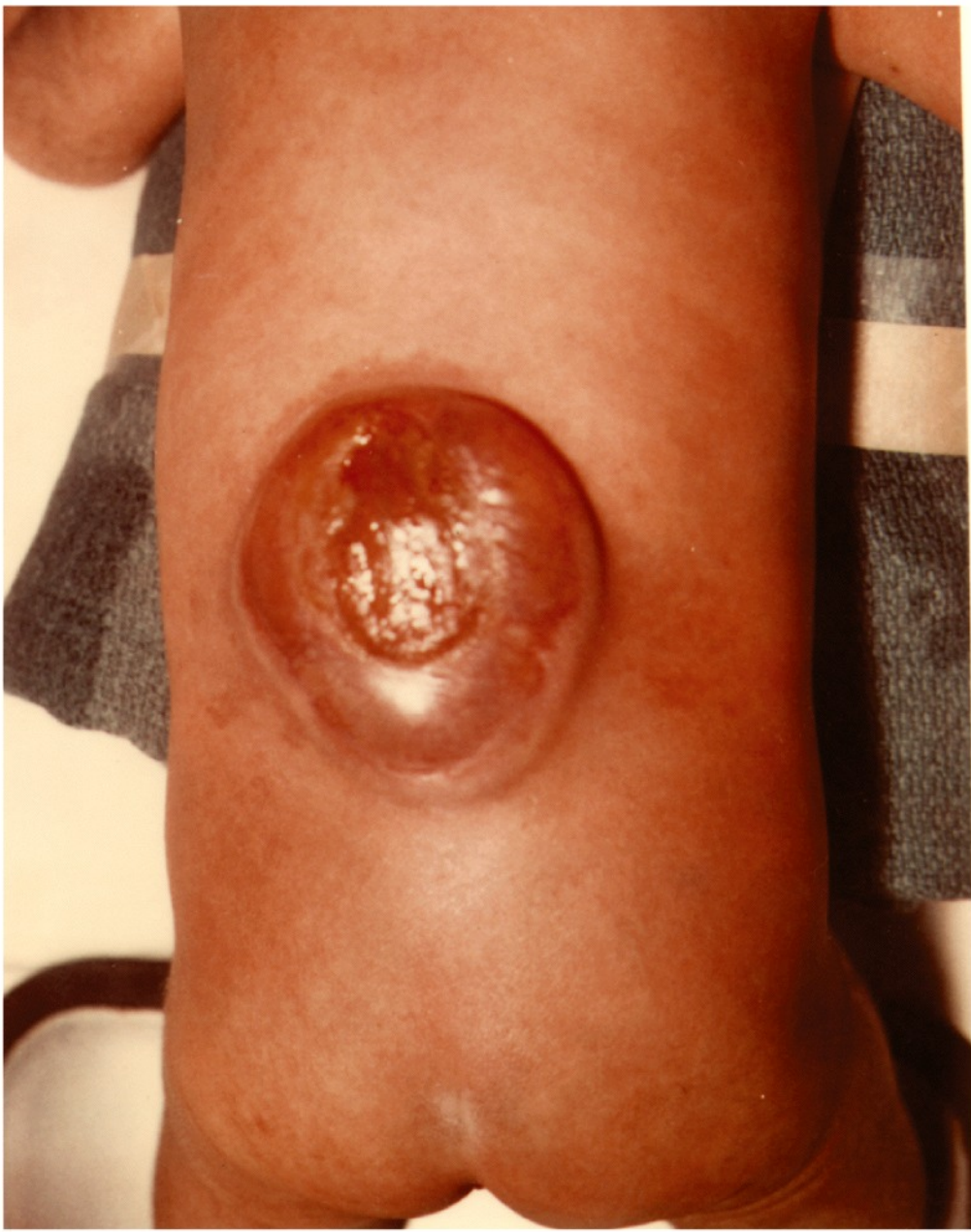Dr. P. Marazzi/Photo Researchers, Inc.

(b) Kyphosis



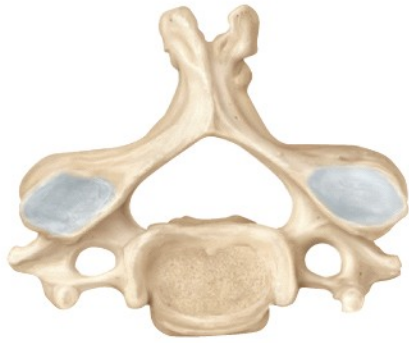Custom Medical Stock Photo, Inc.

(c) Lordosis

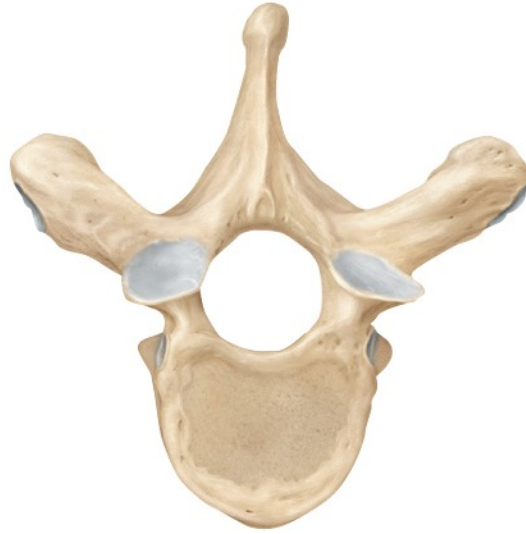

Center for Disease Control/Project Masters, Inc

Cervical



Thoracic



Lumbar

