Chapter 6

Bone Tissue

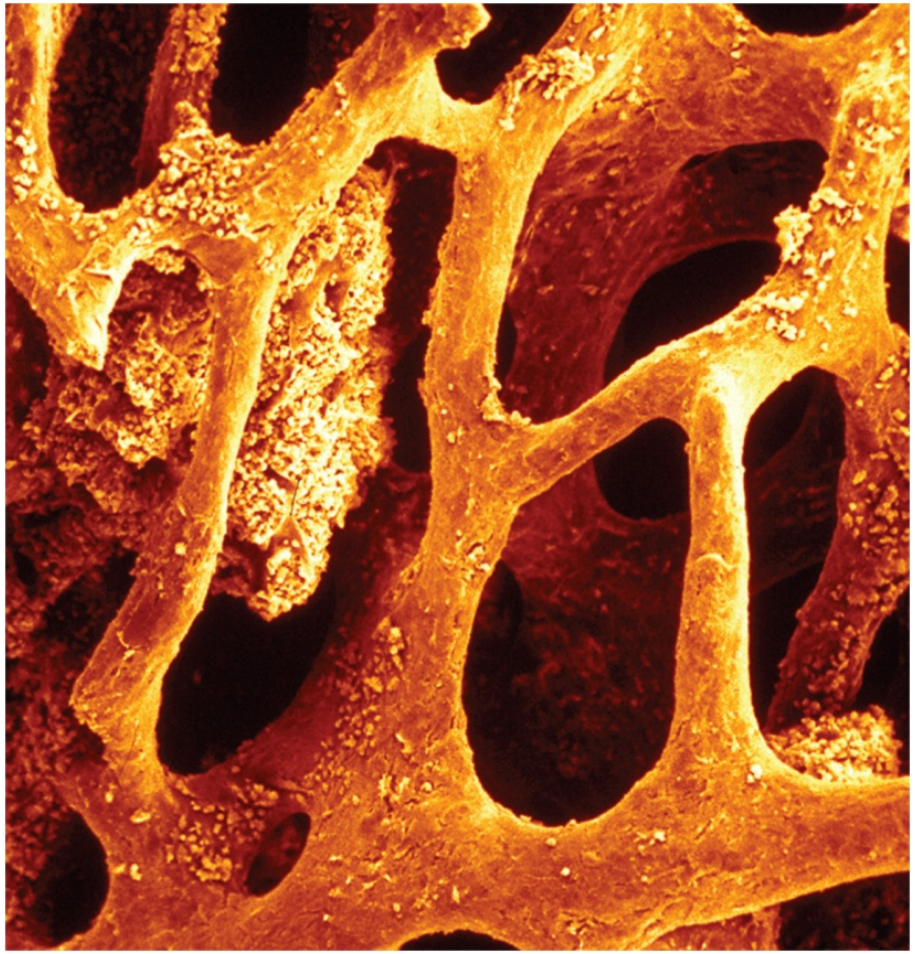

Functions of the Skeleton

- **support** – hold the body up, supports muscles, mandible and maxilla support teeth
- **protection** – brain, spinal cord, heart, lungs
- **movement** – limb movements, breathing, action of muscle on bone
- **electrolyte balance** – calcium and phosphate ions
- **acid-base balance** – buffers blood against excessive pH changes
- **blood formation** – red bone marrow is the chief producer of blood cells

Bones and Osseous Tissue

- bone (osseous tissue)
  - connective tissue consisting of cells and matrix
  - matrix composite of protein fibers (collagen) and calcium phosphate crystals
- continually remodels itself and interacts physiologically with all of the other organ systems of the body
- *permeated with nerves and blood vessels*, which attests to its sensitivity and metabolic activity

Bones and Osseous Tissue

- individual bones consist of:
  - bone tissue
  - bone marrow
  - cartilage
  - adipose tissue
  - nervous tissue
  - fibrous connective tissue

Structure of a Long Bone

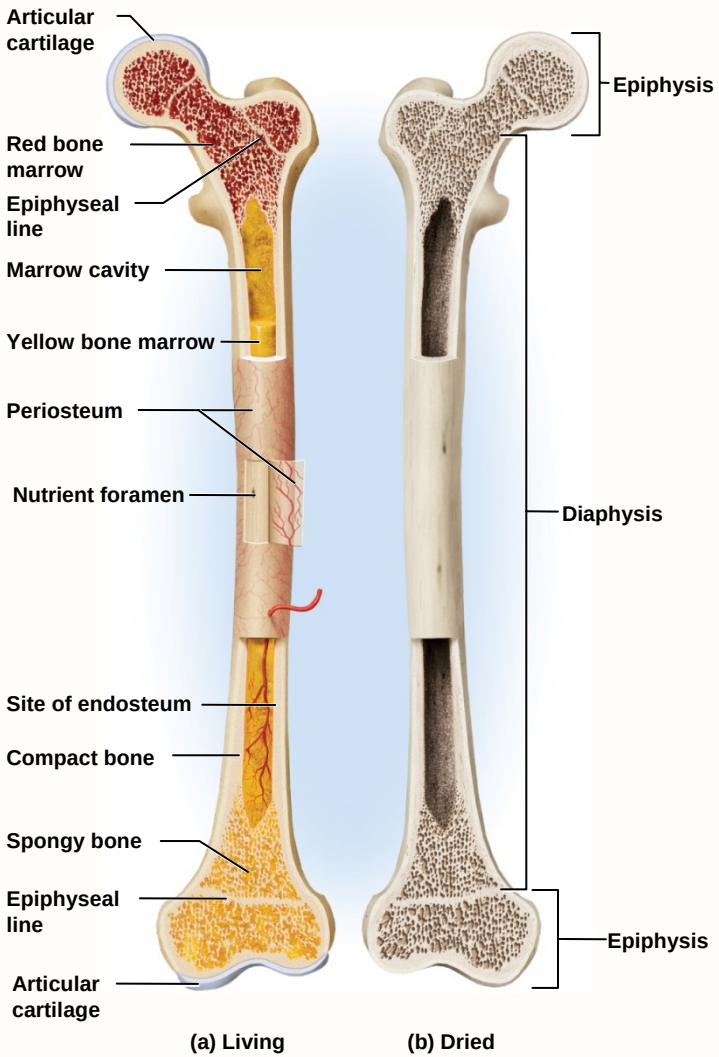

- epiphyses and diaphysis
- compact and spongy bone
- marrow cavity
- articular cartilage
- periosteum

General Features of Bones

- **compact (dense) bone** ***//*** Superficial layer of long bone // functional unit = osteon

- **diaphysis** (shaft) // cylinder of compact bone to provide leverage

- **medullary cavity** (marrow cavity) // space in middle of diaphysis
  - contains bone marrow
  - Yellow marrow = fat
  - red marrow = hemopoetic

- **epiphyses** // enlarged ends of a long bone // enlarged to strengthen joint and attach ligaments and tendons

General Features of Bones

- spongy (cancellous) bone
  - covered by more durable compact bone
  - skeleton about three-fourths compact and one-fourth spongy bone by weight
  - spongy bone found in ends of long bones, and the middle of nearly all others
- articular cartilage
  - a layer of hyaline cartilage
  - covers the joint surface where one bone meets another
  - allows joint to move more freely and friction free

General Features of Bones

- nutrient foramina
  - minute holes in the bone surface
  - allows blood vessels to penetrate bone to distribute blood to osteons and medulary cavity

General Features of Bones

- Periosteum // external sheath that covers bone
  - outer fibrous membrane = dense irregular
    - some outer fibers (collagen fibers) continuous with the tendons that attach muscle to bone
    - perforating (Sharpey's) fibers –fibers on inner surface of periosteum which penetrate into the bone matrix
    - strong attachment and continuity from muscle to tendon to bone
  - inner osteogenic layer of bone forming cells // important to growth of bone and healing of fractures
  - not present on articular surfaces (hyalin cartilage)

General Features of Bones

- endosteum
  - connective tissue membrane lining marrow cavity
  - Between membrane and bone there are osteogenic cells (osteoblast and osteoclast)
- epiphyseal plate (growth plate)
  - area of hyaline cartilage that separates the marrow spaces of the epiphysis and diaphysis
  - enables growth in length
- epiphyseal line
  - adults, a bony scar that marks where growth plate used to be

Structure of a Long Bone

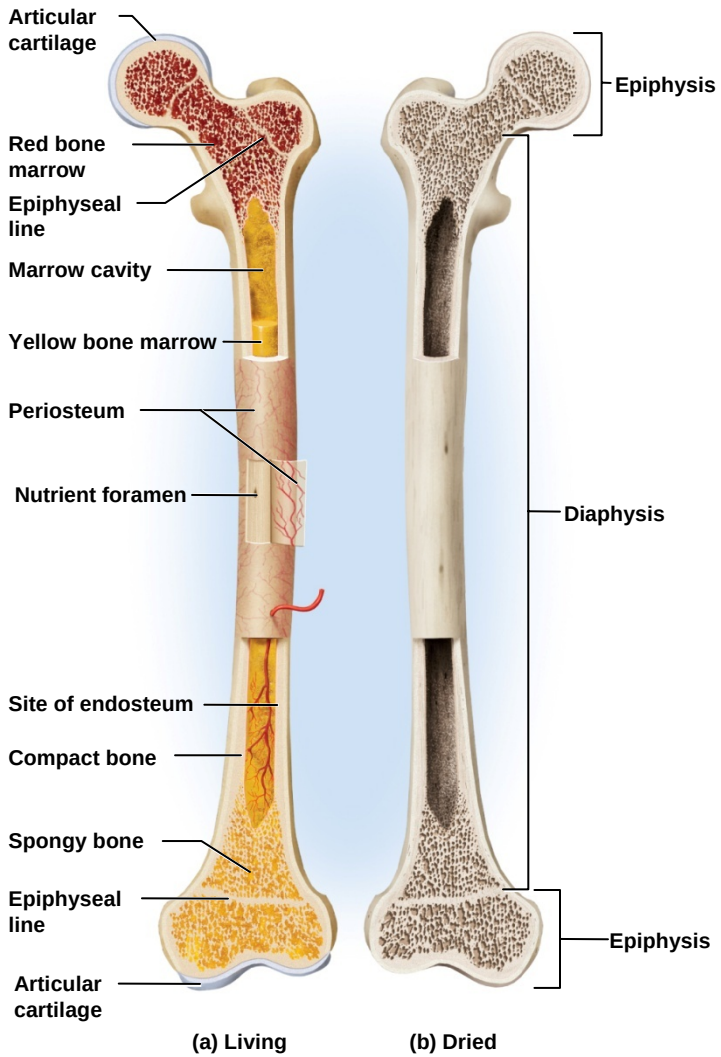

- epiphyses and diaphysis
- compact and spongy bone
- marrow cavity
- articular cartilage
- periosteum

Histology of Osseous Tissue

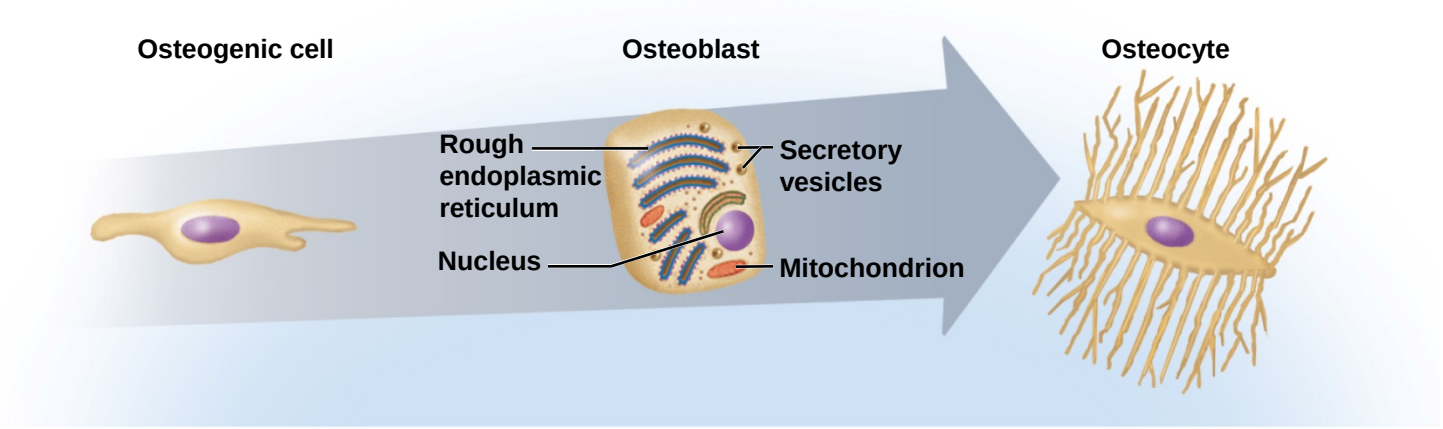

- **bone** is connective tissue that consists of cells, fibers and ground substance
- **four principal types** of bone cells (know function of these cell types!)
  - **osteogenic (osteoprogenator) cells**
  - **osteoblasts**
  - **osteocytes**
  - **Osteoclasts // formed by union of macrophage**

Osteogenic (osteoprogenator) cells

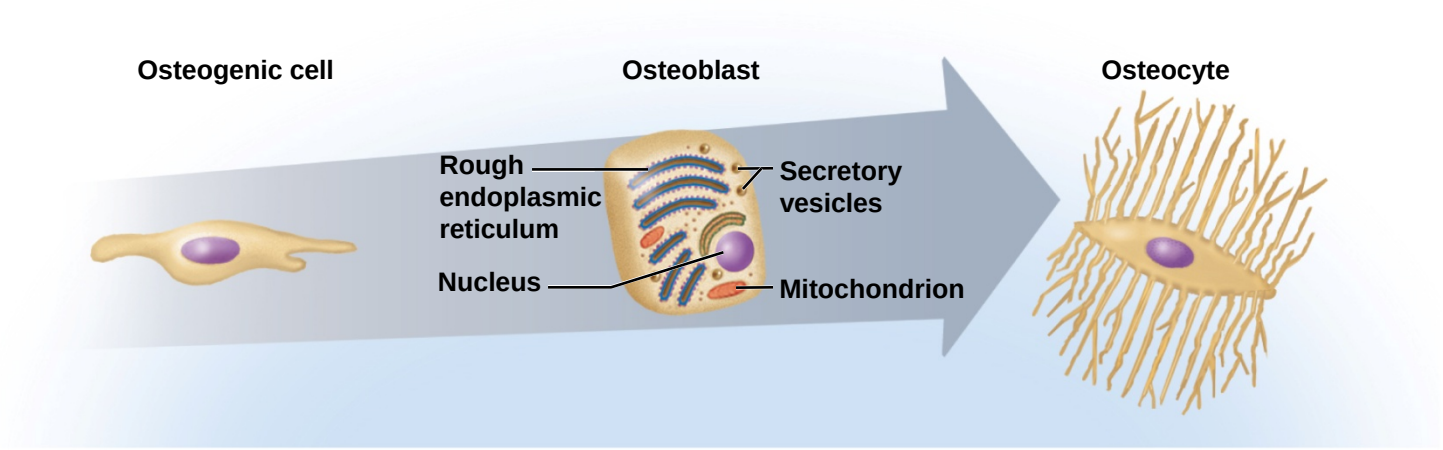

- stem cells found in endosteum, periosteum, and in central canals
- arise from embryonic mesenchymal cells
- multiply continuously to produce new osteoblasts

Osteoblasts

- bone forming cells
- line up as single layer of cells under endosteum and periosteum // are non-mitotic
- synthesize extracellular fiber = collagen / exocytosis / forms matrix
- Calcium phosphate crystals form in collagen fibers
- stress and fractures stimulate osteogenic cells to multiply more rapidly and increase number of osteoblasts to reinforce or rebuild bone

Osteoclasts

- bone-dissolving cells found on the bone surface
- osteoclasts develop from same bone marrow stem cells that give rise to blood cells / modified macrophage
- different origin from rest of bone cells
- unusually large cells formed from the fusion of several stem cells / typically have 3 to 4 nuclei, may have up to 50
- ruffled border – side facing bone surface
  - several deep infoldings of the plasma membrane which increases surface area and resorption efficiency
- resorption bays (Howship lacunae) – pits on surface of bone where osteoclasts reside
- remodeling – results from combined action of the bone-dissolving osteoclasts and the bone-depositing osteoblasts

Osteocytes

- Osteoblast transforms itself into an osteocyte
- Osteoblast become surrounded by the matrix they have deposited
- **lacunae** – tiny cavities where osteocytes reside
- **canaliculi** – little channels that connect lacunae
- cytoplasmic processes of osteocyte reach into canaliculi
- contribute to homeostatic mechanism of bone density and calcium and phosphate ions
- when stressed, produce biochemical signals that regulate bone remodeling
- If lamella eroded back to the osteocyte / can once again become an osteoblast

The Matrix

- bone is a composite – combination of two basic structural materials, a ceramic and a polymer
  - combines optimal mechanical properties of each component
  - bone combines the polymer, collagen, with the ceramic, hydroxyapatite and other minerals
  - ceramic portion allows the bone to support the body weight, and protein portion gives bone some degree of flexibility
- rickets – soft bones due to deficiency of calcium salts
- osteogenesis imperfecta - brittle bone disease
  - excessively brittle bones due to lack of the protein fiber / collagen

The Matrix

- matrix of osseous tissue / by dry weight
  - about one-third organic
  - two-thirds inorganic matter
  - organic matter
    - synthesized by osteoblasts
    - Collagen fibers, carbohydrate – protein complexes, such as glycosaminoglycans, proteoglycans, and glycoproteins
  - inorganic matter
    - 85% hydroxyapatite (crystallized calcium phosphate salt)
    - 10% calcium carbonate
    - other minerals (fluoride, sodium, potassium, magnesium)

Compact Bone

- **osteon (haversian system)** – the basic structural unit of compact bone
  - formed by a **central canal** and its **concentric lamella** connected to each other by **canaliculi**
  - a cylinder of tissue around a central canal
  - **perforating (Volkmann) canals** are transverse or diagonal passages along the length of the osteon
  - **collagen fibers** “corkscrew” down the matrix of the lamella giving it a helical arrangement
  - helices coil in one direction in one lamella and in the opposite direction in the next lamella for added strength

Compact Bone

- blood flow - skeleton receives about half a liter of blood per minute
- nutrient foramina – on the surface of bone tissue that allow blood vessels and nerves to enter the bone
  - open into the perforating canals that cross the matrix and feed into the central canals
  - innermost osteocytes near central canal receive nutrients and pass them along through their gap junction to neighboring osteocytes
  - they also receive wastes from their neighbors and transfer them to the central canal maintaining a two-way flow of nutrients and waste

Three Types of Lamellae in Compact Bone

- concentric lamellae // forms matrix around central canal
- circumferential lamellae // inner and outer boundaries of dense bone // run parallel to bone surface
- interstitial lamellae // remains of old osteons // as bone is remodeled some osteons are “eroded” // the fragments of old osteons are referred to as interstitial lamellae
- (see next slide)

Blood Vessels of Compact Bone

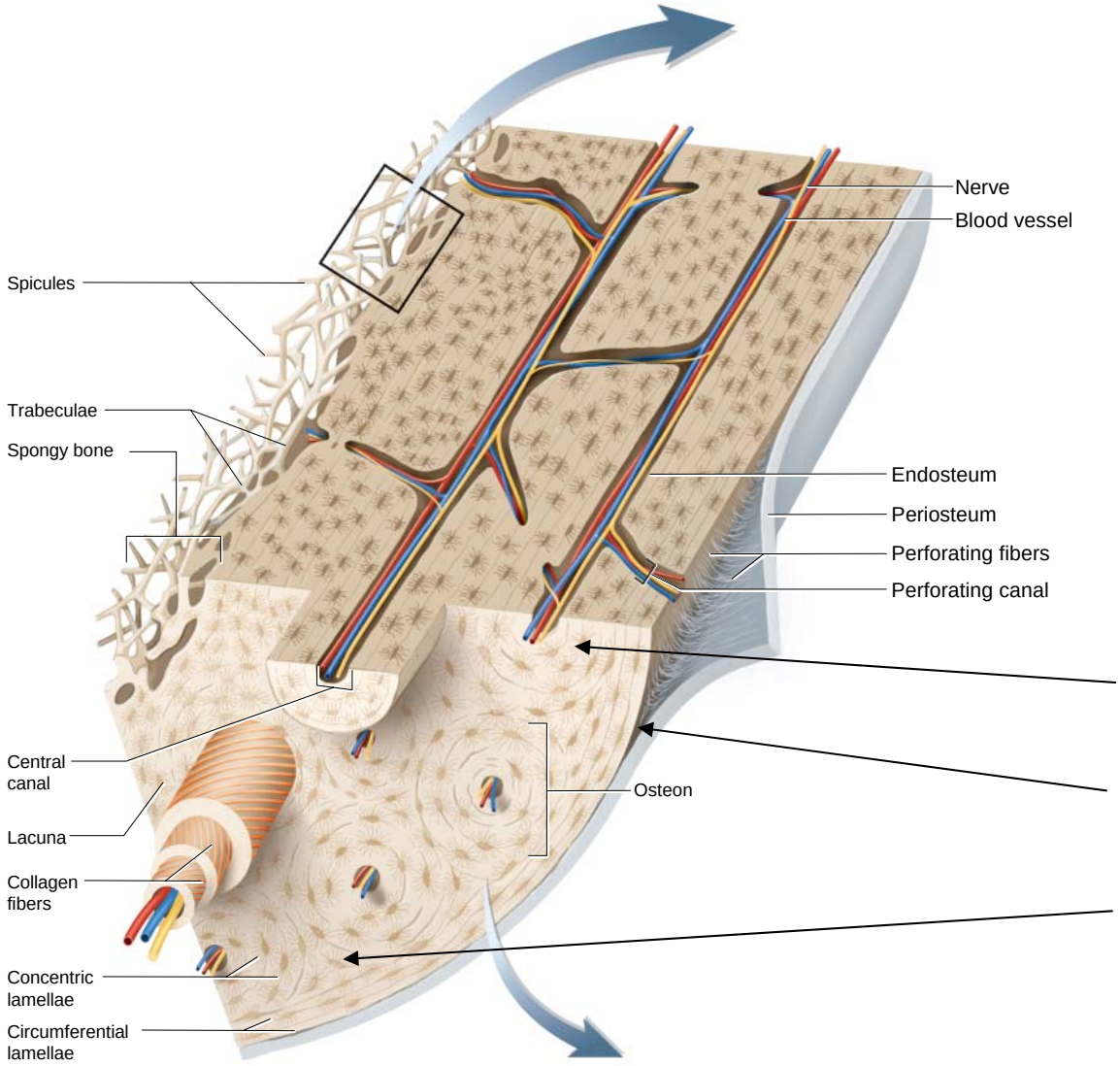

(b)

- **nutrient foramina //** on bone surface
- **perforating (Volkmann's) canals //** transverse or diagonal canals
- **central canals //** vertical canals
- **concentric lamellae**
- **circumferential lamellae**
- **interstitial lamellae**

Histology of Compact and Spongy Bone

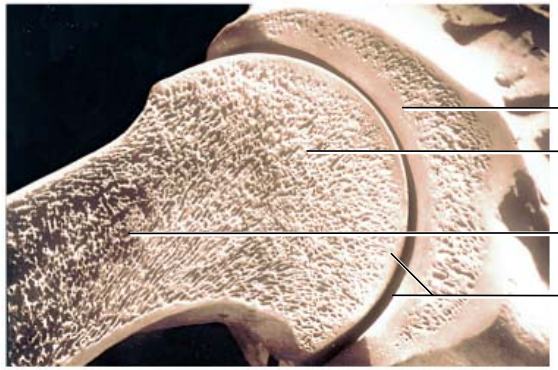

(a)

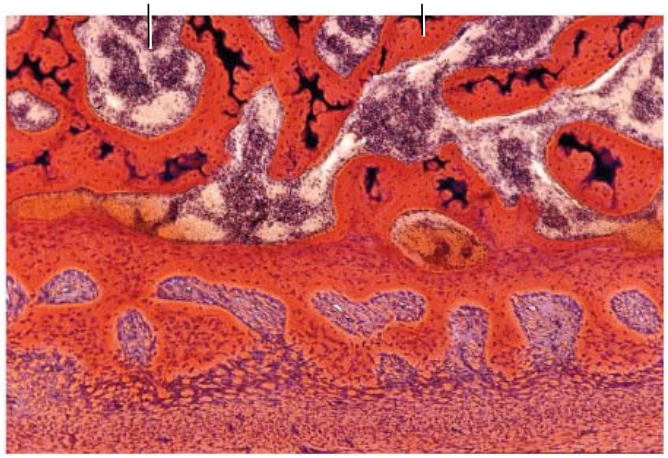

(c)



(d)

20 μm

Spongy Bone (Cancellous Bone)

- sponge-like appearance // as hard as compact bone
- spongy bone consists of:
  - slivers of bone called **spicules**
  - thin plates of bone called **trabeculae**
  - spaces filled with **bone marrow**
- few osteons and no central canals
- all osteocytes close to bone marrow
- provides strength with minimal weight // trabeculae develop along bone's lines of stress

Design of Spongy Bone

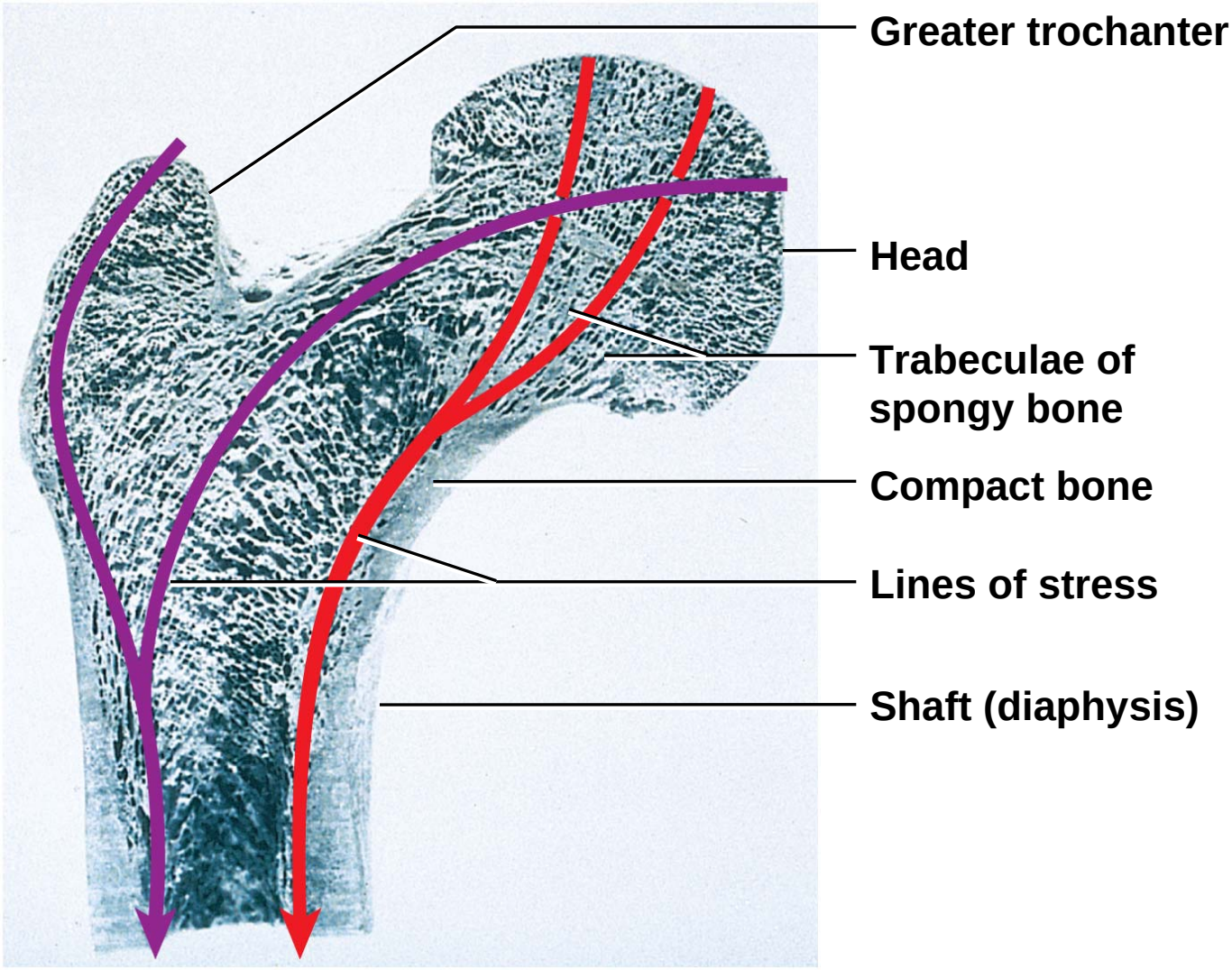

Structure of a Flat Bone

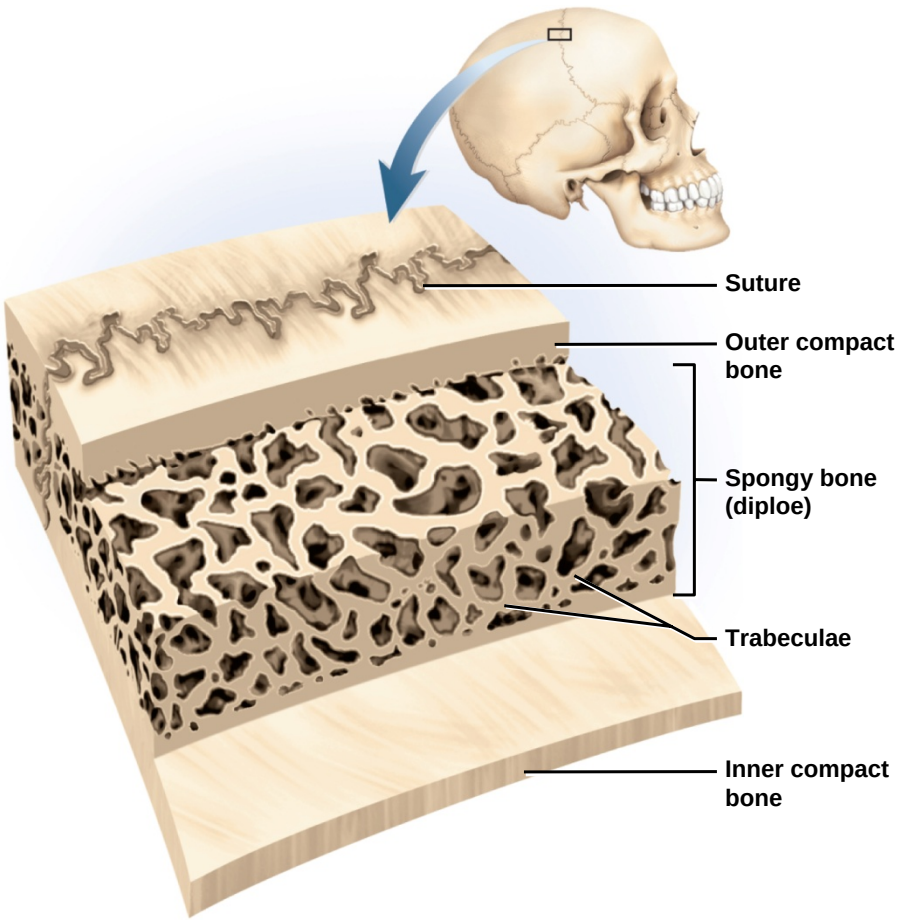

- sandwich-like construction
- two layers of compact bone enclosing a middle layer of spongy bone
  - both surfaces of flat bone covered with periosteum
- **diploe** – spongy layer in the cranium
  - absorbs shock
  - marrow spaces lined with endosteum

Bone Marrow

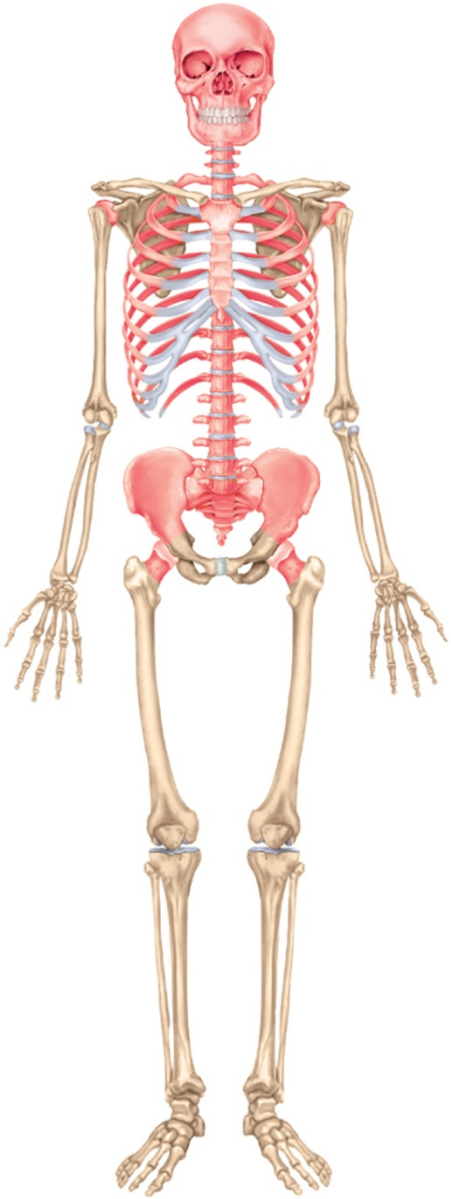

- **bone marrow** – general term for soft tissue that occupies the marrow cavity of a long bone and small spaces amid the trabeculae of spongy bone
- **red marrow (myeloid tissue)**
  - in nearly every bone in a child
  - **hemopoietic tissue** - produces blood cells and is composed of multiple tissues in a delicate, but intricate arrangement that is an organ to itself
  - in adults, found in **skull**, **vertebrae**, **ribs**, **sternum**, part of **pelvic girdle**, and **proximal heads of humerus and femur**
- **yellow marrow** found in adults
  - most red marrow turns into fatty yellow marrow
  - no longer produces blood

Chapter 6

Bone Development

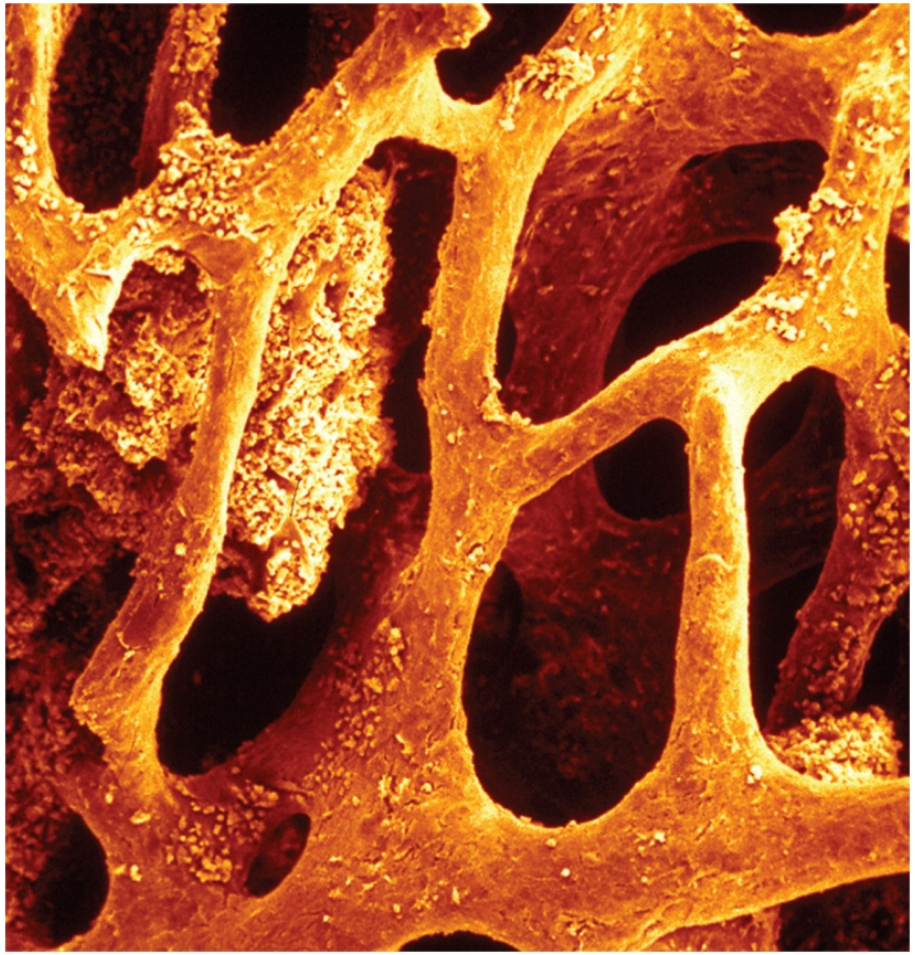

Bone Development in Fetal Growth

- **Ossification or osteogenesis =** the formation of new bone
- Bone grows differently during fetal-infant and adult stages

- **In the human fetus and infant bone growth by:**
  - intramembranous ossification
  - endochondral ossification
- **In human adults bone growth by:**
  - interstitial ossification
  - appositional ossification

Intramembranous Ossification

- these bones develop within a fibrous membrane similar to the epidermis of the skin (**dermal bones**)
  - **mesenchyme** – embryonic connective tissue condenses into a layer of soft tissue with dense supply of blood capillaries
  - **mesenchymal cells** differentiate into **osteogenic cells**
  - regions of mesenchyme become a network of soft sheets – **trabeculae**
  - osteogenic cells differentiate into **osteoblasts**
    - these cells deposit organic matrix – **osteoid tissue**

Intramembranous Ossification

- as trabeculae grow thicker, calcium phosphate is deposited in the matrix

- mesenchyme close to the surface of a trabecula remains uncalcified // becomes denser and more fibrous, forming periosteum

- osteoblasts continue to deposit minerals // producing a honeycomb of bony trabeculae

  - some persist as permanent spongy bone
  - osteoclasts resorb and remodel others to form a marrow cavity in the middle of bone

- trabeculae at the surface continue to calcify until the spaces between them are filled in, converting spongy bone to compact bone

- gives rise to the sandwich-like arrangement of mature flat bone

Intramembranous Ossification

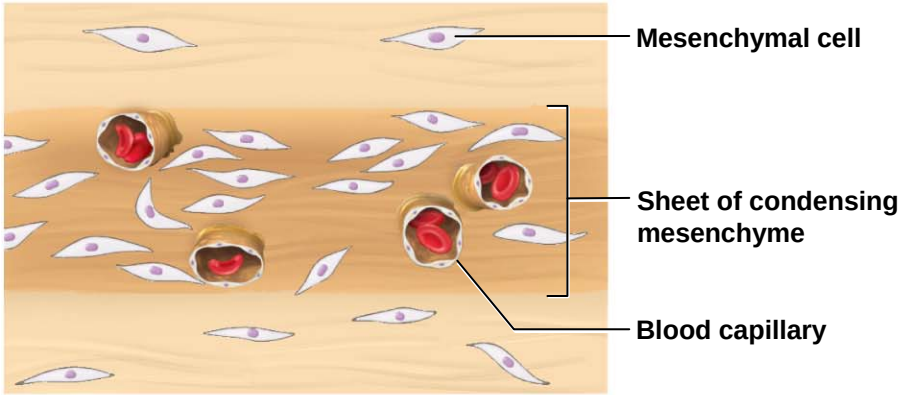

1 Condensation of mesenchyme into soft sheet permeated with blood capillaries

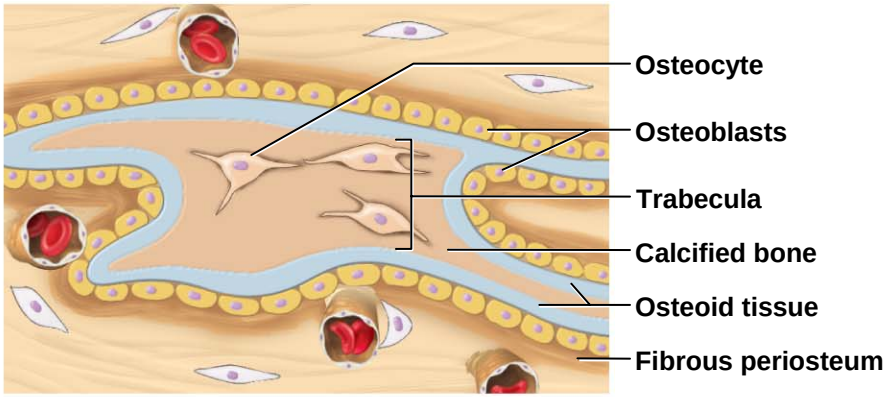

2 Deposition of osteoid tissue by osteoblasts on mesenchymal surface; entrapment of first osteocytes; formation of periosteum

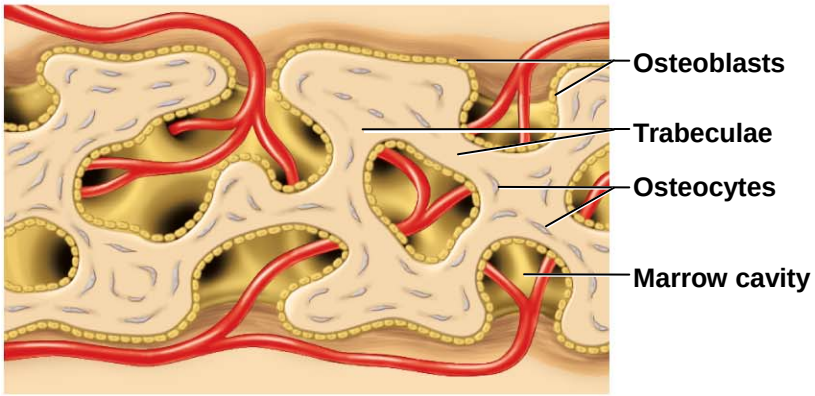

3 Honeycomb of bony trabeculae formed by continued mineral deposition; creation of spongy bone

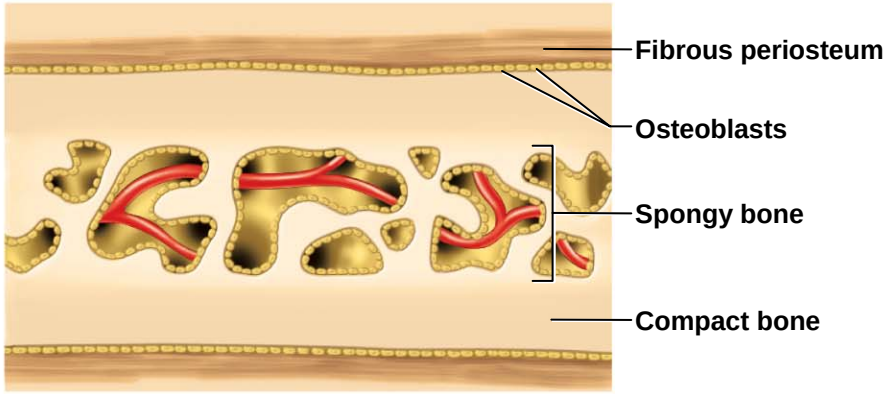

4 Surface bone filled in by bone deposition, converting spongy bone to compact bone. Persistence of spongy bone in the middle layer.

e.g. // produces flat bones of skull and clavicle

Intramembranous Ossification

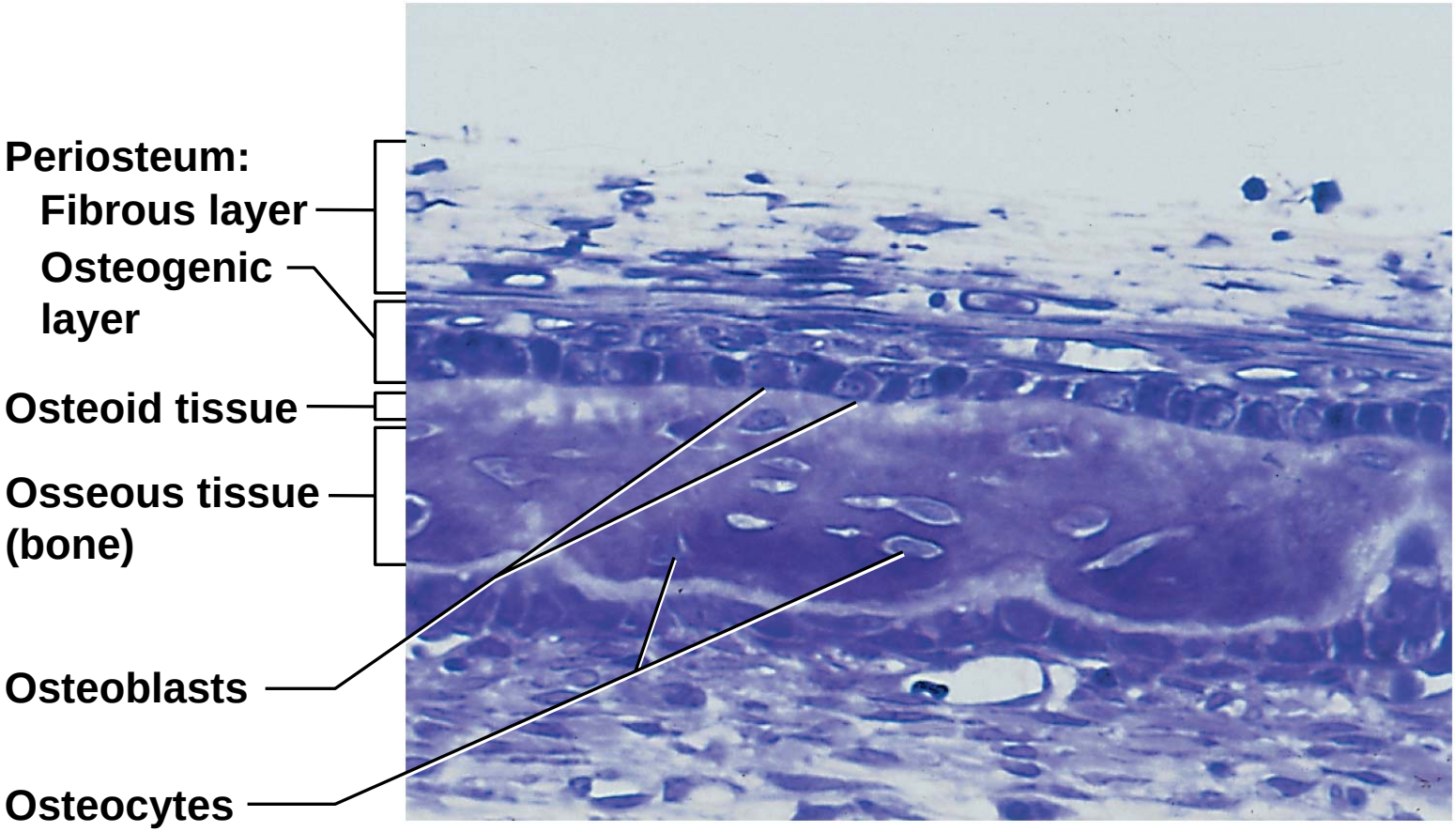

note the periosteum and osteoblasts

Endochondral Ossification

- process in which bone develops from pre-existing hyaline cartilage model
  - beginning the 6th fetal week and ending in early 20's
  - most bones develop by this process
- mesenchyme develops into a body of hyaline cartilage in location of future bone
  - covered with fibrous perichondrium /// perichondrium produces chondrocytes initially, and later produces osteoblasts
  - osteoblasts form a bony collar around middle of cartilage model
  - former perichondrium is now considered to be periosteum

Stages of Endochondral Ossification

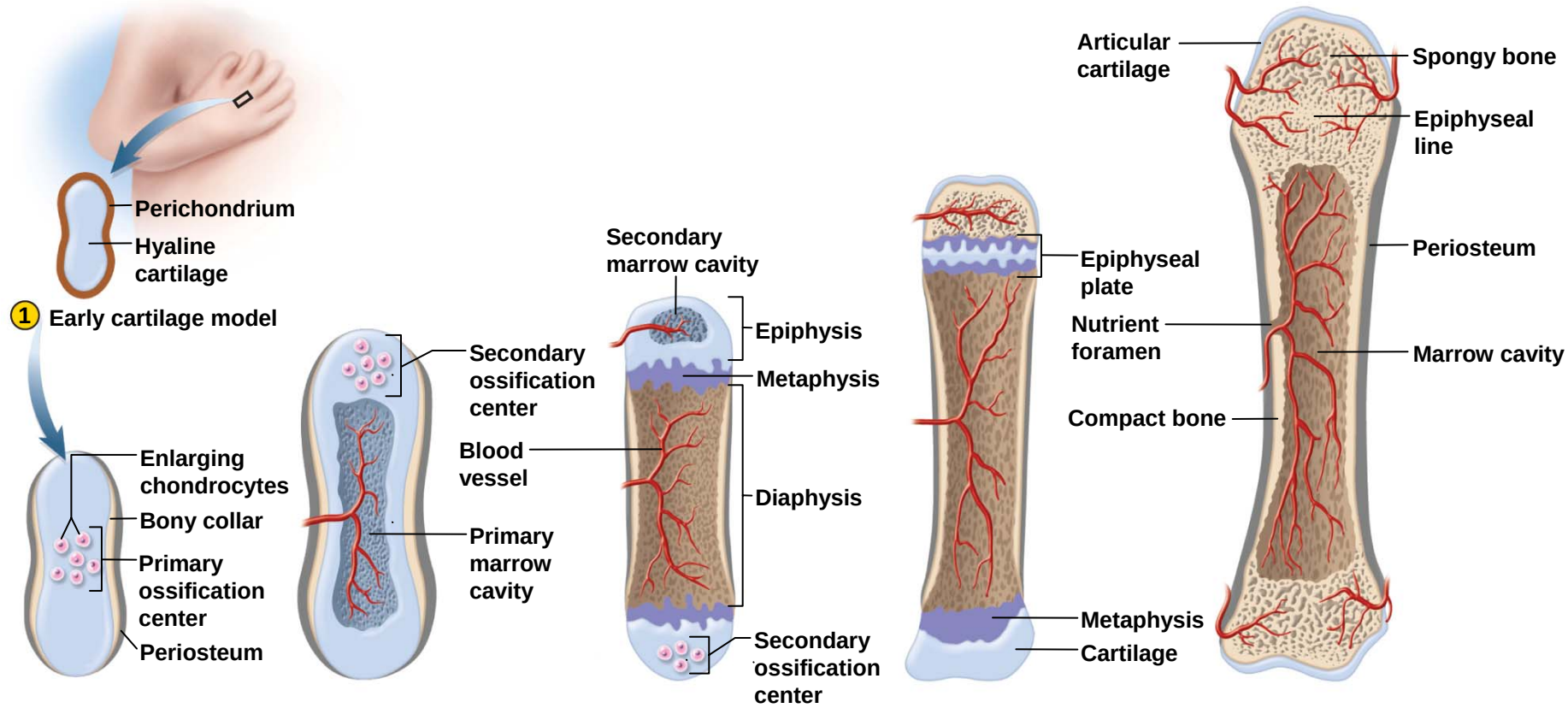

2 Formation of primary ossification center, bony collar, and periosteum

3 Vascular invasion, formation of primary marrow cavity, and appearance of secondary ossification center

4 Bone at birth, with enlarged primary marrow cavity and appearance of secondary marrow cavity in one epiphysis

5 Bone of child, with epiphyseal plate at distal end

6 Adult bone with a single marrow cavity and closed epiphyseal plate

Endochondral Ossification

- primary ossification center - chondrocytes in the middle of the model enlarge
  - matrix between lacunae are reduced to thin walls
  - walls of this thin matrix ossify and block nutrients from reaching chondrocytes
  - they die and their lacunae merge into a single cavity in the middle of the model

- blood vessels penetrate the bony collar and invade primary ossification center
  - primary marrow cavity – forms from blood and stem cells filling hollow cavity

Fetal Skeleton at 12 Weeks

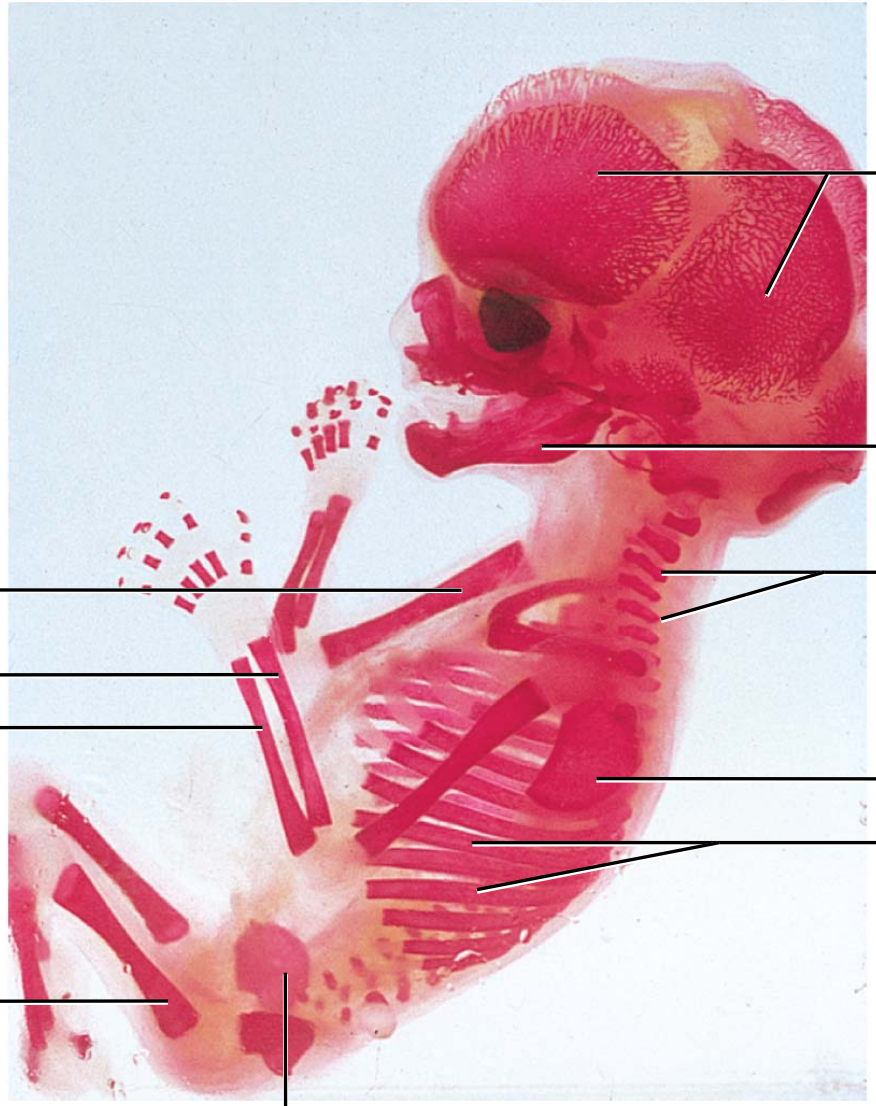

Primary Ossification Center and Primary Marrow Cavity

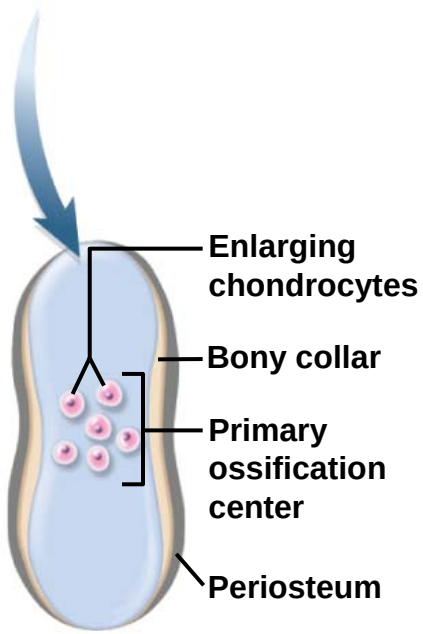

2 Formation of primary ossification center, bony collar, and periosteum

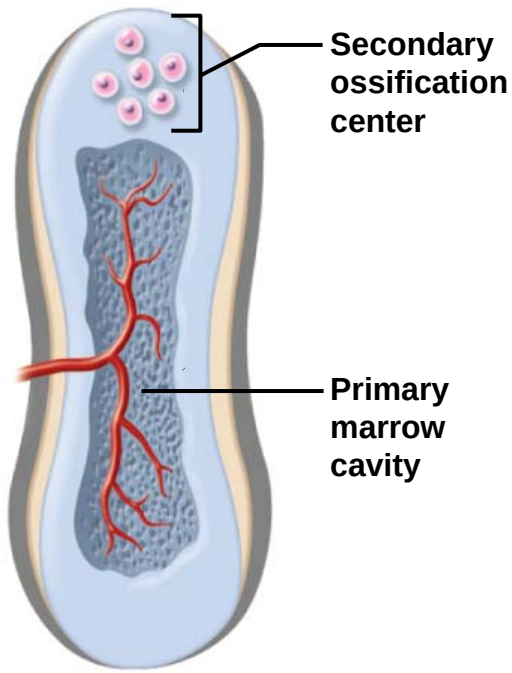

3 Vascular invasion, formation of primary marrow cavity, and appearance of secondary ossification center

Endochondral Ossification

- blood vessels penetrate the bony collar and invade primary ossification center
  - primary marrow cavity – forms from blood and stem cells filling hollow cavity
  - stem cells give rise to osteoblasts and osteoclasts
  - osteoblasts line cavity and deposit osteoid tissue and calcify it
    - forming temporary network of trabeculae
  - wave of cartilage death progresses toward the ends
    - osteoclasts follow the wave dissolving the cartilage remnants enlarging the marrow cavity
  - metaphysis – region of transition from cartilage to bone at each end of primary marrow cavity

Endochondral Ossification

- secondary ossification center – created by chondrocyte enlargement and death in the epiphyses
  - become hollowed out by the same process generating a secondary marrow cavity in epiphyses
  - cavity expands outward from the center in all directions

Secondary Ossification Centers and Secondary Marrow Cavities

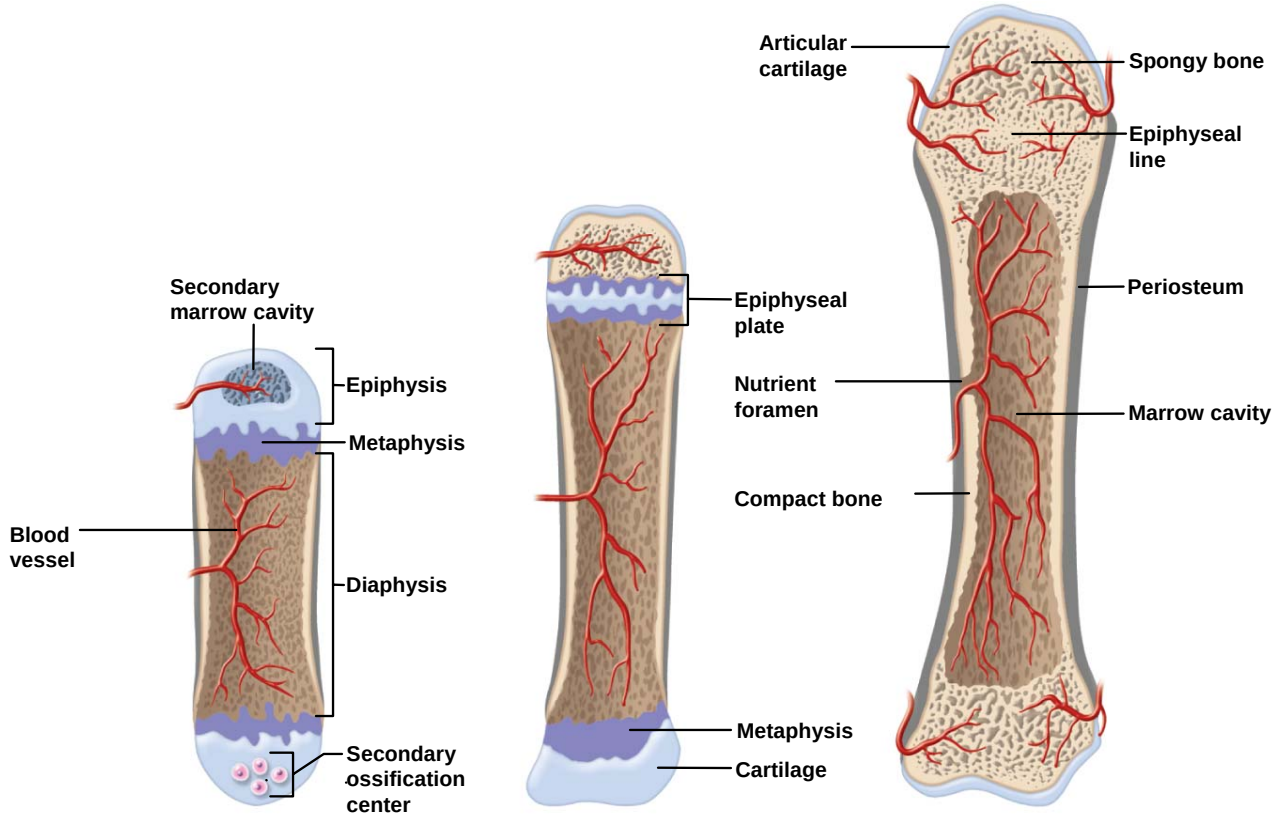

4 Bone at birth, with enlarged primary marrow cavity and appearance of secondary marrow cavity in one epiphysis

5 Bone of child, with epiphyseal plate at distal end

6 Adult bone with a single marrow cavity and closed epiphyseal plate

Stages of Endochondral Ossification

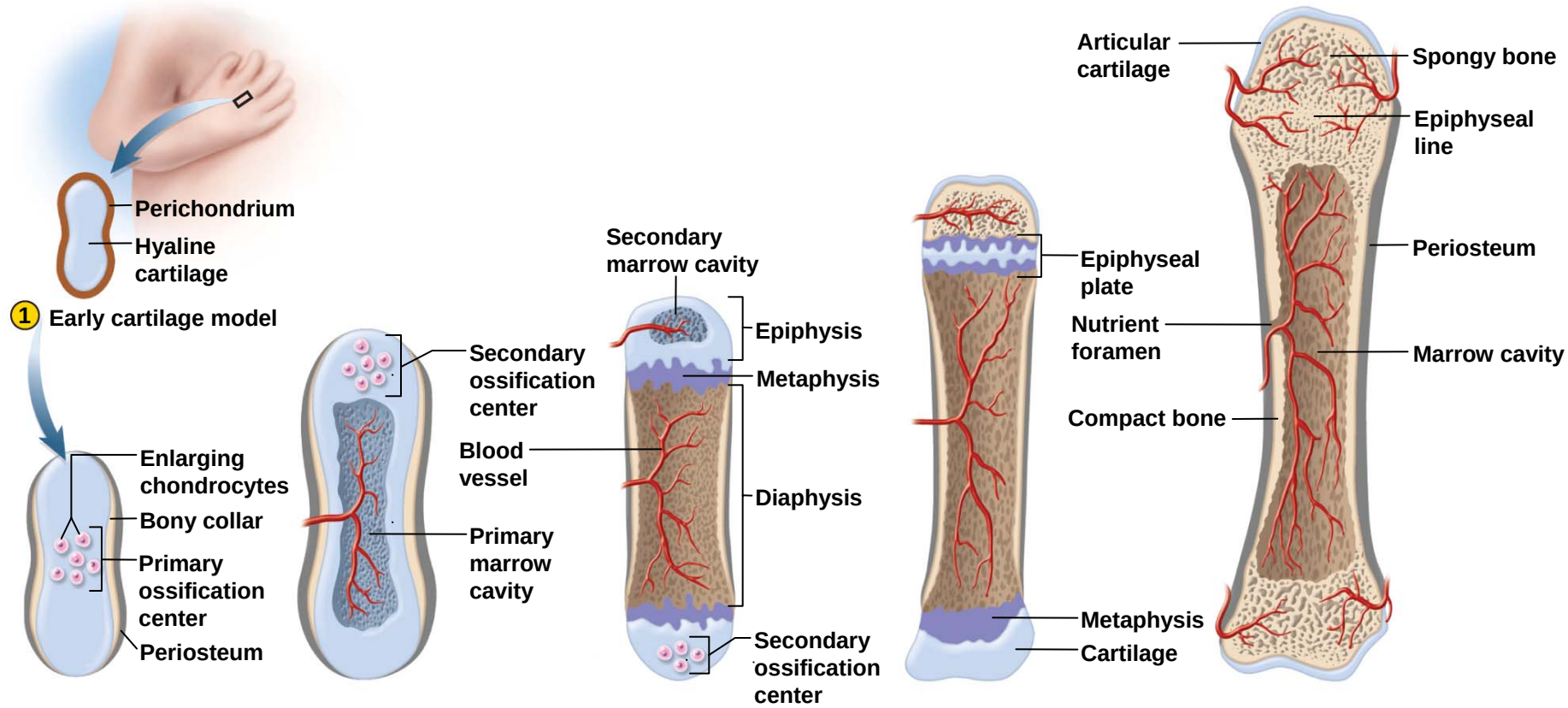

2 Formation of primary ossification center, bony collar, and periosteum

3 Vascular invasion, formation of primary marrow cavity, and appearance of secondary ossification center

4 Bone at birth, with enlarged primary marrow cavity and appearance of secondary marrow cavity in one epiphysis

5 Bone of child, with epiphyseal plate at distal end

6 Adult bone with a single marrow cavity and closed epiphyseal plate

Postpartum Bone Growth

- during infancy and childhood, the epiphyses fill with spongy bone
- cartilage limited to the articular cartilage covering each joint surface, and to the epiphyseal plate
  - a thin wall of cartilage separating the primary and secondary marrow cavities
  - epiphyseal plate persists through childhood and adolescence
  - *serves as a growth zone for bone elongation*

Postpartum Bone Growth

- by late teens to early twenties, all remaining cartilage in the epiphyseal plate is generally calcified
  - gap between epiphyses and diaphysis closes
  - primary and secondary marrow cavities unite into a single cavity
  - *bone can no longer grow in length*
  - epiphyseal line "remains" as shadow of old epiphyseal plate

Cartilaginous Epiphyseal Plates

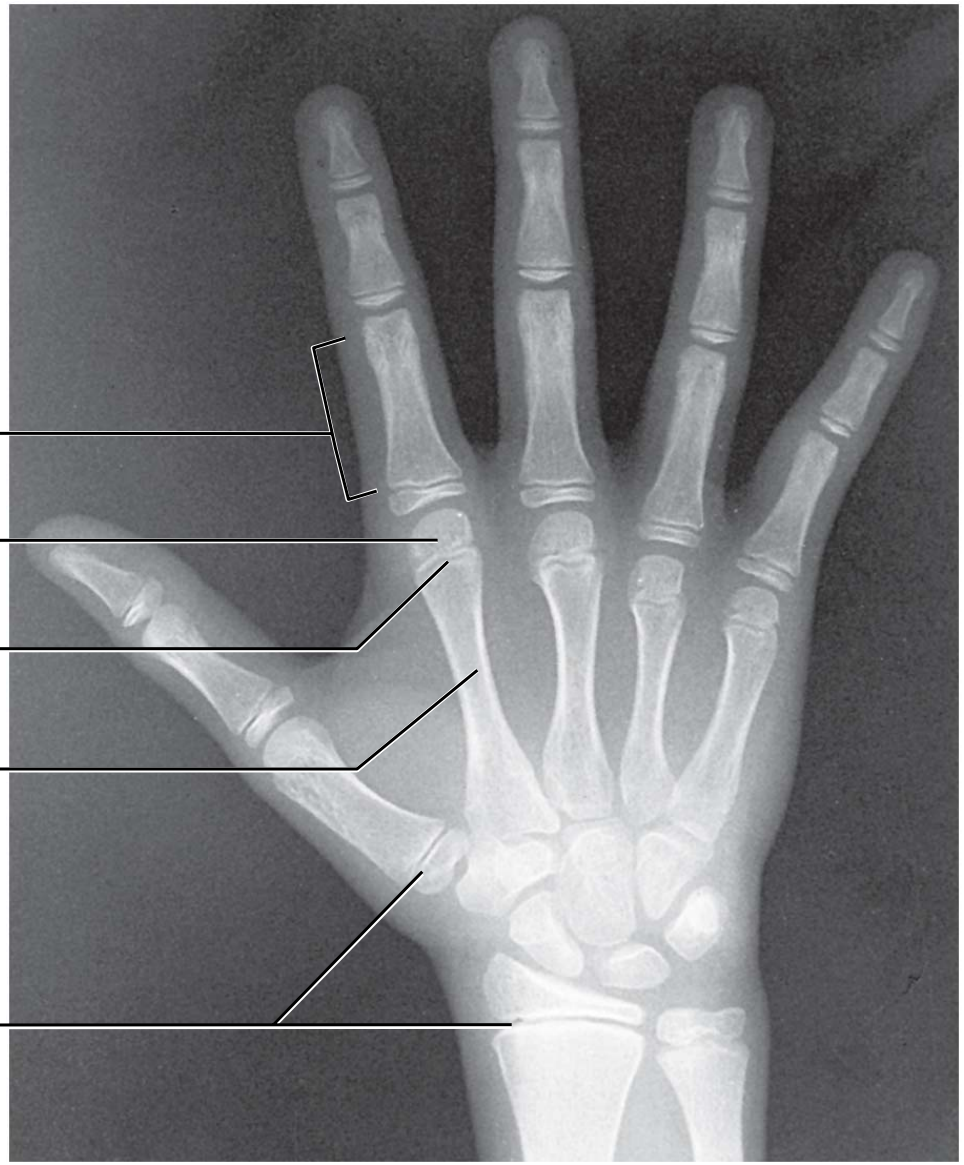

Bone Growth and Remodeling After Birth

- ossification continues throughout life with the growth and remodeling of bones
  - bones grow in two directions
    - length (interstitial) – stops in early 20's
    - width (appositional) – continues throughout
  - elongation occurs at ephyseal plate
  - after it closes, bone can still remodel itself by changing the width and/or shape of long bones

Bone Growth and Remodeling After Birth

- interstitial growth = bone elongation
  - epiphyseal plate – a region of transition from cartilage to bone
    - functions as growth zone where the bones elongate
    - consists of typical hyaline cartilage in the middle
    - with a transition zone on each side where cartilage is being replaced by bone
    - metaphysis is the zone of transition <u>facing the marrow cavity</u>

Bone Growth and Remodeling After Birth

- interstitial growth
  - bones increase in length
  - bone elongation is really a result of cartilage growth within epiphyseal plate
  - epiphyses close when cartilage is gone forming the epiphyseal line
  - length-wise growth is completed // occurs at different ages in different bones

Zones of the Metaphysis

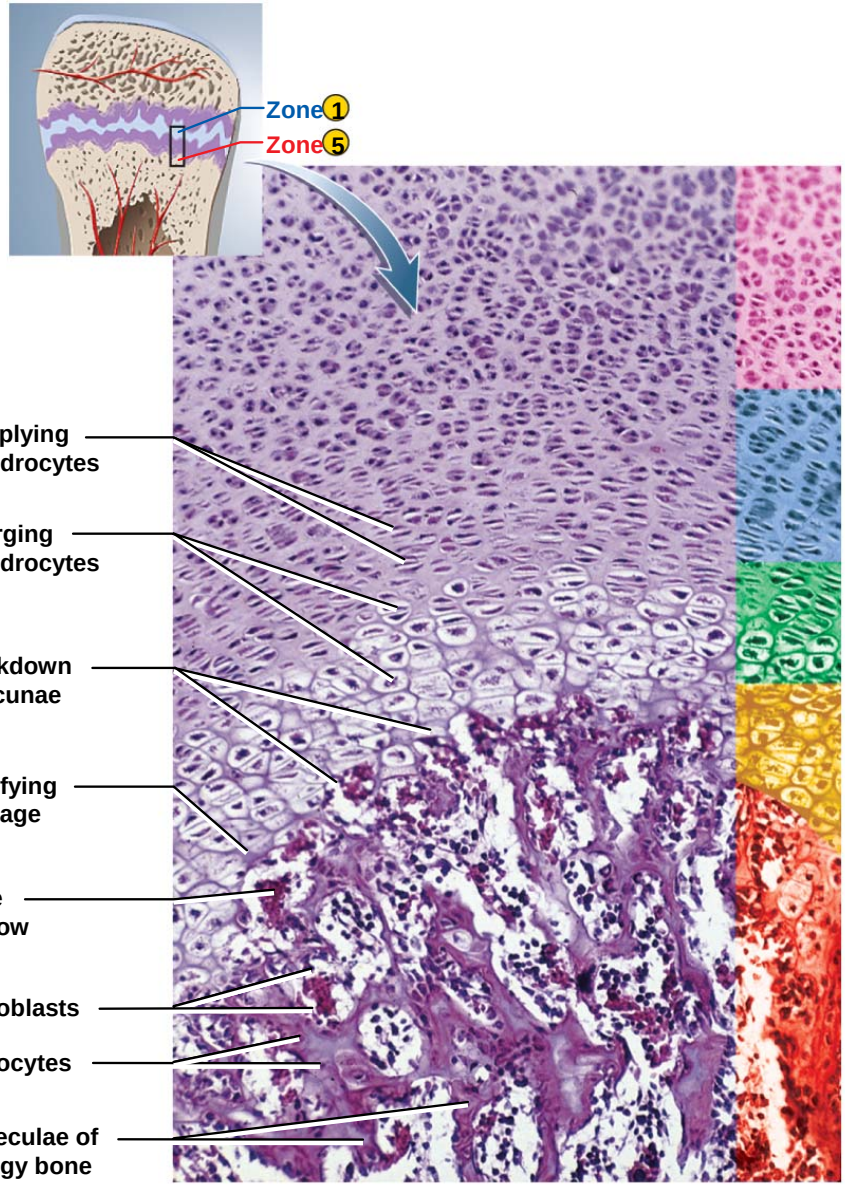

Victor Eroschenko

1. **Zone of reserve cartilage**
   Typical histology of resting hyaline cartilage
2. **Zone of cell proliferation**
   Chondrocytes multiplying and lining up in rows of small flattened lacunae
3. **Zone of cell hypertrophy**
   Cessation of mitosis; enlargement of chondrocytes and thinning of lacuna walls
4. **Zone of calcification**
   Temporary calcification of cartilage matrix between columns of lacunae
5. **Zone of bone deposition**
   Breakdown of lacuna walls, leaving open channels; death of chondrocytes; bone deposition by osteoblasts, forming trabeculae of spongy bone

Bone Growth and Remodeling After Birth

- **Appositional Growth**
  - bones increase in width throughout life
  - the deposition of new bone at the surface
  - osteoblasts on deep side of periosteum deposit osteoid tissue / become trapped as tissue calcifies
  - circumferential lamellae = matrix in layers parallel to surface
    - forms over surface
    - osteoclasts under endosteum enlarge marrow cavity

Bone Growth and Remodeling

- **Bone remodeling** occurs throughout life - 10% per year
  - repairs microfractures, releases minerals into blood, reshapes bones in response to use and disuse
  - **Wolff's Law of Bone**
    - architecture of bone determined by mechanical stresses placed on it and bones adapt to withstand those stresses
    - remodeling is a collaborative and precise action of osteoblasts and osteoclasts
    - bony processes grow larger in response to mechanical stress

Dwarfism

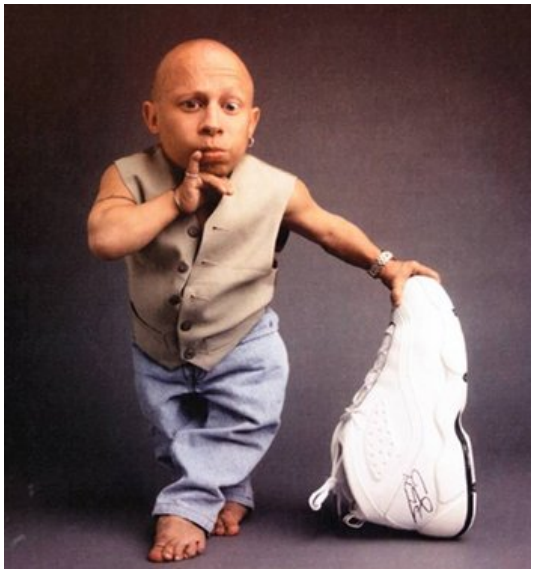

- **Achondroplastic dwarfism**
  - long bones stop growing in childhood // normal torso, short limbs / more common
  - failure of cartilage growth in metaphysis
  - spontaneous mutation produces mutant dominant allele
- **Pituitary dwarfism**
  - lack of growth hormone
  - normal proportions with short stature

Chapter 6

Bone Fracture & Repair

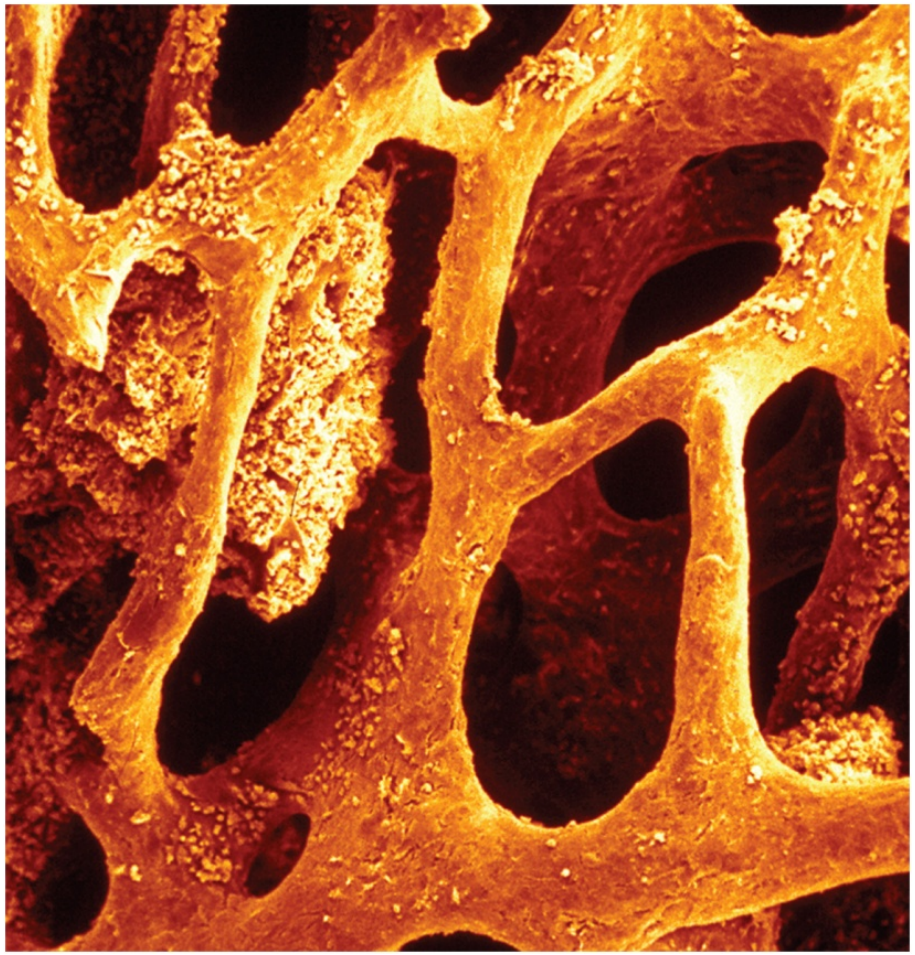

Fractures and Their Repair

- **stress fracture** – break caused by abnormal trauma to a bone
  - falls, athletics, and military combat

- **pathological fracture** – break in a bone weakened by some other disease
  - bone cancer or osteoporosis
  - usually caused by stress that would not break a healthy bone

- **fractures** classified by structural characteristics
  - direction of fracture line
  - break in the skin
  - multiple pieces

- uncomplicated fractures
  - normally take 8 - 12 weeks to heal
  - longer in elderly

Stages in Healing of Fractures

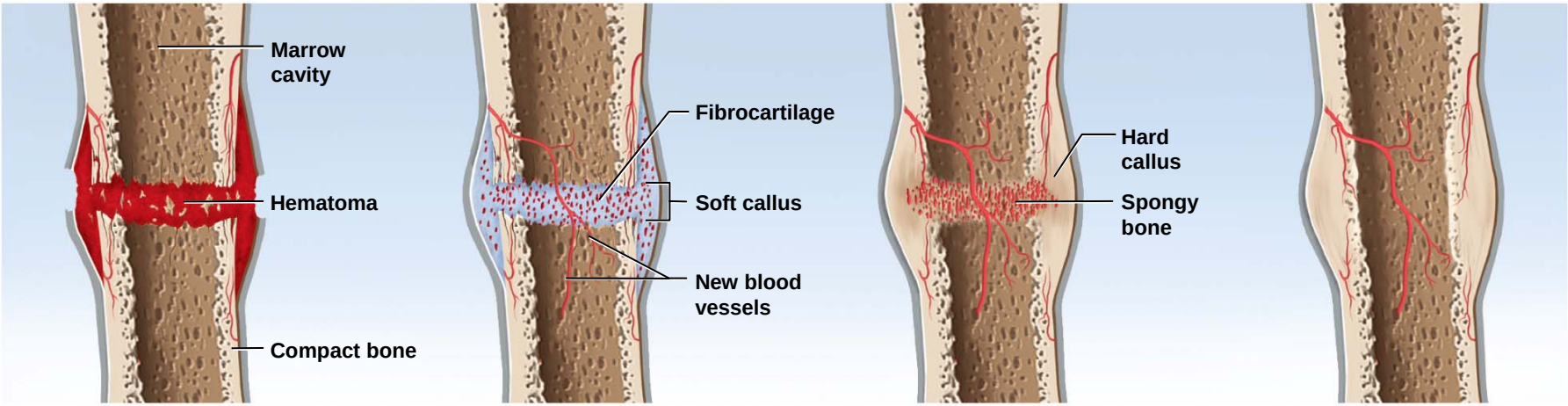

1 **Hematoma formation**
The hematoma is converted to granulation tissue by invasion of cells and blood capillaries.

2 **Soft callus formation**
Deposition of collagen and fibrocartilage converts granulation tissue to a soft callus.

3 **Hard callus formation**
Osteoblasts deposit a temporary bony collar around the fracture to unite the broken pieces while ossification occurs.

4 **Bone remodeling**
Small bone fragments are removed by osteoclasts, while osteoblasts deposit spongy bone and then convert it to compact bone.

Stages of Healing Bone Fractures (#1)

– Fracture results in hematoma followed by development of granulation tissue

- bleeding of a broken bone forms a clot – fracture hematoma // immune cells like neutrophils and macrophage enter area
- granulation tissue – soft fibrous mass is produced includes new capillary networks growing into hematoma
- cellular invasion // <u>after about 48 hours</u> after injury // chondrocytes enter area
- fibroblasts, osteoclasts, and osteogenic cells follow chondroblast enter area to further deveop granulation tissue

Stages of Healing Bone Fractures (#2)

- Soft callus formation
  - formed by fibroblasts and chondroblasts depositing collagen and fibrocartilage into granulation tissue

Stages of Healing Bone Fractures (#3)

– Conversion to hard callus

- osteoblasts produce a bony collar in 6 weeks called a hard callus
- hard callus is cemented to dead bone around the injury site and acts as a temporary splint to join broken ends together
- 4 - 6 weeks for hard callus to form and immobilization is necessary

Stages of Healing Bone Fractures (#4)

– Remodeling

- hard callus persists for 3 – 4 months
- osteoclasts dissolve fragments of broken bone
- osteoblasts deposit spongy bone to bridge to gap between the broken ends, transformed gradually into compact bone that is thicker in fracture area

– ***Note: Vitamin A, vitamin C, and vitamin D are*** *required nutritional factors for growth and repair*

Healing of Fractures

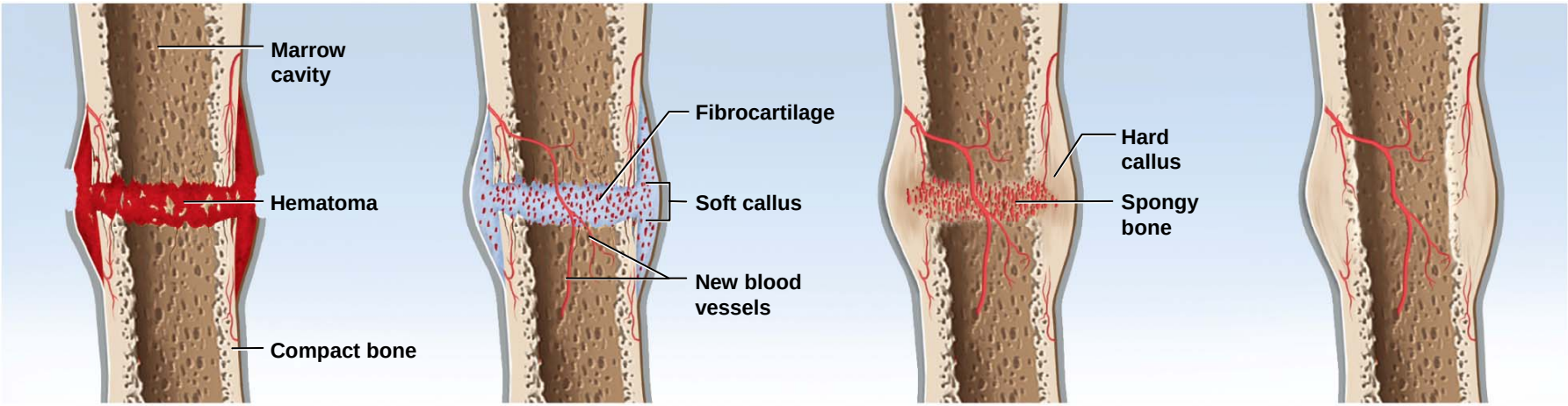

1 **Hematoma formation**
The hematoma is converted to granulation tissue by invasion of cells and blood capillaries.

2 **Soft callus formation**
Deposition of collagen and fibrocartilage converts granulation tissue to a soft callus.

3 **Hard callus formation**
Osteoblasts deposit a temporary bony collar around the fracture to unite the broken pieces while ossification occurs.

4 **Bone remodeling**
Small bone fragments are removed by osteoclasts, while osteoblasts deposit spongy bone and then convert it to compact bone.

Treatment of Fractures

- **closed reduction**
  - procedure in which the bone fragments are manipulated into their normal positions without surgery
- **open reduction**
  - involves surgical exposure of the bone and the use of plates, screws, or pins to realign the fragments

Treatment of Fractures

- cast – normally used to stabilize and immobilize healing bone
- electrical stimulation accelerates repair // suppresses the effects of parathyroid hormone
- orthopedics – the branch of medicine that deals with prevention and correction of injuries and disorders of the bones, joints, and muscles

Treatment of Fractures

- traction used to treat fractures of the femur in children
  - aligns bone fragments by overriding force of the strong thigh muscles
  - risks long-term confinement to bed
  - rarely used for the elderly
  - hip fractures are usually pinned in elderly and early ambulation (walking) is encouraged to promote blood circulation and healing

Types of Bone Fractures

(a) Nondisplaced

(c) Comminuted

(d) Greenstick

X-Ray of Fractures and Their Repairs