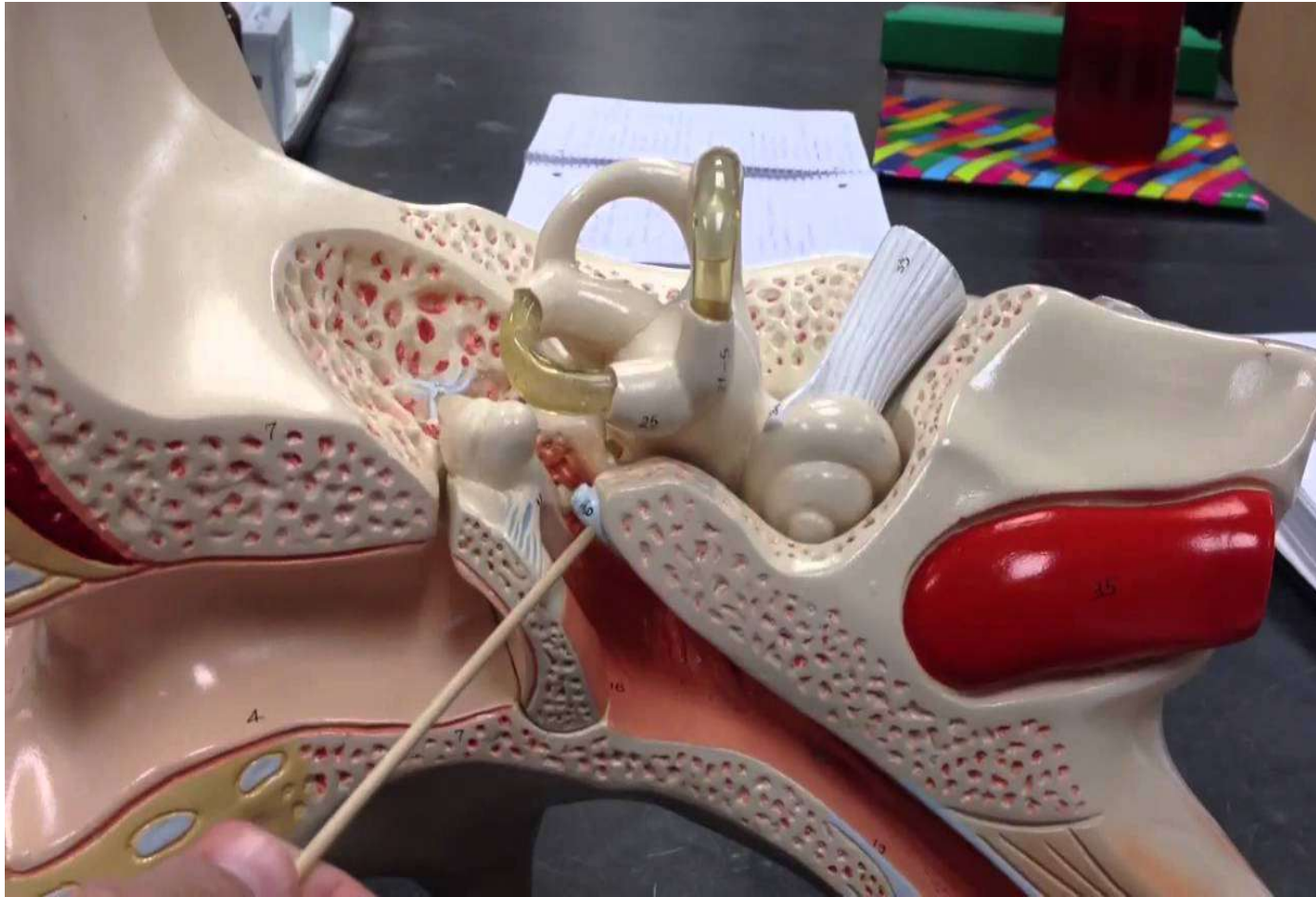
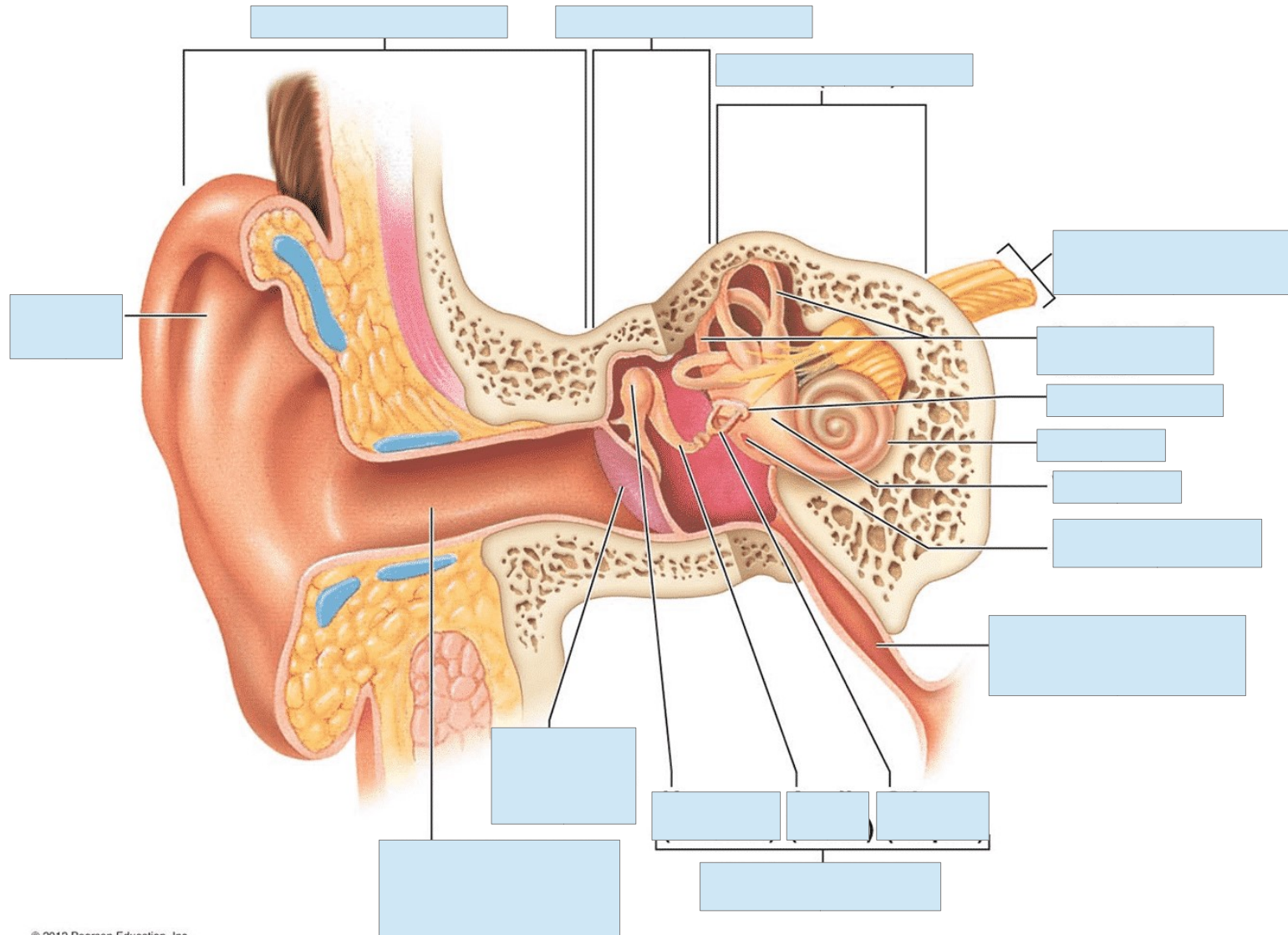


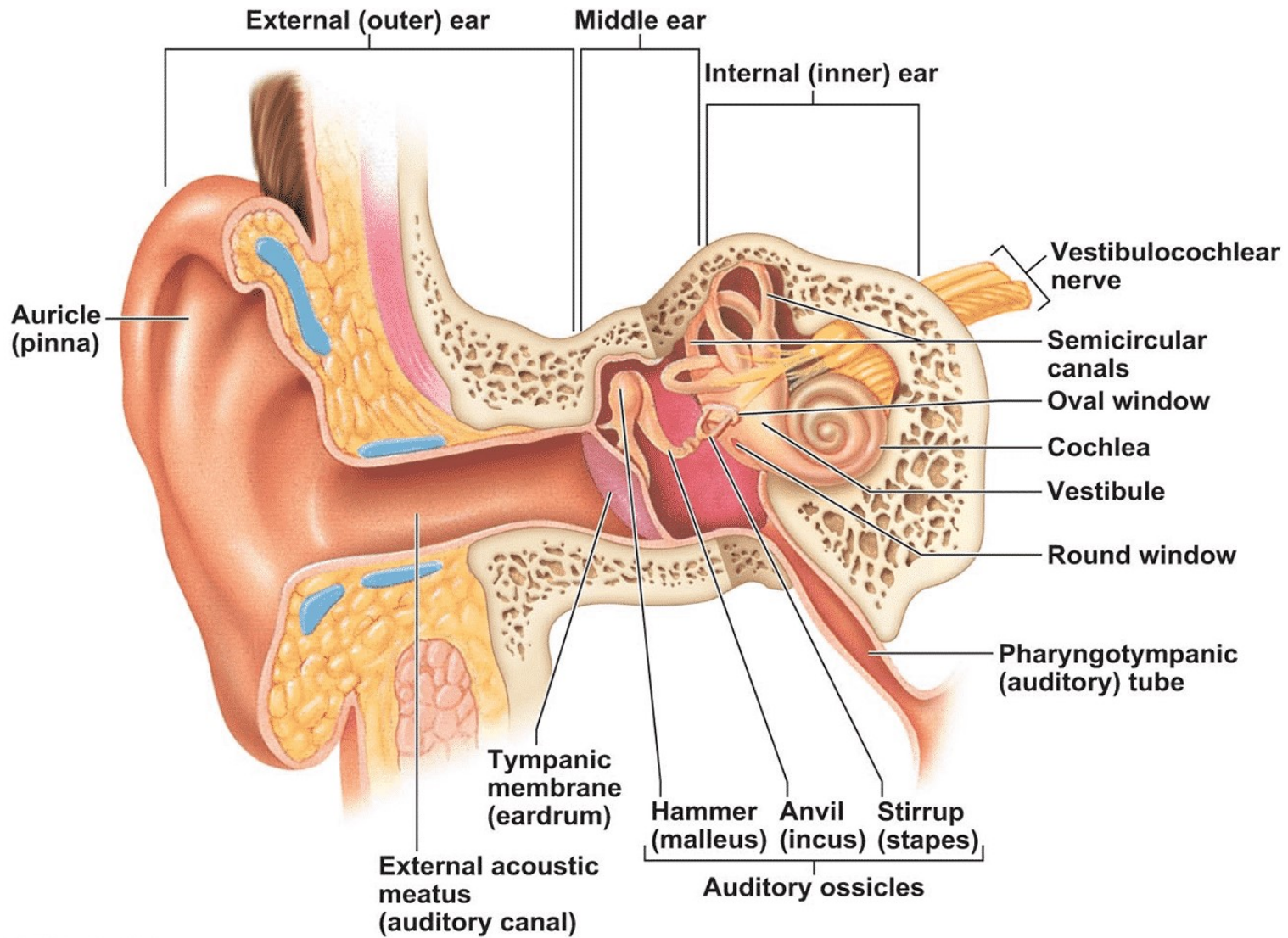
Anatomy of the Ear

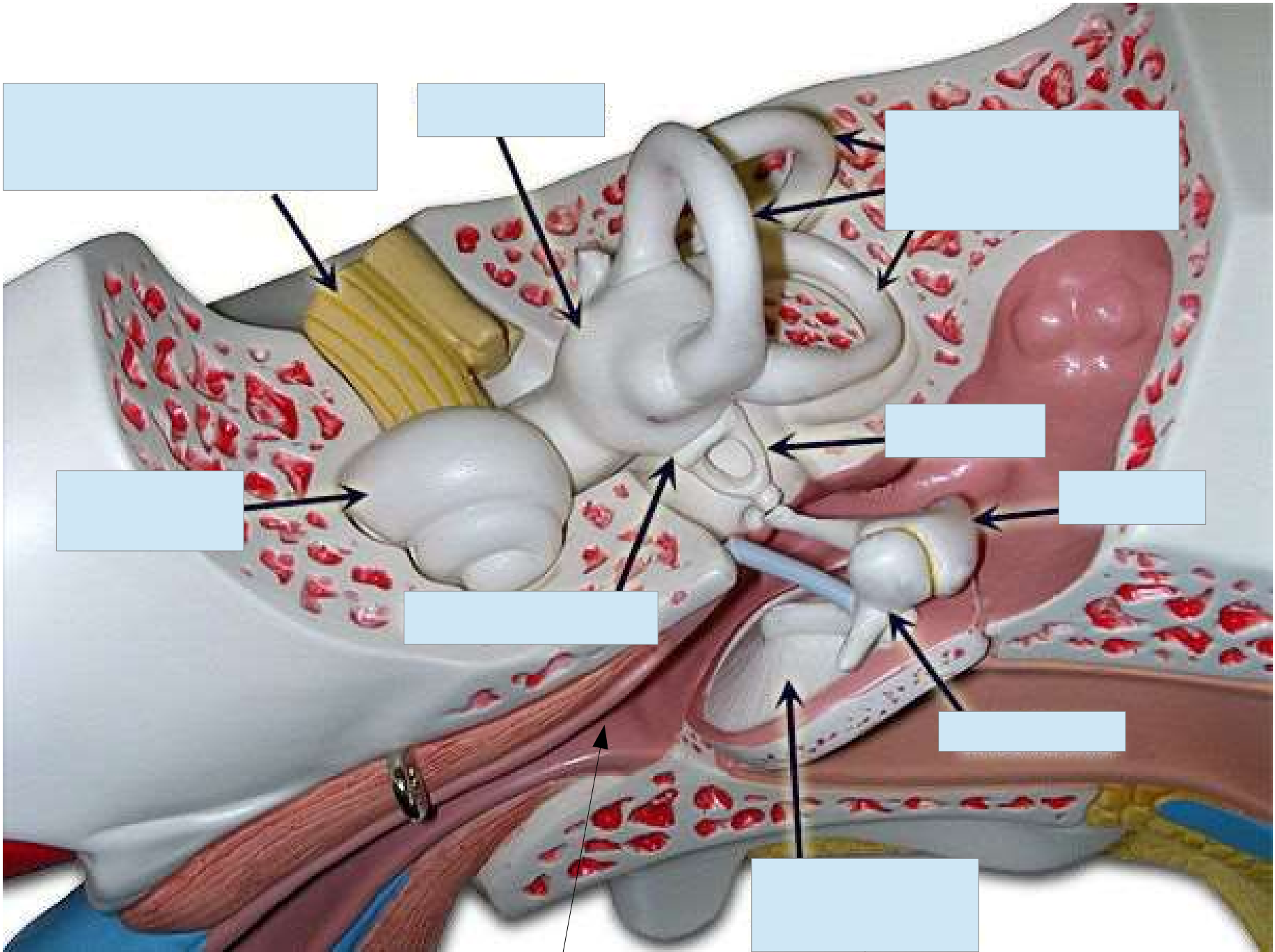


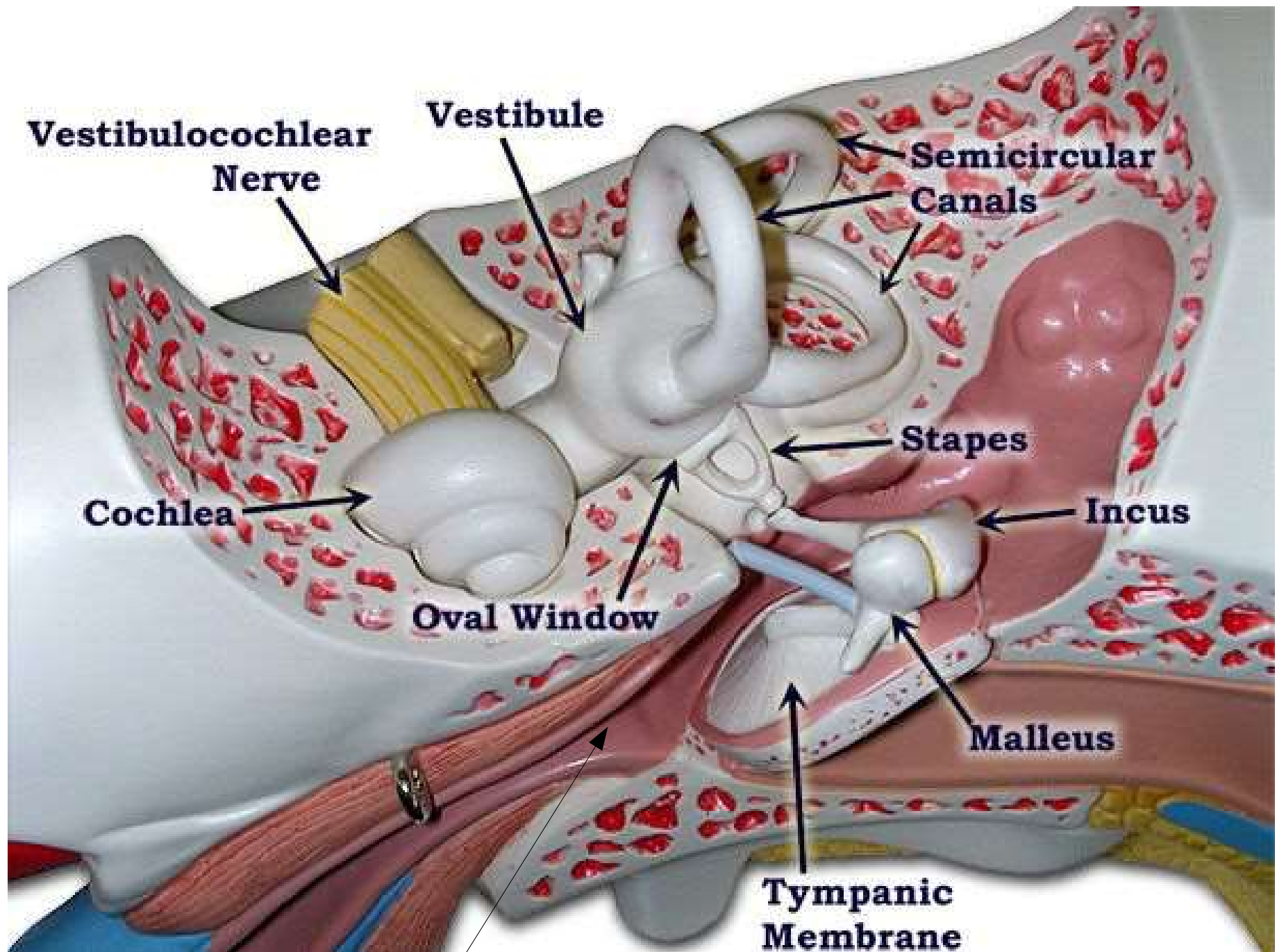
Anatomy of the Ear



Anatomy of the Ear







Vestibulocochlear Nerve

Vestibule

Semicircular Canals

Cochlea

Oval Window

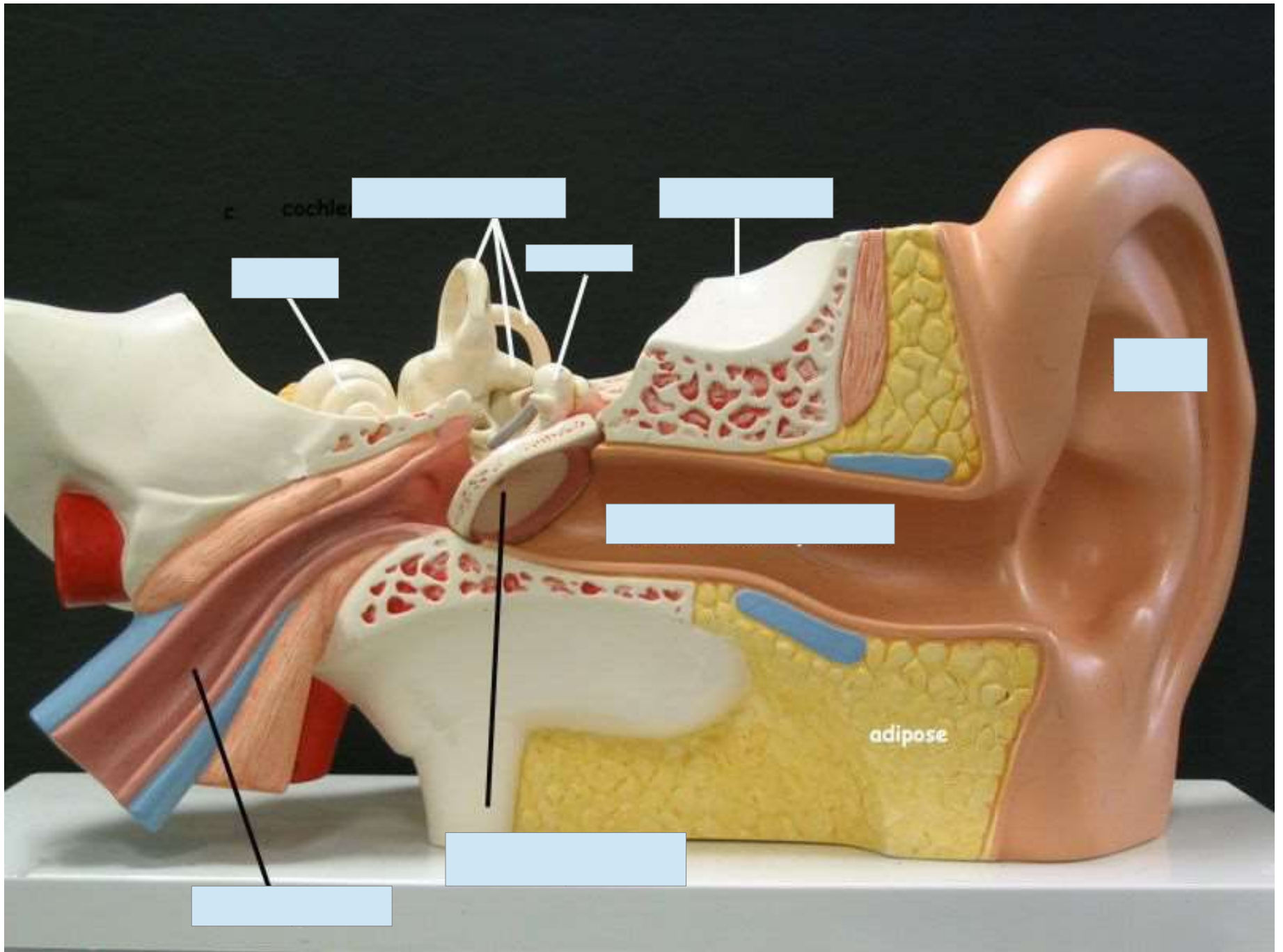
Stapes

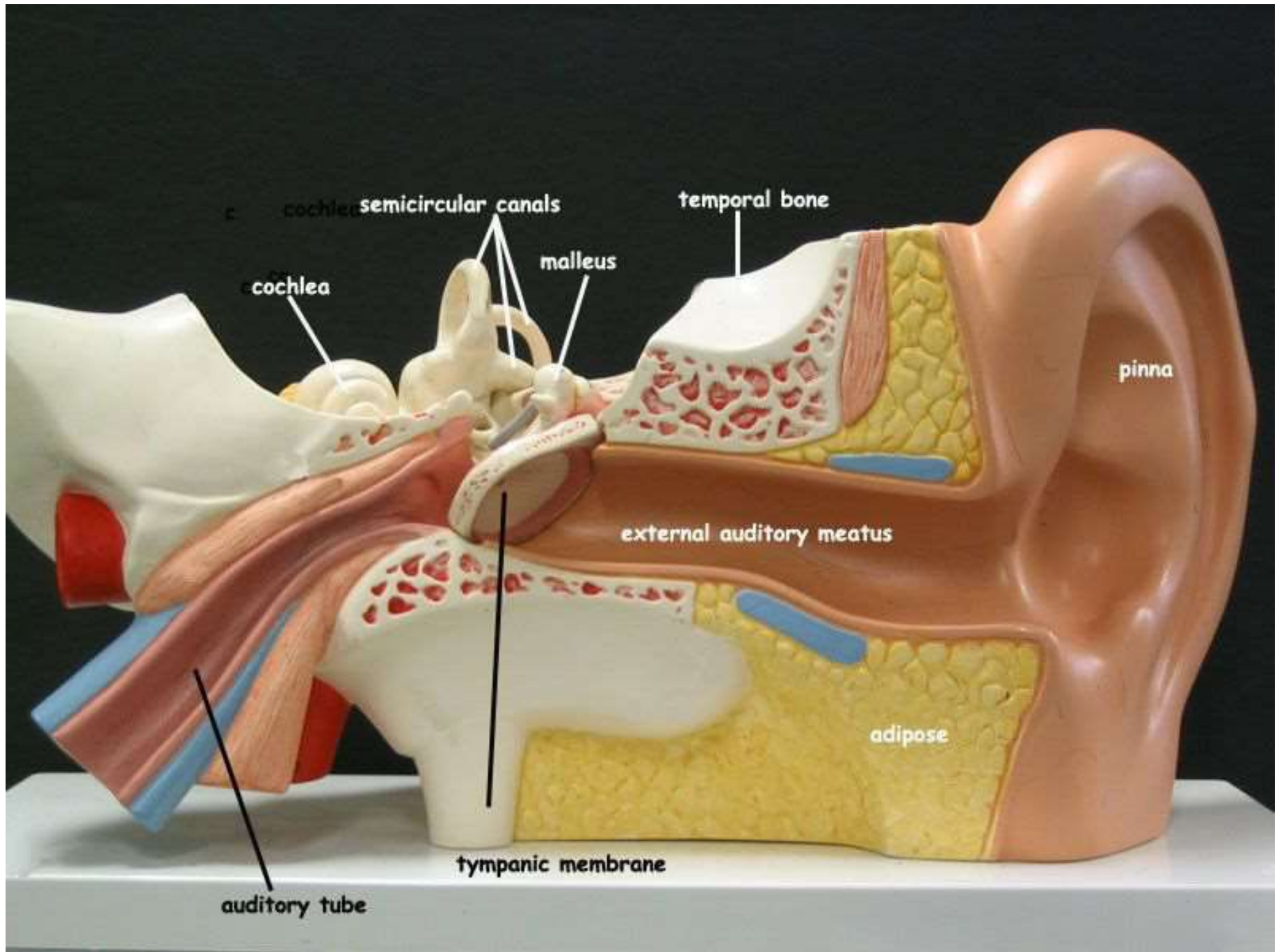
Incus

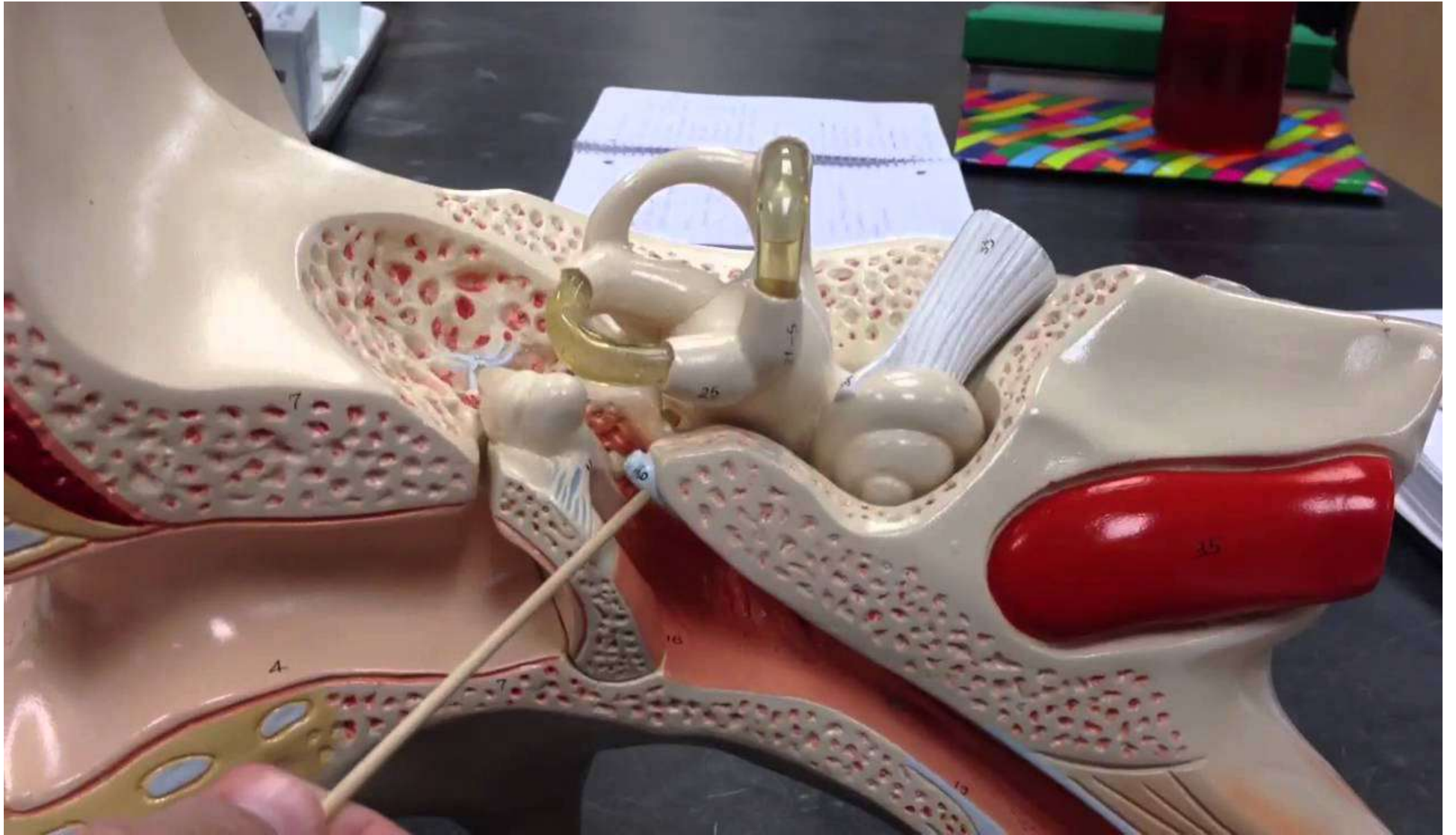Malleus


Tympanic Membrane

Auditory Tube

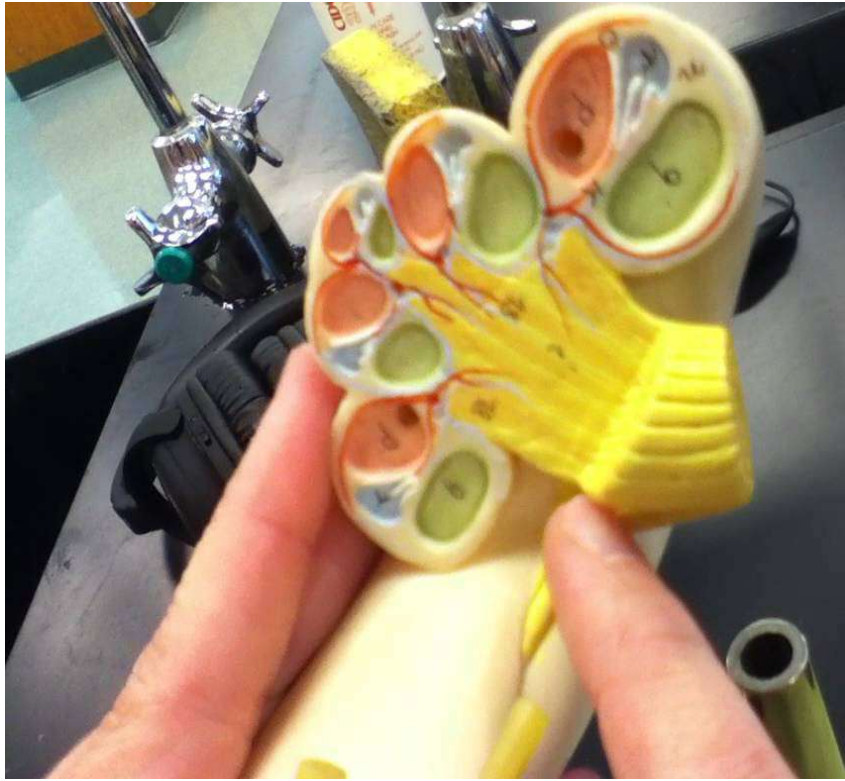




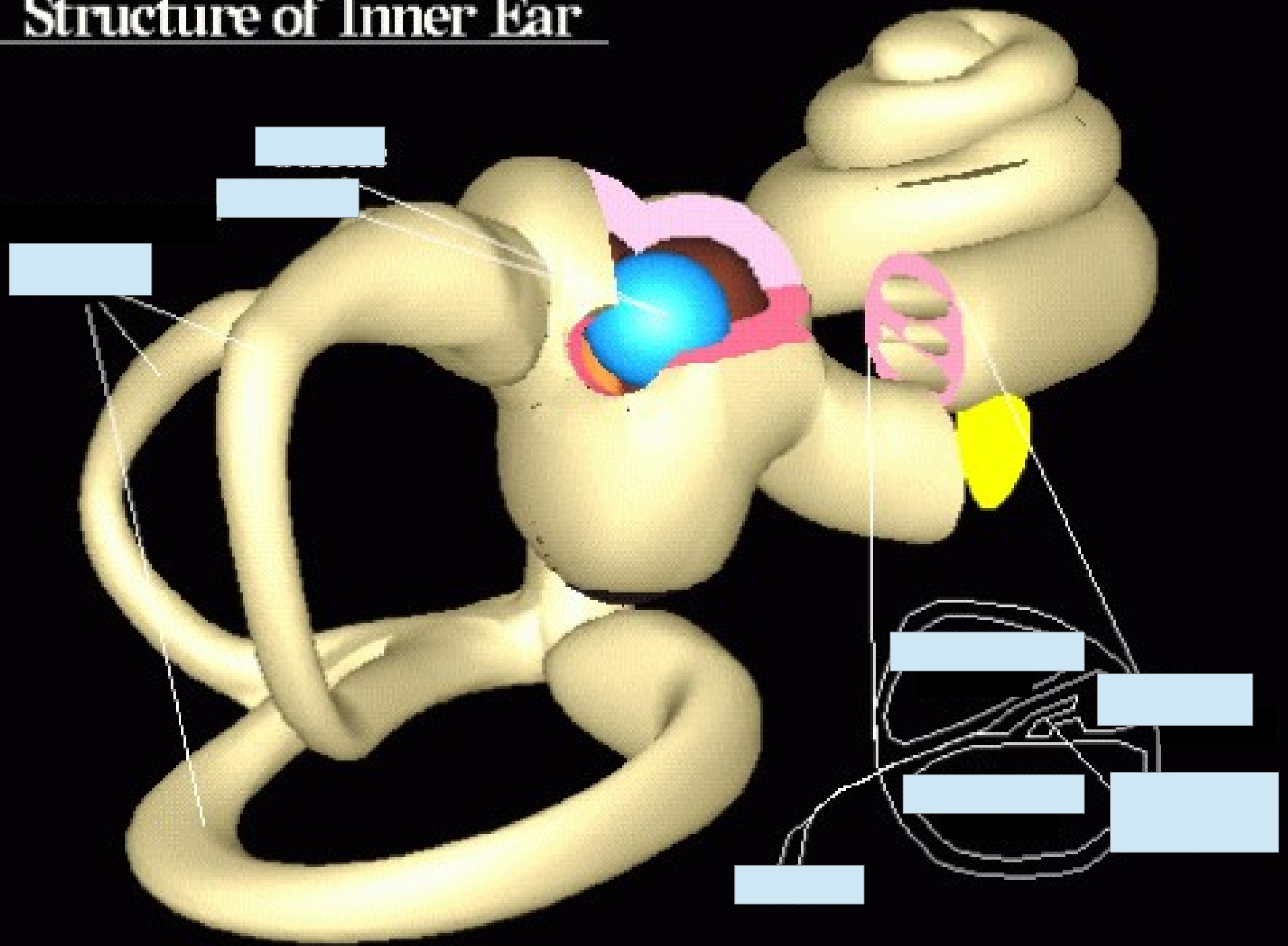




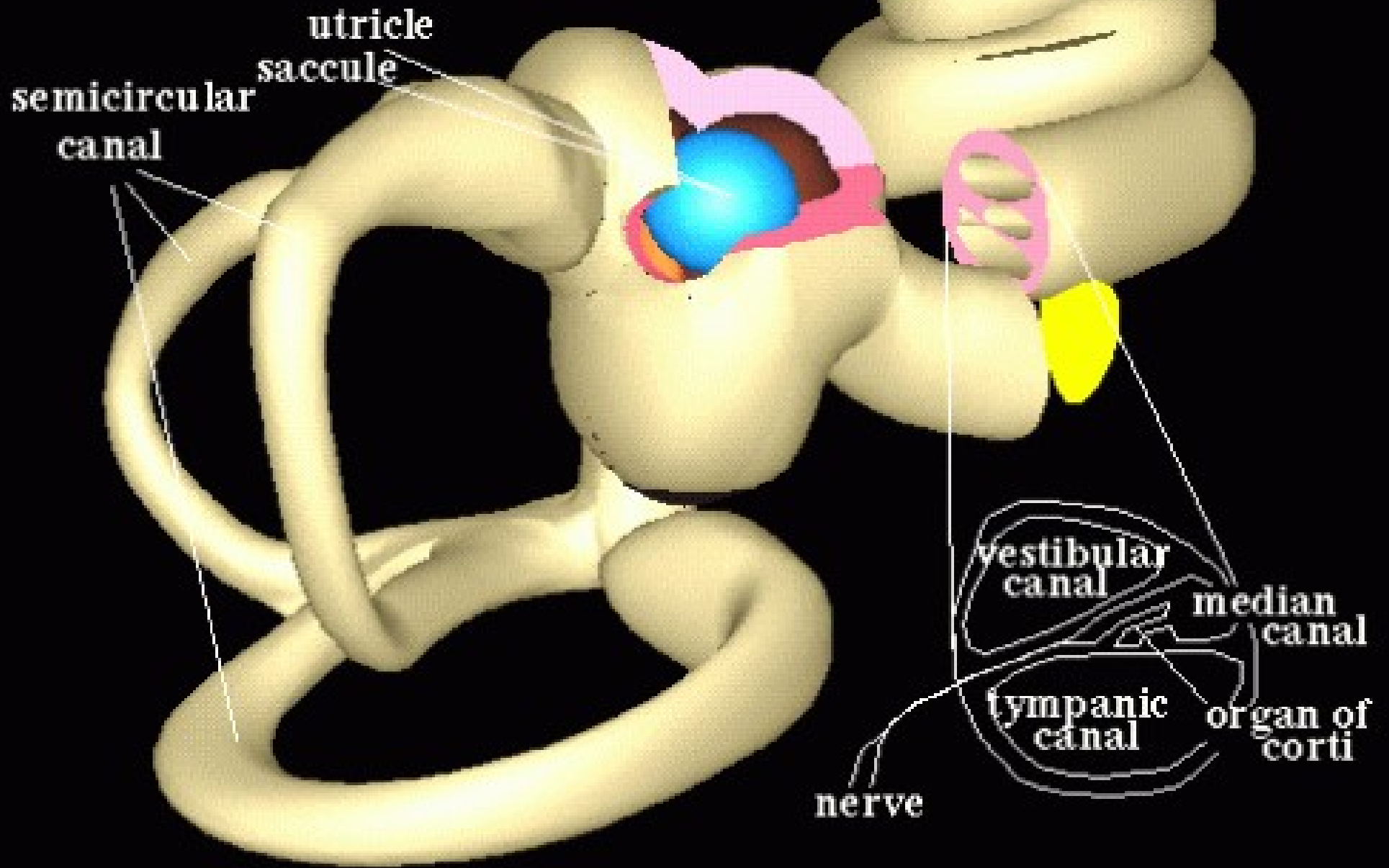


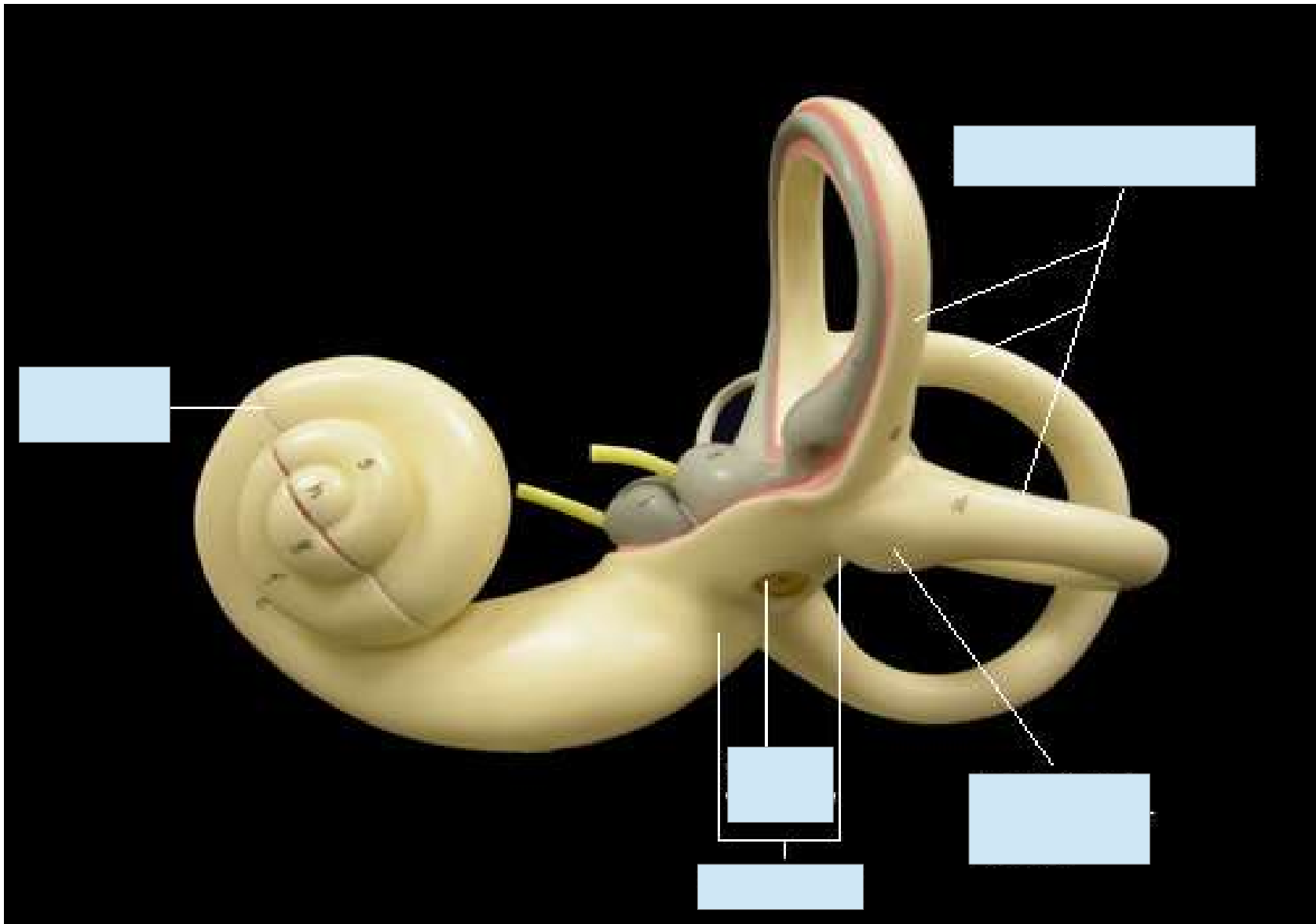


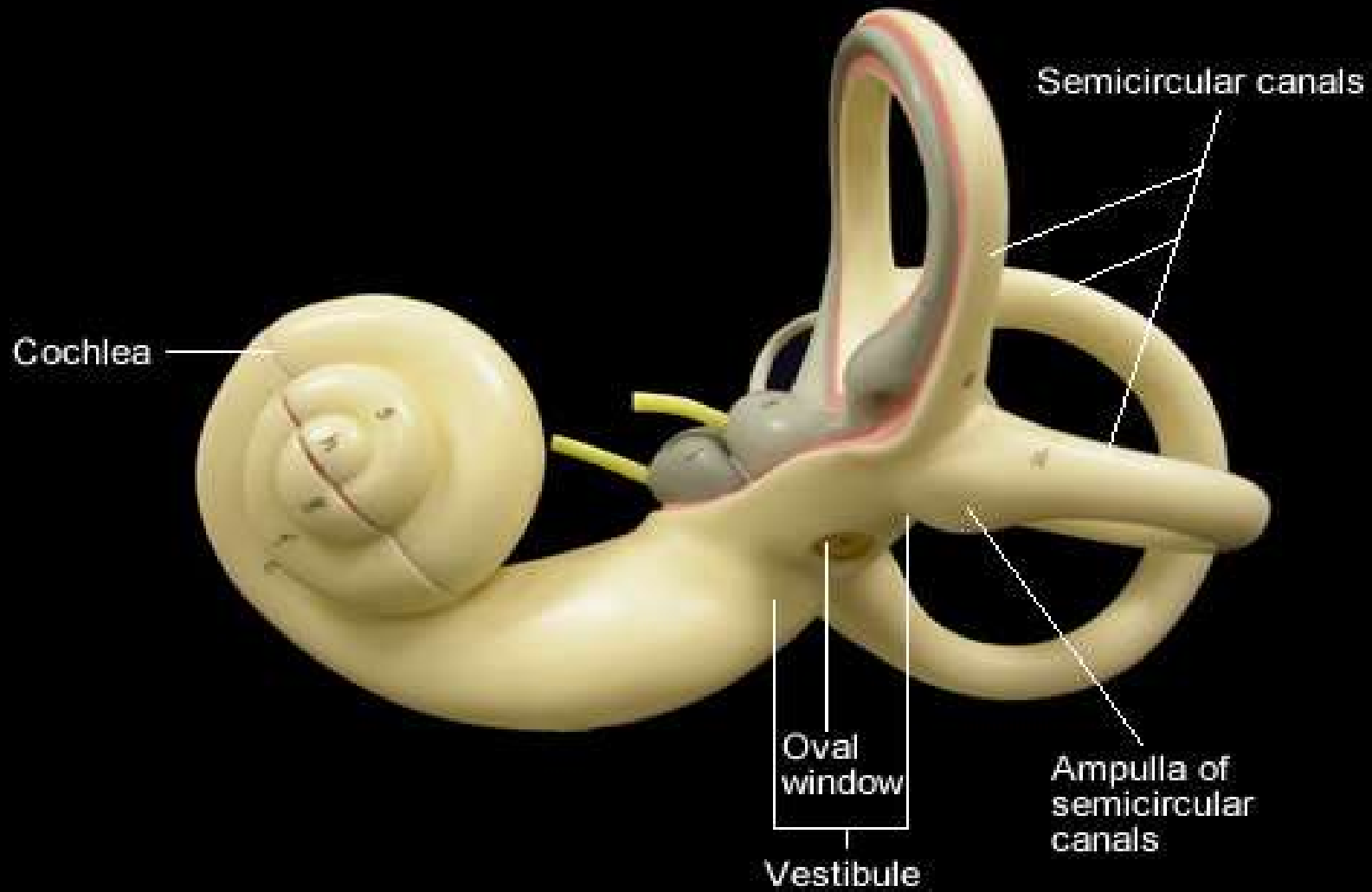
Structure of Inner Ear



Structure of Inner Ear



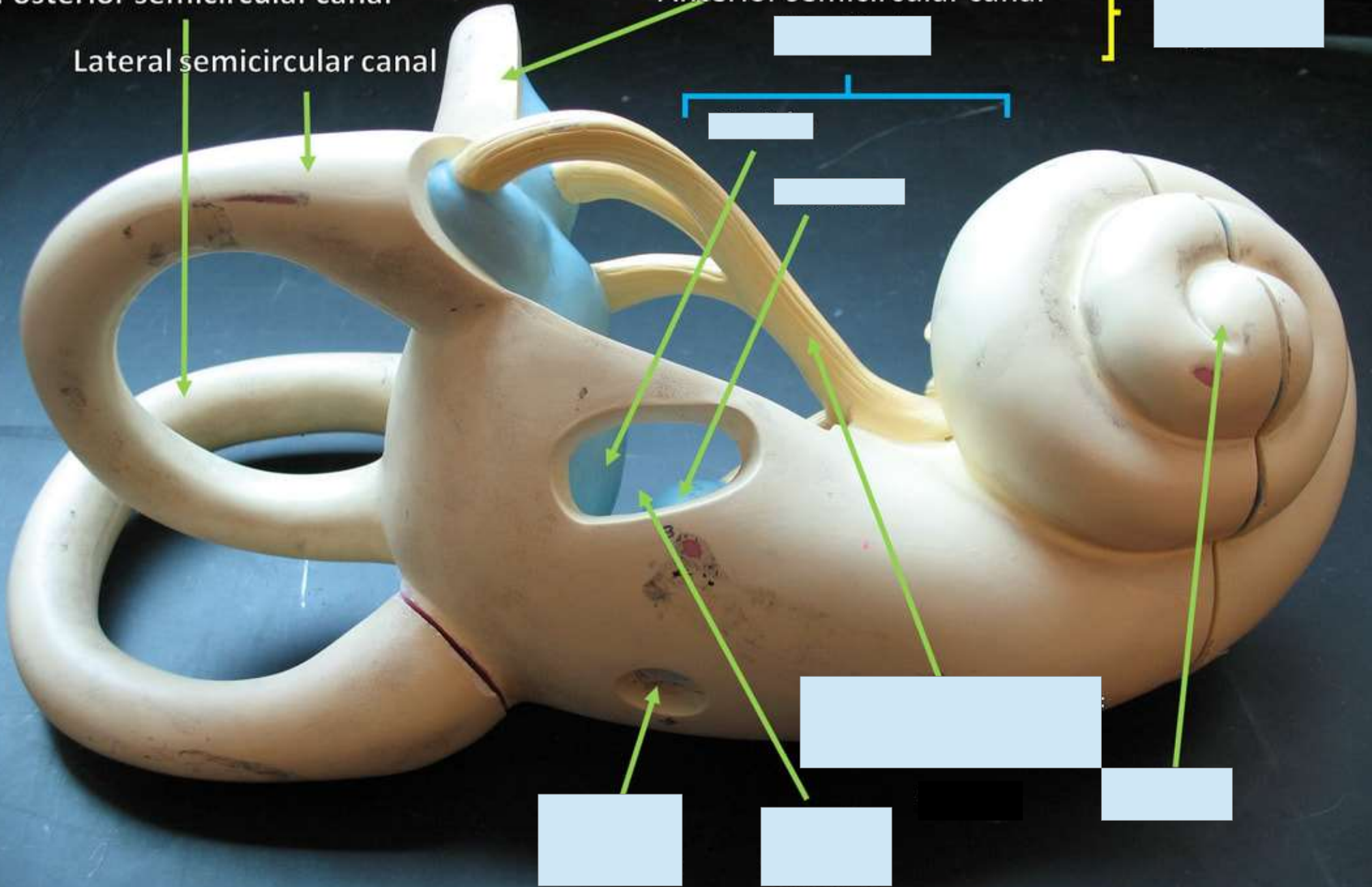




Posterior semicircular canal

Anterior semicircular canal

Lateral semicircular canal



Posterior semicircular canal

Anterior semicircular canal
Vestibule

Vestibular apparatus

Lateral semicircular canal

Utricle

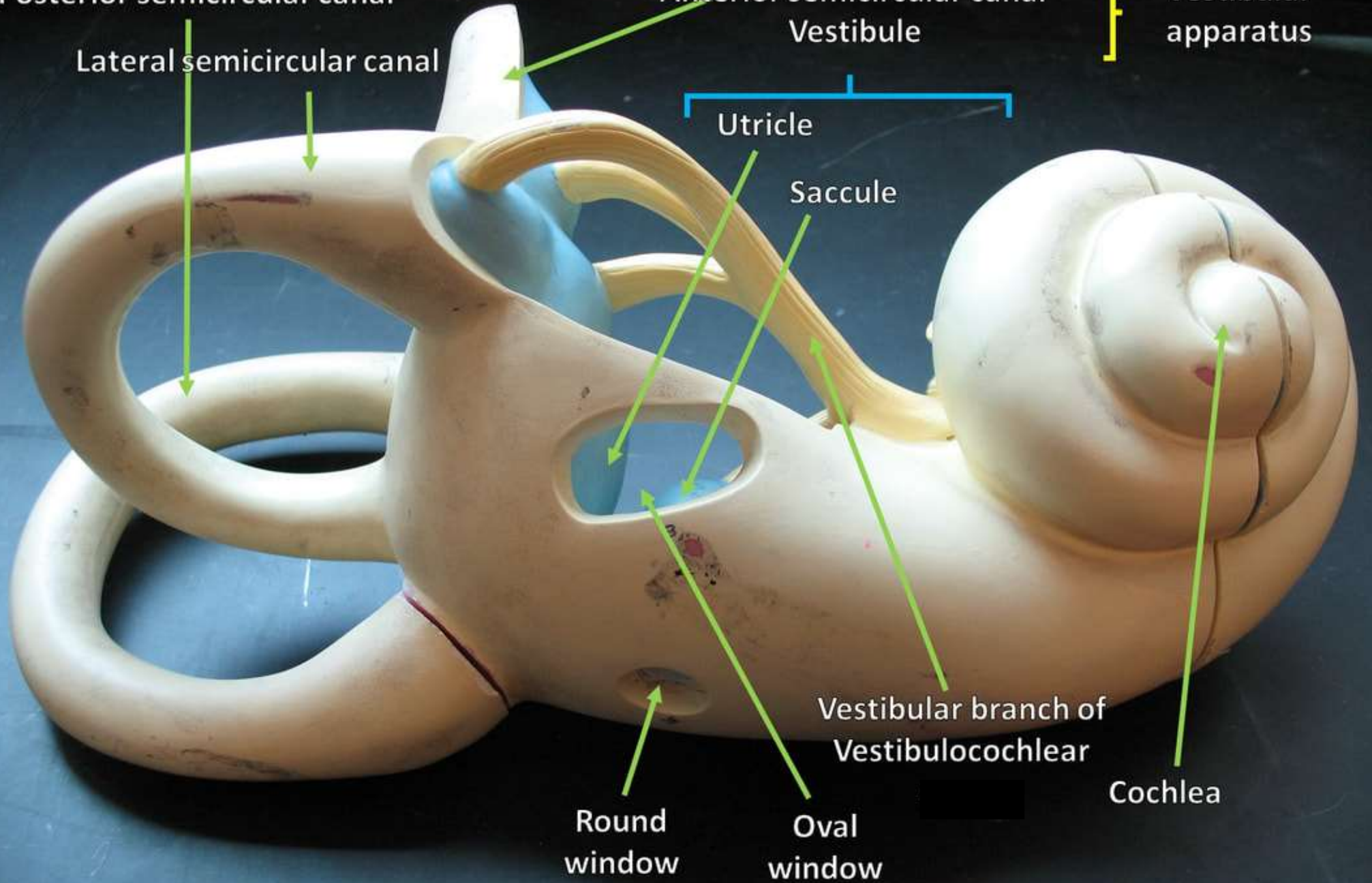
Sacculle

Vestibular branch of
Vestibulocochlear

Cochlea

Round
window

Oval
window

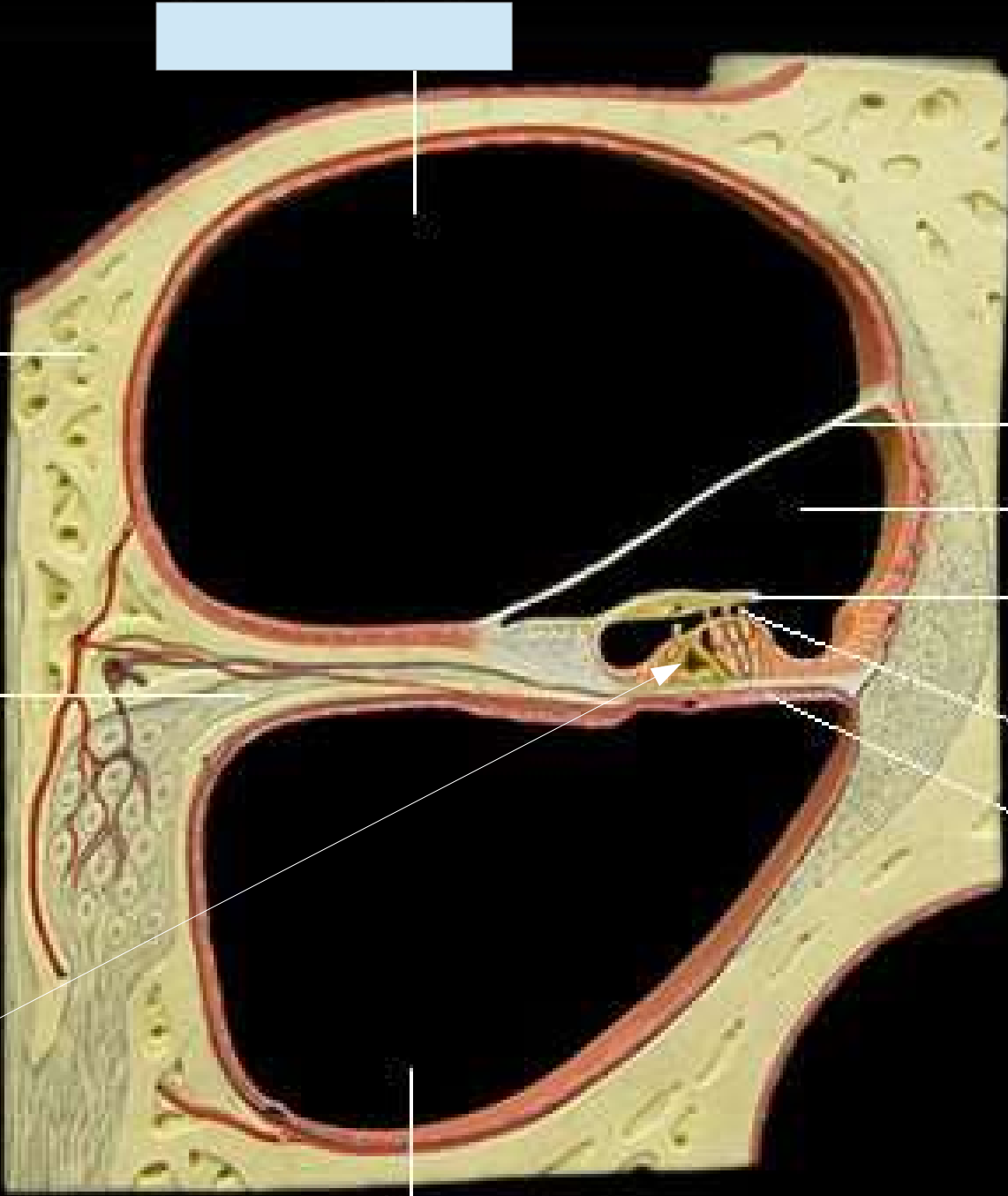


[Redacted label]

[Redacted label]

[Redacted label]

[Redacted label]



[Redacted label]

[Redacted label]

[Redacted label]

[Redacted label]

[Redacted label]

[Redacted label]

Scala vestibuli

Bony substance of cochlea

Vestibular membrane

Cochlear duct

Tectorial membrane

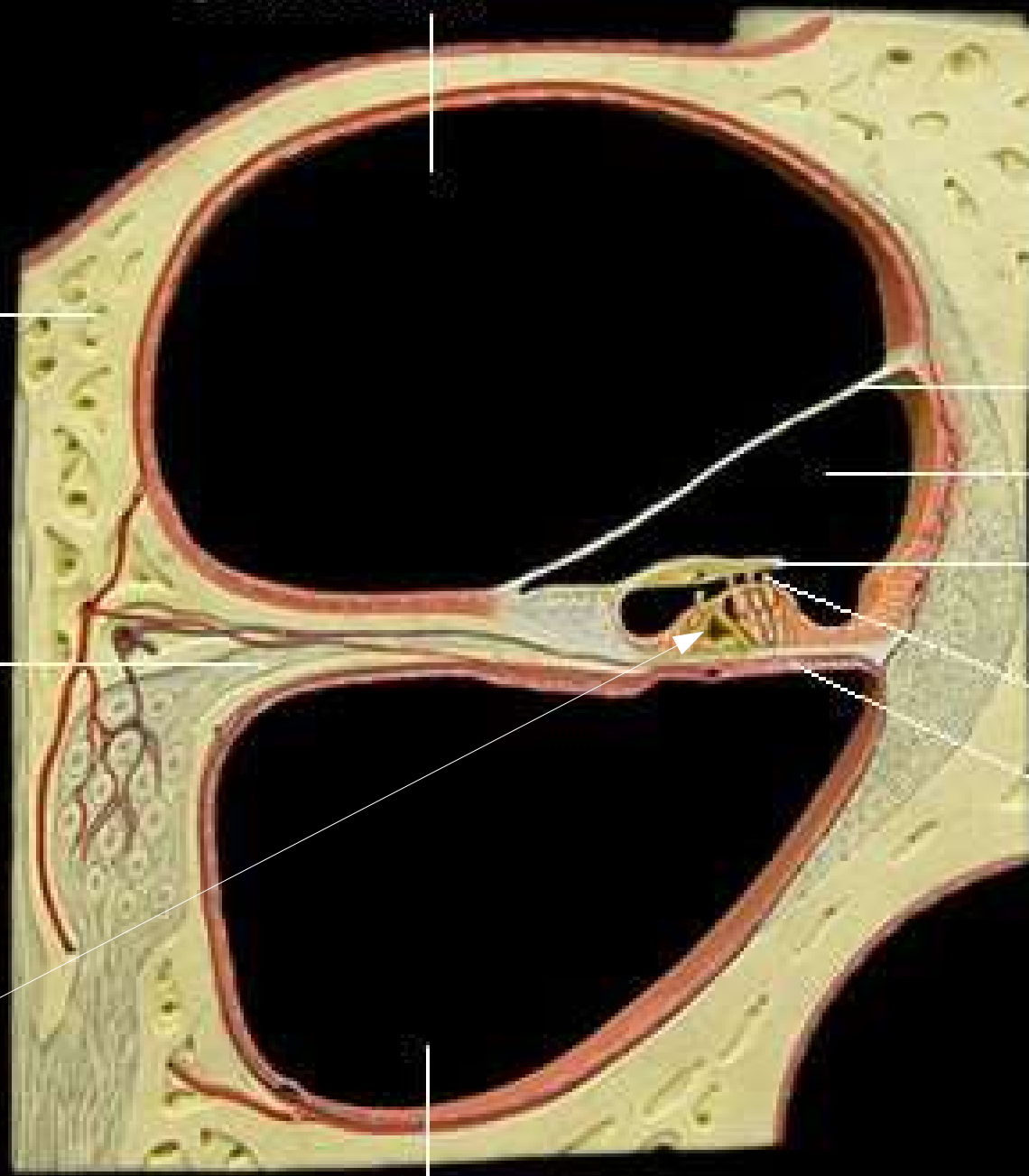
Cochlear nerve

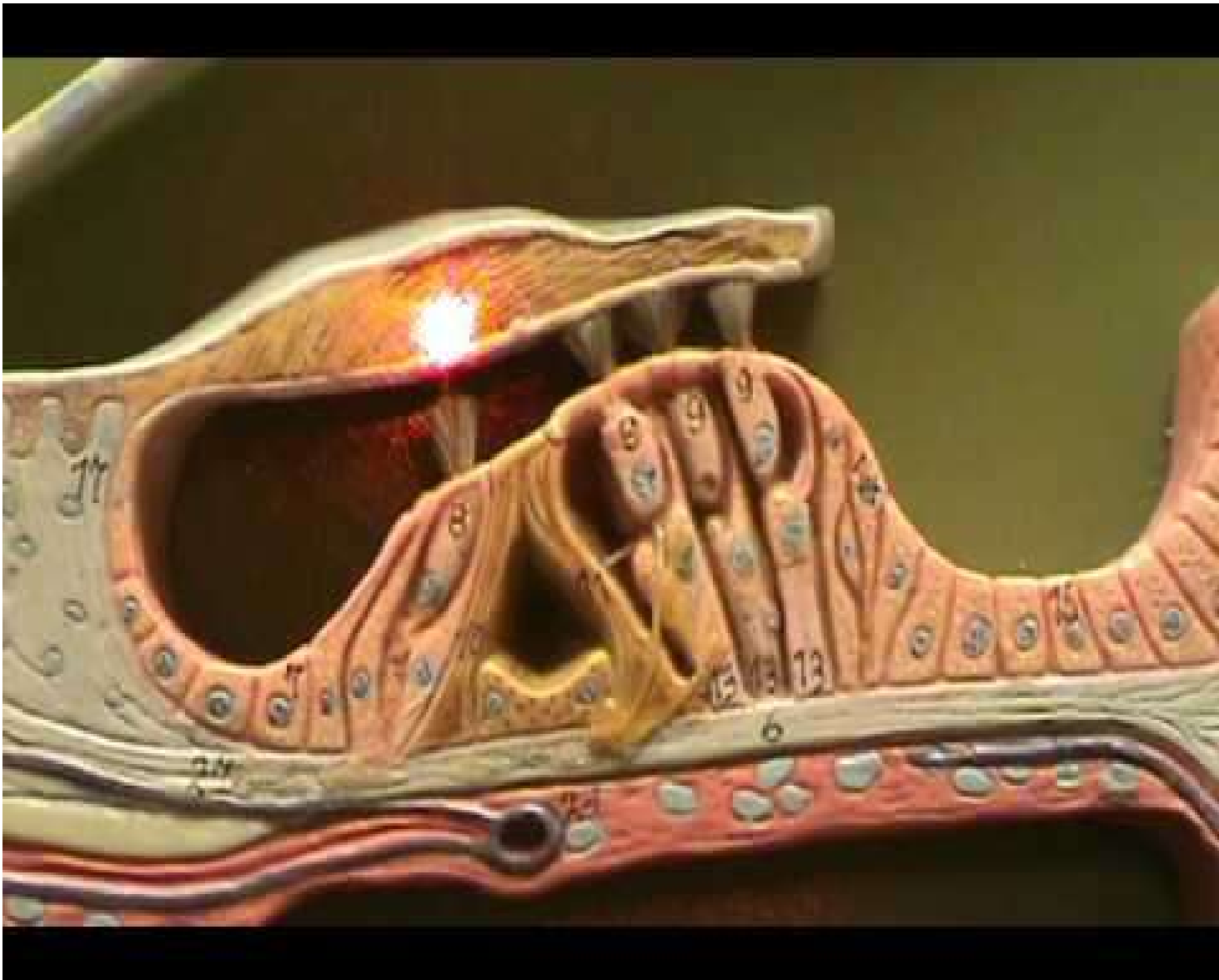Hair cells

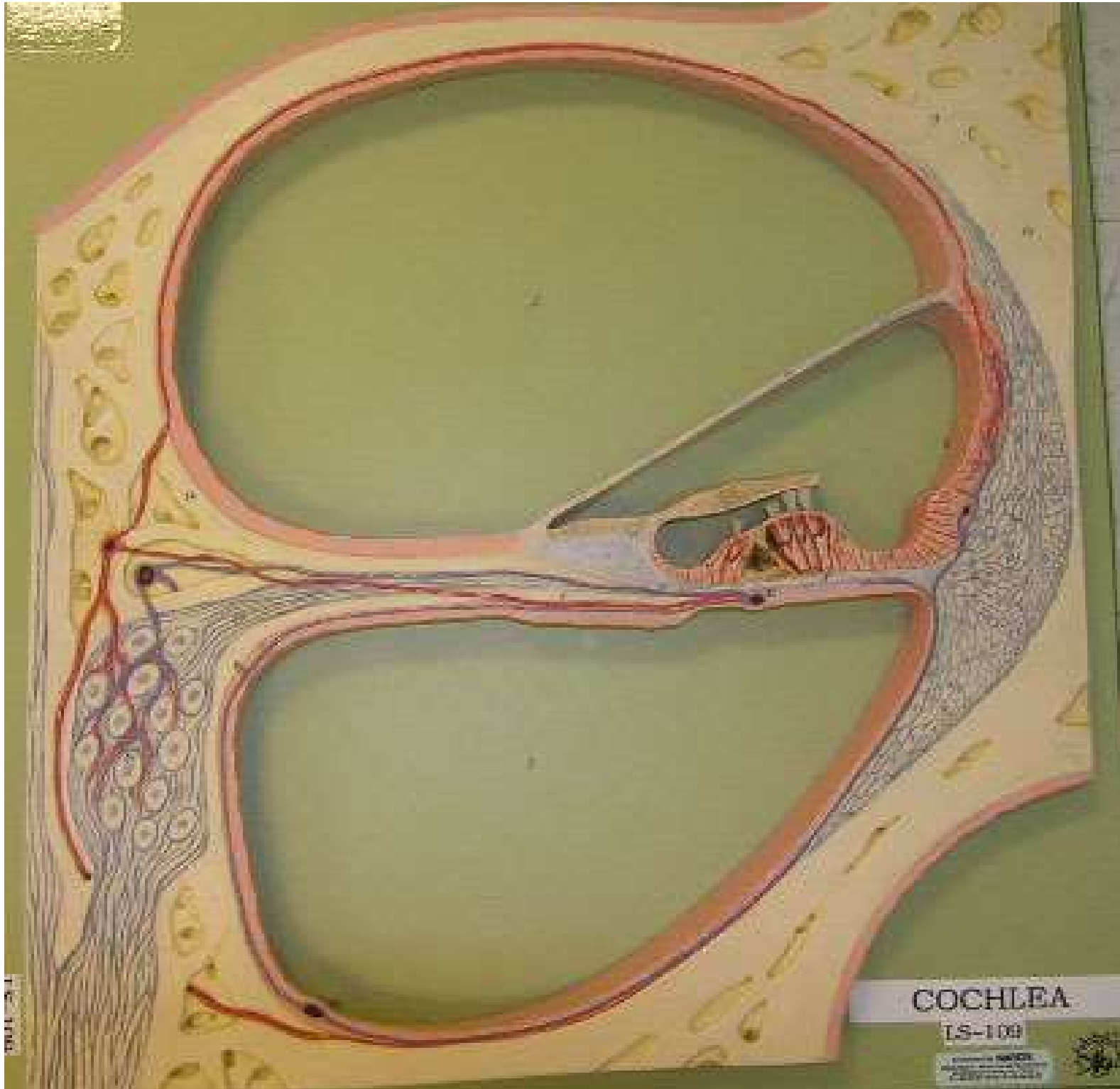
Basilar membrane

Organ of Corti

Scala tympani







COCHLEA

LS-100

© 1998 by
Lippincott Williams & Wilkins
A Harcourt Health Sciences Company



