
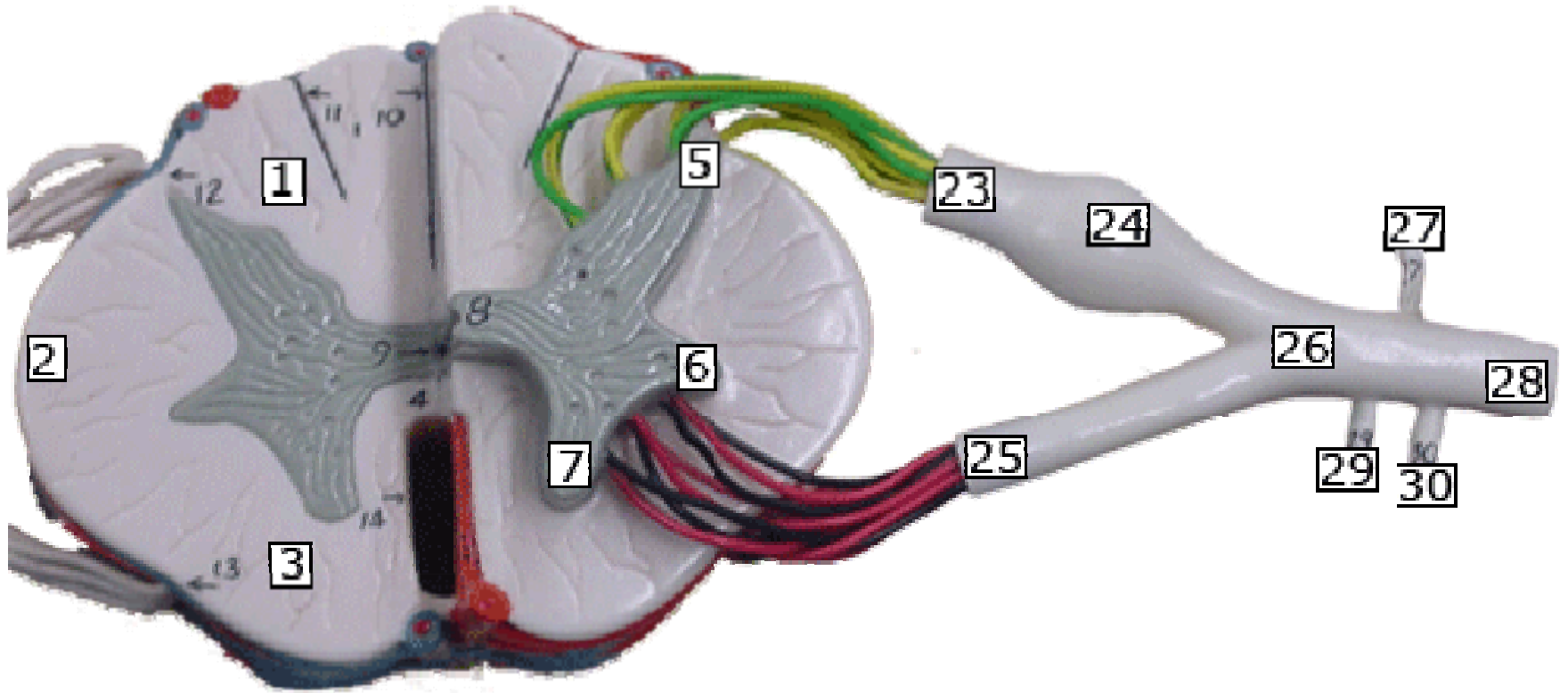


Spinal Cord





White Matter: 1 posterior funiculus / 2 lateral funiculus / 3 anterior funiculus / 4 white commissure / 10 posterior sulcus / 14 anterior fissure

Gray Matter: 5 posterior horn / 6 lateral horn / 7 anterior horn / 8 gray commissure / 9 central canal

Spinal Nerves: 23 dorsal root of spinal nerve (sensory) / 24 dorsal root ganglion / 25 ventral root of spinal nerve (motor) / 26 spinal nerve (mixed) / 27 dorsal ramus of spinal nerve (mixed) / 28 ventral ramus communicans (ANS) / 29 gray ramus communicans (ANS) / 30 white ramus communicans (ANS)