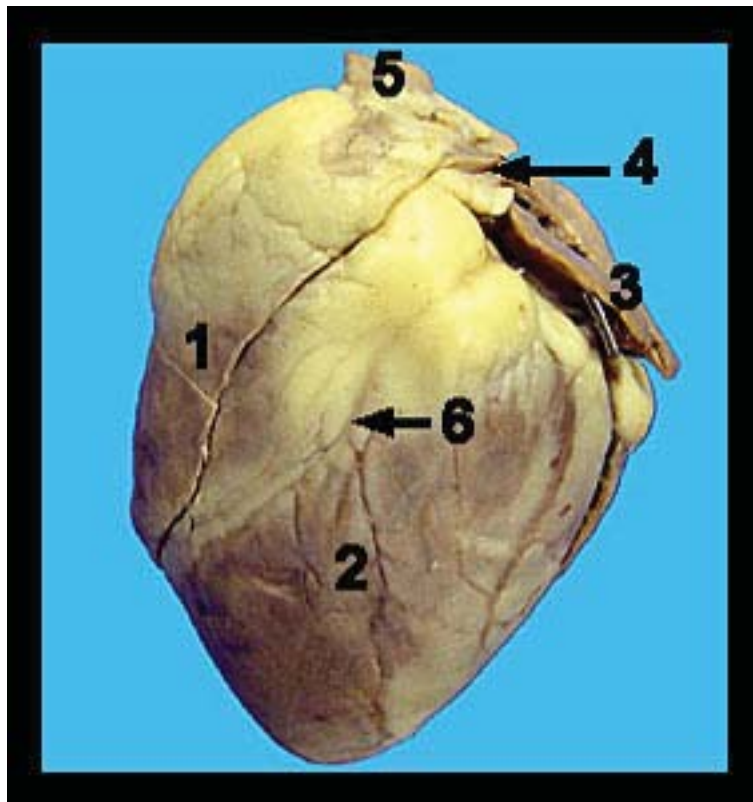


Sheep Heart Dissection

Sheep heart (anterior view)

This image shows an external view of the anterior side of a preserved sheep heart. Note the pointed apex of the heart and the wide superior end of the heart which is termed the base. The large blood vessels (i.e., the great vessels of the heart) which carry blood to and from the heart are located at the base. The right and left atria are also located at the base and appear as thin-walled chambers with irregular, more or less scalloped edges. The wrinkled portion of each atrium that protrudes externally to form a pouch is called the auricle or atrial appendage. The atria serve as receiving chambers for low pressure venous blood returning to the heart thus their walls are extremely thin. Observe the anterior interventricular sulcus extending from the left side of the base obliquely to the heart's right side. The interventricular sulcus contains the left anterior descending coronary artery and the left coronary vein embedded within adipose tissue. The right ventricle lies to your left and toward the base relative to the anterior interventricular sulcus. The left ventricle lies to the right of the anterior interventricular sulcus and extends to and includes the apex of the heart. The ventricles are the pumping chambers of the heart and are, of necessity, thick walled.

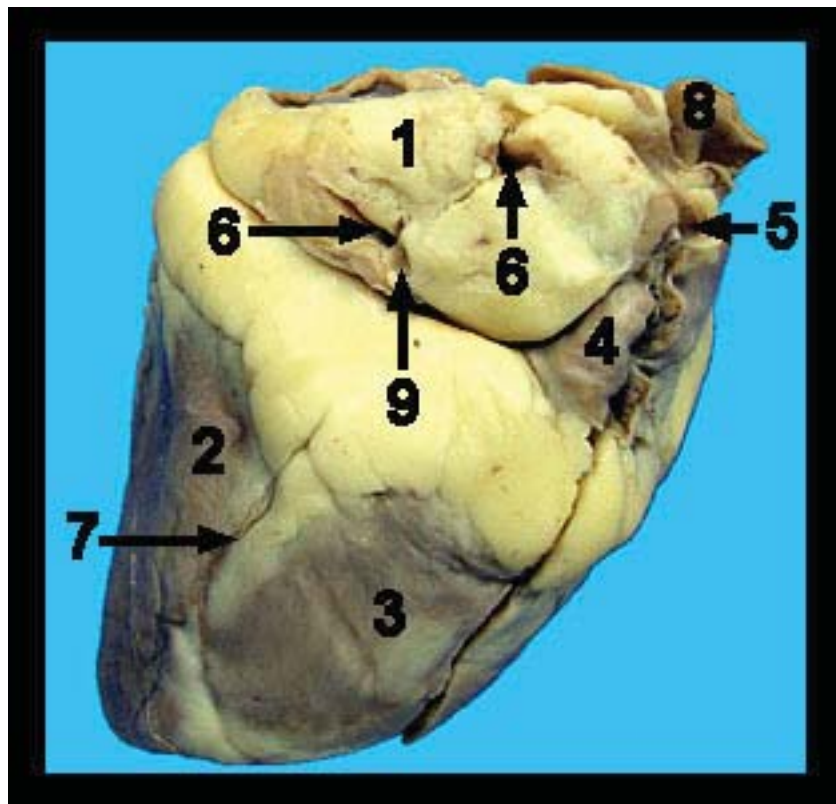
1. Right ventricle
2. Left ventricle
3. Auricle of left atrium
4. Pulmonary trunk
5. Aorta
6. Interventricular sulcus



Sheep Heart (posterior view)

This image shows an external view of a preserved sheep heart. The heart is a four-chambered muscular pump. In adults it is approximately the size of a clenched fist. The four chambers consist of two thin-walled superior atria (singular atrium) and two thick-walled inferior ventricles. The heart is suspended in a double-walled fibroserous sac called the pericardium. The majority of this sac is usually absent from the prepared sheep hearts, but there may be parts of it still attached to the great vessels of the heart. The visceral layer of the pericardium, the epicardium, is attached to the outer surface of the heart wall. It is only one cell layer thick.

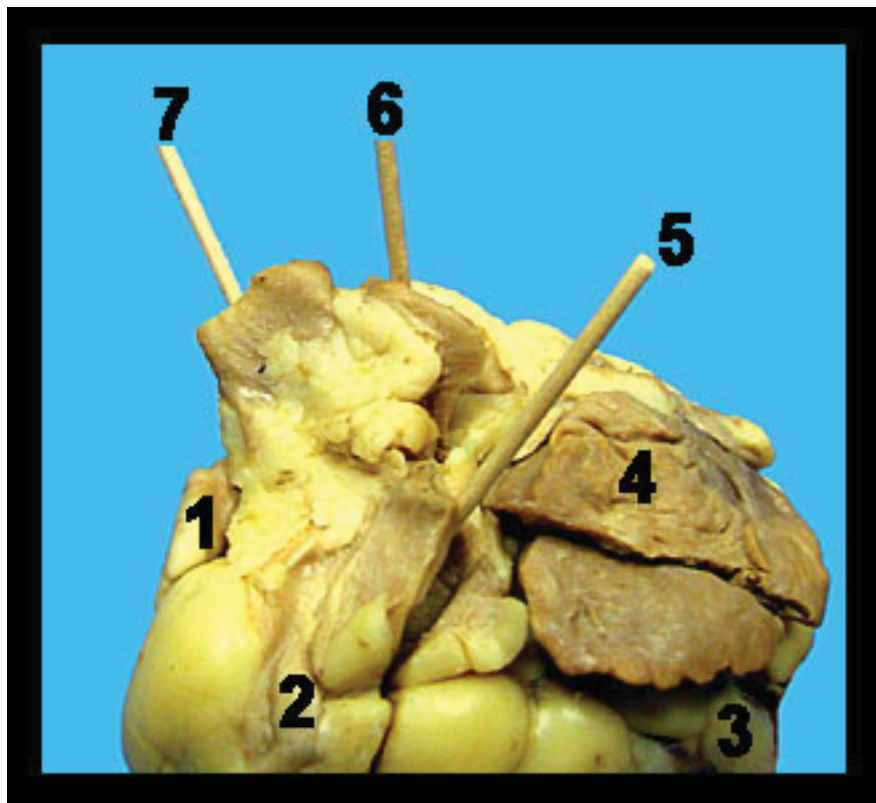
1. Left atrium - 2. Left ventricle - 3. Right ventricle - 4. Right atrium - 5. Superior vena cava
6. Pulmonary veins - 7. Interventricular sulcus - 8. Branch of the aorta - 9. Inferior vena cava



Sheep heart (great vessels)

This image shows an external view of some of the great vessels that leave the heart. The pulmonary trunk, carrying blood low in oxygen and high in carbon dioxide to the lungs, exits the right ventricle and curves toward the left side of the heart. The pulmonary trunk soon branches into the left and right pulmonary arteries which deliver blood to the left and right lungs, respectively. The aorta leaves the left ventricle and carries oxygenated systemic blood to all parts of the body. It is the start of the systemic circulation.

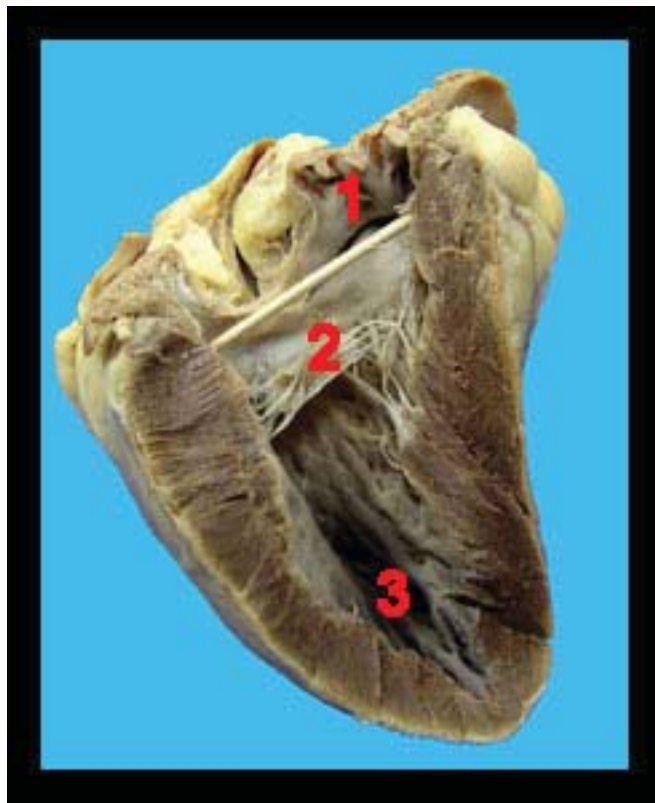
1. Right atrium - 2. Right ventricle - 3. Left ventricle - 4. Left atrium - 5. Pulmonary trunk
6. Aorta - 7. Branch of aorta



Sheep heart (left side)

This image shows the left side of a preserved sheep heart that has been sectioned to reveal its internal chambers. Note the thick, muscular walls of the left ventricle, reflecting its role in pumping oxygenated blood to all parts of the body through the systemic circulatory loop. Oxygenated blood returning from the lungs via the pulmonary veins enters the left atrium and then the left ventricle through a one-way bicuspid (mitral) valve.

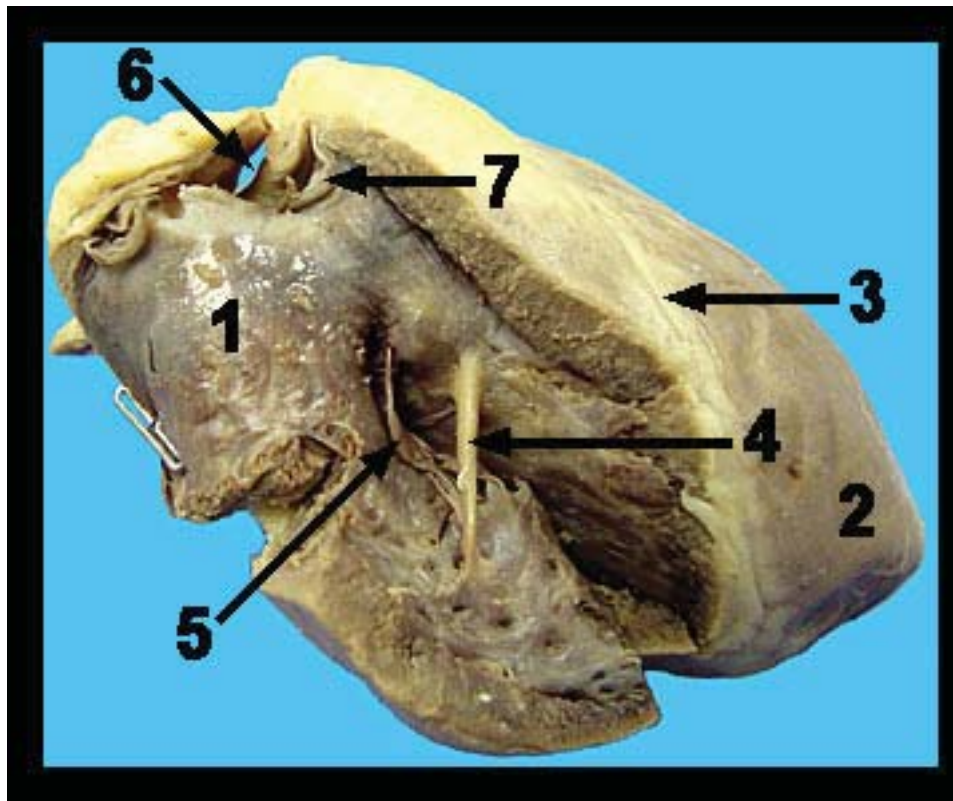
1. Left atrium - 2. Bicuspid (mitral) valve - 3. Left ventricle



Sheep Heart (right side)

This image shows a close-up view of the inside of the right ventricle. Blood from the right atrium enters the right ventricle through the one-way tricuspid valve. The pulmonary trunk, carrying blood low in oxygen and high in carbon dioxide to the lungs, exits the right ventricle and curves toward the left side of the heart. Blood pumped into the pulmonary trunk is prevented from returning to the right ventricle by the pulmonary semilunar valve. A similar valve (the aortic semilunar valve) can be found at the base of the aorta where it exits the left ventricle. Each semilunar valve is composed of three pocket-like cusps with the pocket facing away from the ventricular chamber. When the ventricles contract during systole, the increasing blood pressure within the ventricles forces the cusps of the semilunar valves outward against the arterial walls so that the blood can pass into the aorta and pulmonary trunk. When the ventricles relax (diastole), the pressures within the ventricular chambers fall, and the back flow of arterial blood attempting to reenter the ventricles fills the pockets of the valves and snaps them shut. Notice the moderator band (septomarginal trabecula) running between the inner walls within the right ventricular chamber. As a modified form of one of the trabeculae carneae, the moderator band helps to carry signals to the papillary muscles, allowing them to contract a few milliseconds before the rest of the right ventricle.

1. Right ventricle
2. Left ventricle
3. Interventricular sulcus
4. Moderator band
5. Tricuspid valve
6. Pulmonary trunk
7. Pulmonary semilunar valve



Sheep Heart (close-up left side)

This image shows a close-up view of the inside of the left ventricle. Each side of the heart has a one-way valve between the atrium and the ventricle known as the atrioventricular valve. The atrioventricular (AV) valves of the two sides of the heart are similar in structure except that the right atrioventricular valve has three cusps while the left atrioventricular valve has two cusps. The right (AV) valve is termed the tricuspid valve while the left (AV) valve is termed the bicuspid valve. The bicuspid valve is also known as the mitral valve. Tendon-like strands of connective tissue known as chordae tendineae (“heart strings”) run from the free edges of the cusps and attach on the ventricular wall to small projections of cardiac muscle called the papillary muscles. When the ventricles contract (systole), increased blood pressure within the chambers forces the cusps upward and together thereby closing the valve. This prevents the back flow of blood from the ventricle into the atrium. The chordae tendineae prevent the cusps from being pushed too far into the atria by the increased ventricular pressure. Muscular ridges called trabeculae carneae that project from the wall of the ventricle can also be seen in the image.

1. Aorta
2. Aortic semilunar valve
3. Bicuspid (mitral) valve
4. Chordae tendineae
5. Papillary muscles
6. Trabeculae carneae

