Skin Disorders

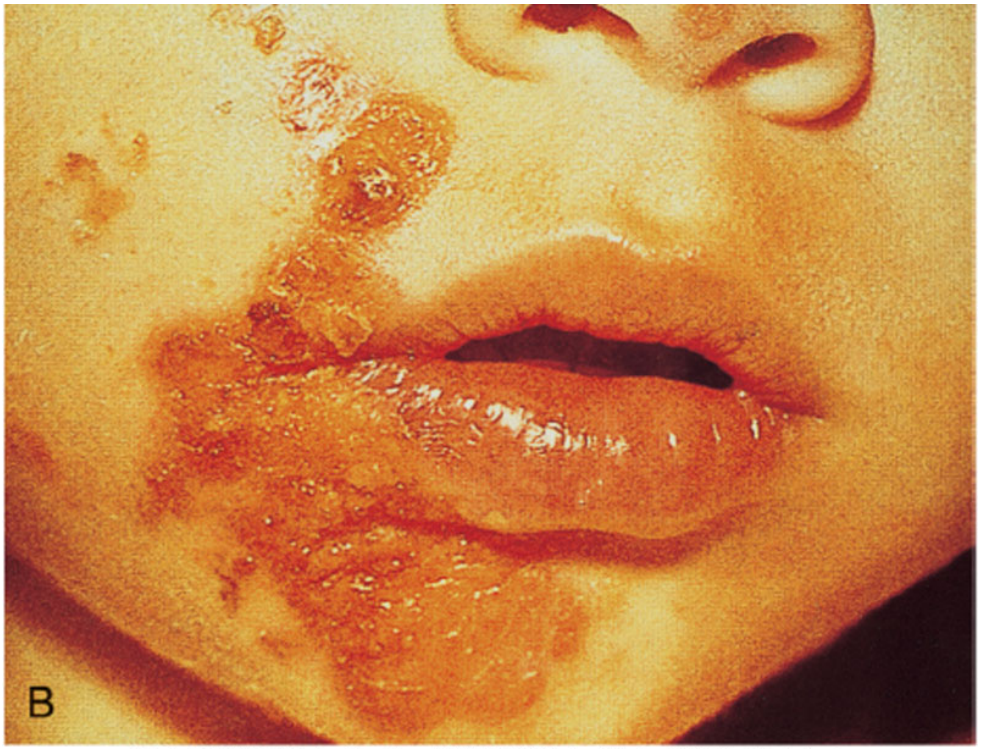

A. From Lookingbill D, Marks J: Principles of Dermatology, *ed 2, Philadelphia, 1993, Saunders.* B. Courtesy of Dr. M. McKenzie, Toronto, Canada.

Diagram of the Skin

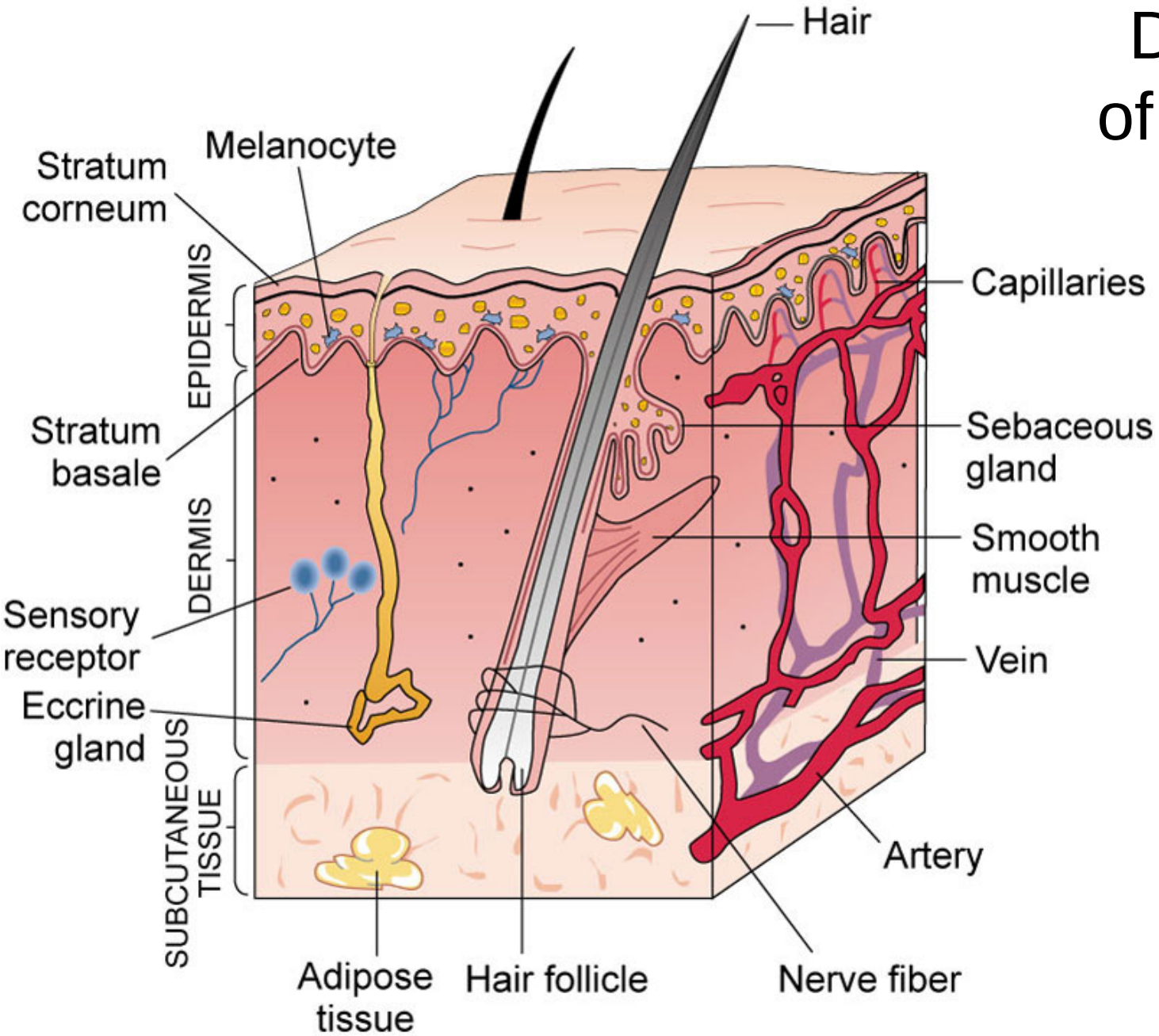

Skin Lesions

- The physical appearance of the lesion is necessary to make a diagnosis.

- Skin lesions may be caused by:

  - Systemic disorders // Liver disease
  - Systemic infections // Chickenpox
  - Allergies to ingested food or drugs
  - Localized factors // Include exposure to toxins

Skin Lesions (Cont.)

- Types of lesions
  - Location
  - Length of time lesion has been present
  - Changes occurring over time
  - Physical appearance
    - Color
    - Elevation
    - Texture
    - Type of exudate
  - Presence of pain or pruritus (itching)

Common Skin Lesions

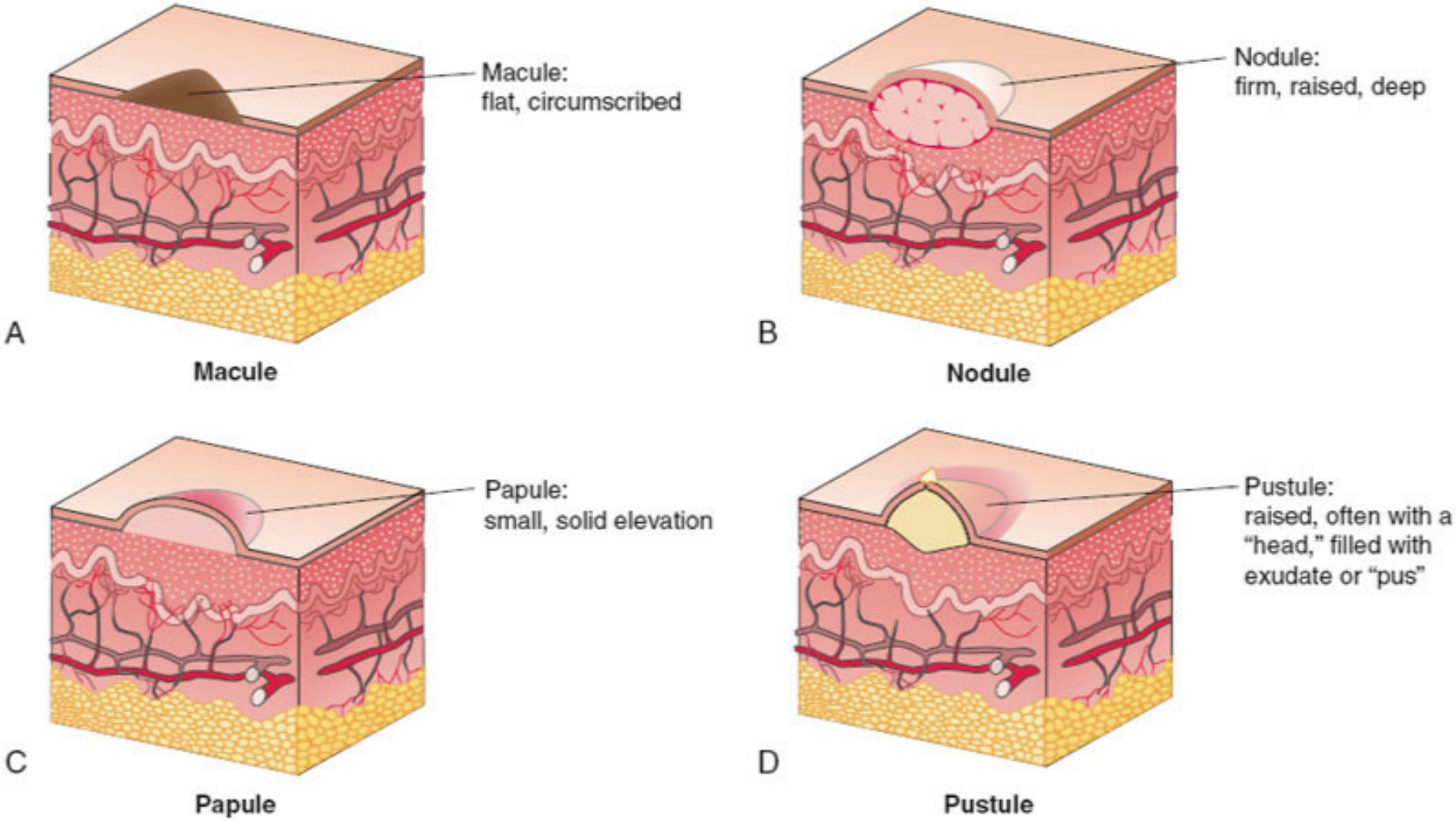

Common Skin Lesions (Cont.)

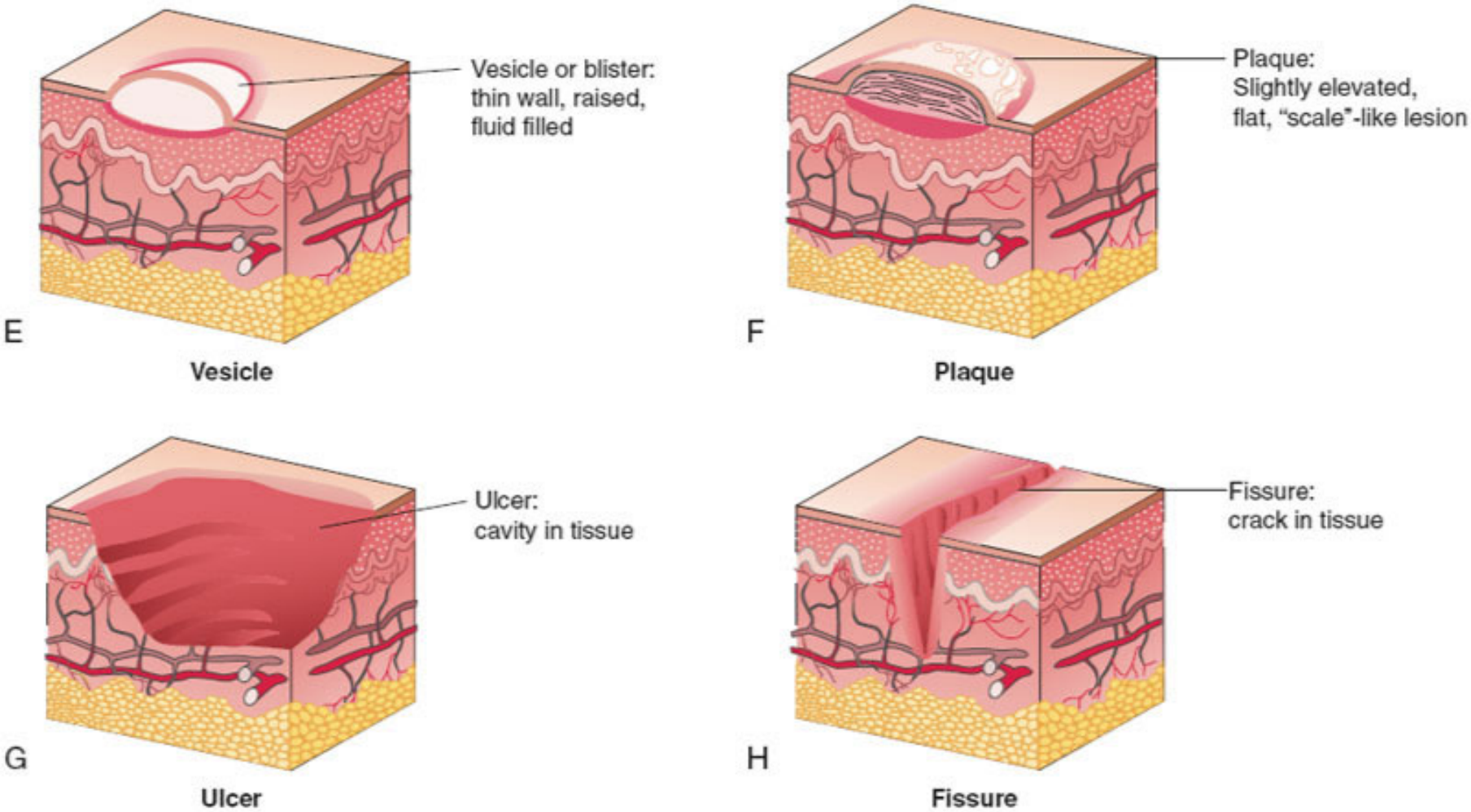

TABLE 8-1 Description of Some Skin Lesions

Macule	Small, flat, circumscribed lesion of a different color than the normal skin
Papule	Small, firm, elevated lesion
Nodule	Palpable elevated lesion; varies in size
Pustule	Elevated, erythematous lesion, usually containing purulent exudate
Vesicle	Elevated, thin-walled lesion containing clear fluid (blister)
Plaque	Large, slightly elevated lesion with flat surface, often topped by scale
Crust	Dry, rough surface or dried exudate or blood
Lichenification	Thick, dry, rough surface (leather-like)
Keloid	Raised, irregular, and increasing mass of collagen resulting from excessive scar tissue formation
Fissure	Small, deep, linear crack or tear in skin
Ulcer	Cavity with loss of tissue from the epidermis and dermis, often weeping or bleeding
Erosion	Shallow, moist cavity in epidermis
Comedone	Mass of sebum, keratin, and debris blocking the opening of a hair follicle

Pruritus

- Associated with
  - Allergic responses
  - Chemical irritation caused by insect bites
  - Infestations by parasites (e.g., scabies)
- Mechanism not totally understood
  - Release of histamine in a hypersensitivity response causes increase in pruritus
  - Infection may result from breaking the skin barrier.
  - Caused by scratching

Diagnostic Tests for Skin Lesions

- Culture and staining of specimens
  - Bacterial infections: microscopic and direct observations
  - Specific procedures for fungal or parasitic infections
- Biopsy // allows for the detection of malignant changes // Safeguard prior to or following removal of skin lesions
- Blood tests // Helpful in diagnosis of conditions caused by allergy or abnormal immune reaction
- Skin testing using patch or scratch method

General Treatment Measures

- Pruritus
  - Topical agents to reduce sensation
  - May be treated by antihistamines or glucocorticoids
- Avoidance of allergens // Reduce risk of recurrence
- If caused by infections // May require antibiotic treatment
- Precancerous lesions // Surgery, laser therapy, electrodessication, cryosurgery

Inflammatory Disorders

Contact Dermatitis

- Exposure to an allergen
  - Metals, cosmetics, soaps, chemicals, plants
  - Sensitization occurs on first exposure.
  - Pruritic rash develops at site a few hours after exposure.
- Direct chemical or mechanical irritation // Mediated by Type IV hypersensitivity
  - Is inflammatory because of direct exposure
    - Removal of irritant
    - Reduction of inflammation with topical glucocorticoids

Contact Dermatitis from Adhesive Tape

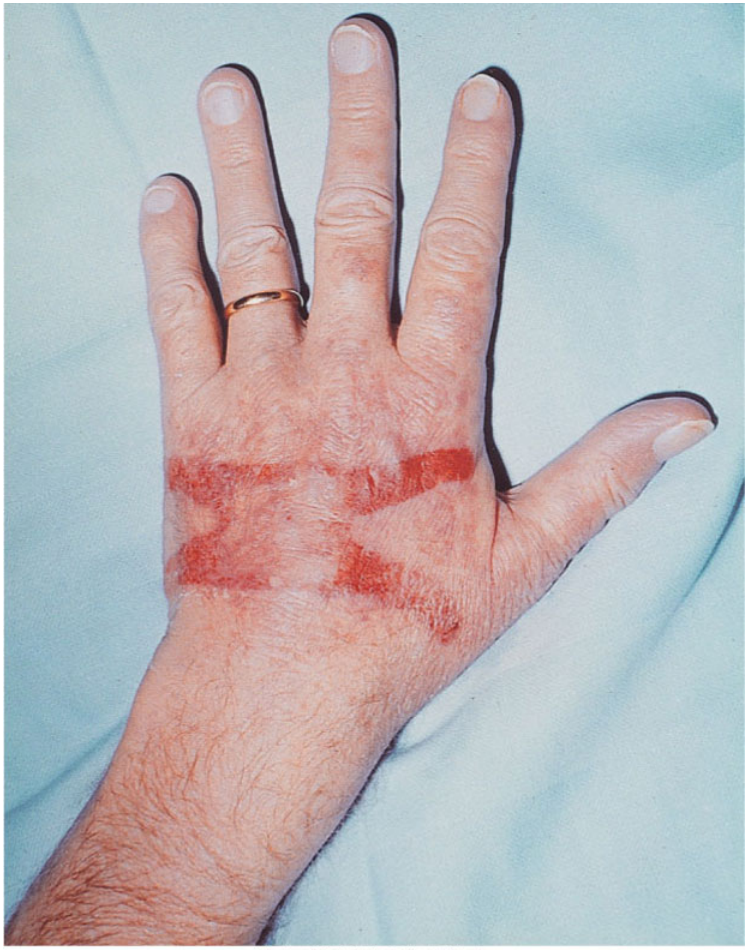

Courtesy of Dr. M. McKenzie, Toronto, Canada.

Urticaria (Hives)

- Result of type I hypersensitivity
  - Ingestion of substances // Examples: shellfish, drugs, certain fruits
- Lesions are highly pruritic.
- Hives are often part of anaphylaxis!
  - Check for swelling around mouth and check airway.
  - Administer EpiPen or other first aid as required.

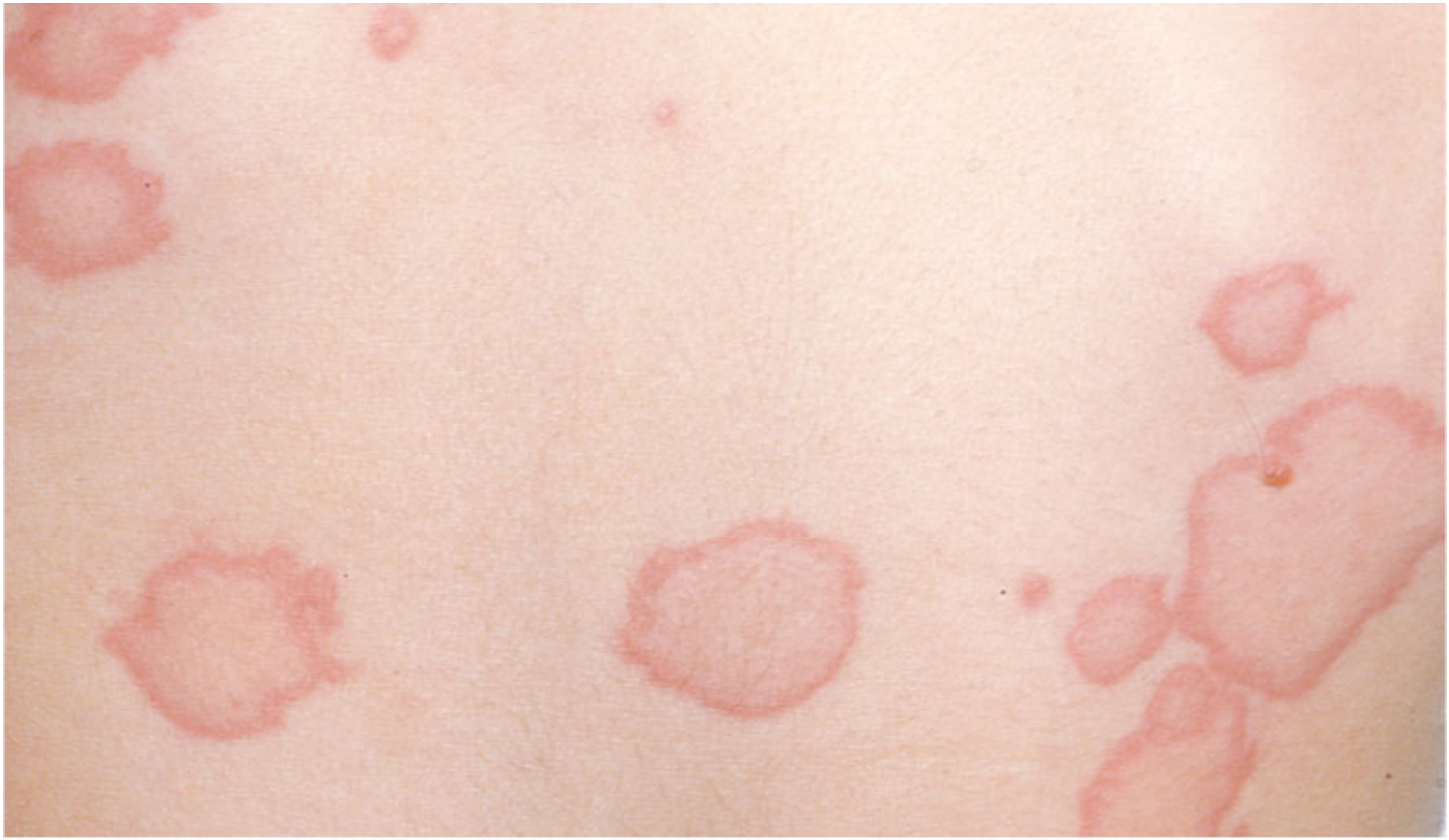

From Dorland's Illustrated Medical Dictionary, ed 32, St. Louis, 2012, Saunders.

Atopic Dermatitis (Eczema)

- Atopic - inherited tendency
- Common problem in infancy
  - Rash is erythematous, with serous exudate.
  - Commonly occurs on face, chest, and shoulders
- In adults, rash is dry, scaly, and pruritic, often on flexor surfaces.

Atopic Dermatitis (Eczema) (Cont.)

- Chronic inflammation results from response to allergens.
  - Eosinophilia and increased serum IgE levels
- Potential complication—secondary infections
- Treatment // Topical glucocorticoids & antihistamines

Infant with Extensive Atopic Dermatitis

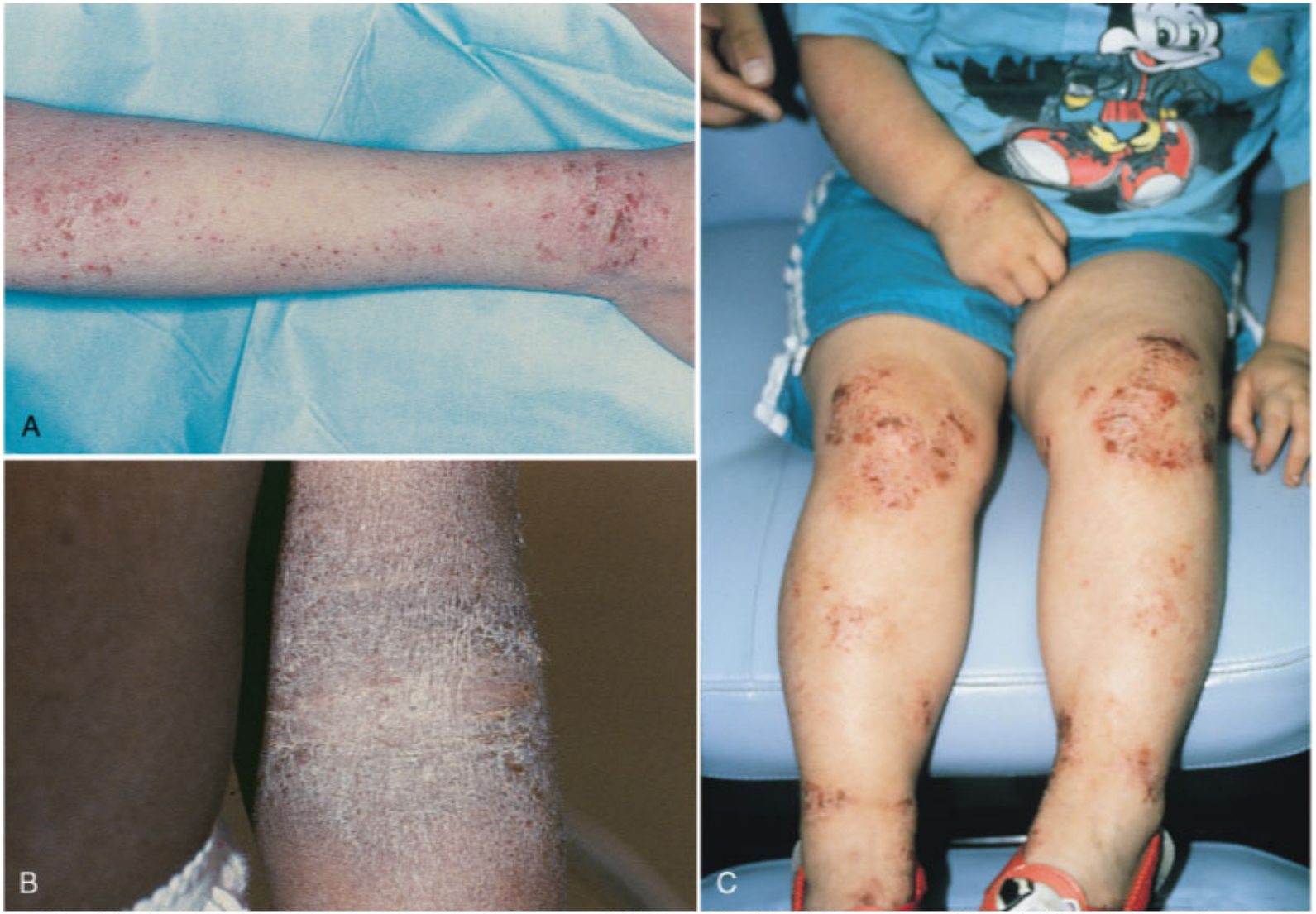

A, B From Callen JP, et al: Color Atlas of Dermatology, *Philadelphia, 1993, Saunders, p 192. C, From McCance KL, et al:* Pathophysiology, *ed 6, St. Louis, 2010, Mosby. Courtesy Department of Dermatology, School of Medicine, University of Utah.*

Psoriasis

- Chronic inflammatory skin disorder
- Onset usually in the teenage years
- Psoriasis results from abnormal T cell activation.
  - Excessive proliferation of keratinocytes
  - Cellular proliferation is greatly increased.
- Lesions found on face, scalp, elbows, knees // Itching or burning sensations
- Treatment // Glucocorticoids, tar preparations, antimetabolites

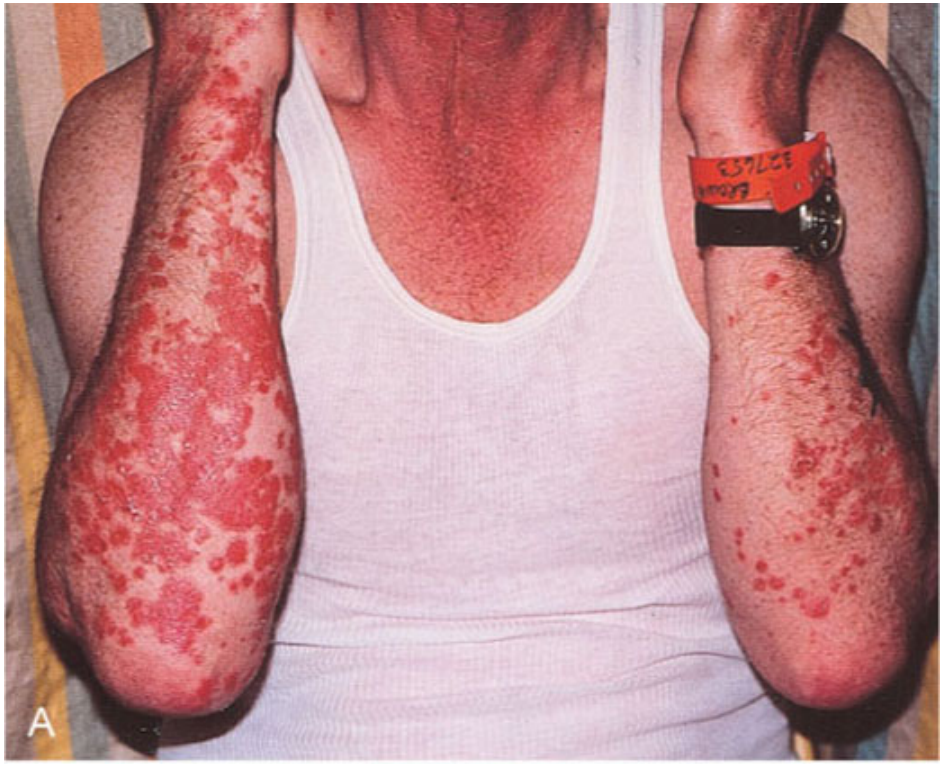

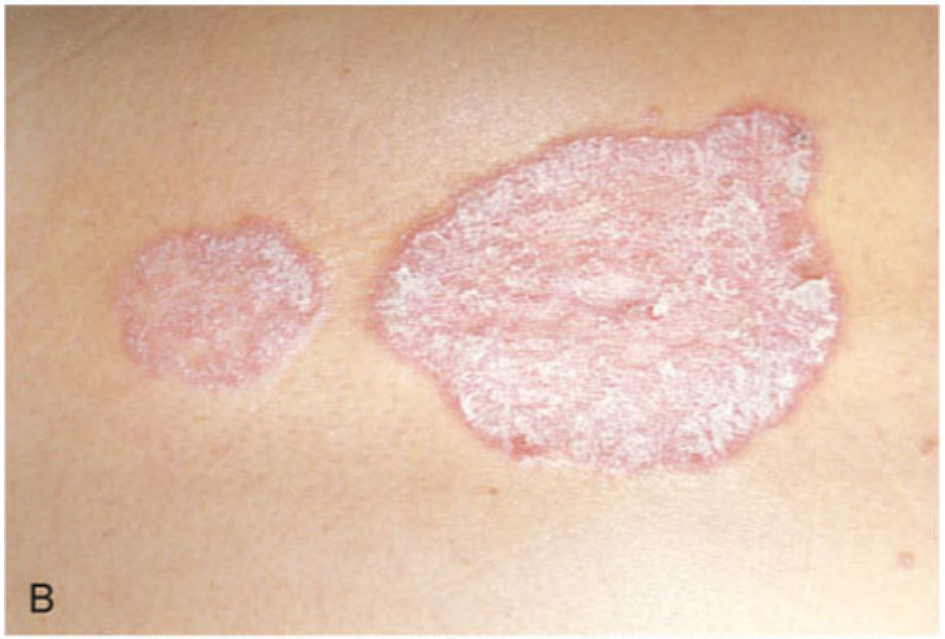

A, Courtesy of Dr. M. McKenzie, Toronto, Canada. B, From Lookingbill DP, Marks JG: Principles of Dermatology, ed 3, Philadelphia, 2000, Saunders.

Psoriasis: Acute Inflammatory Stage

Pemphigus

- Autoimmune disorder
- Autoantibodies disrupt cohesion between epidermal cells.
  - Causes blisters (bullae) to form
  - Skin sheds, leaving area painful and open to secondary infection.
  - May be life-threatening if extensive (e.g., Stevens-Johnson Syndrome)
- Treatment // Systemic glucocorticoids and immuno-suppressants

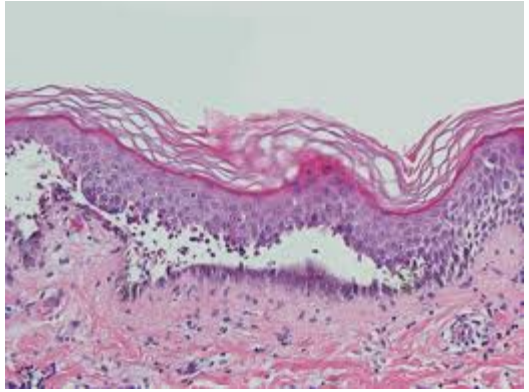

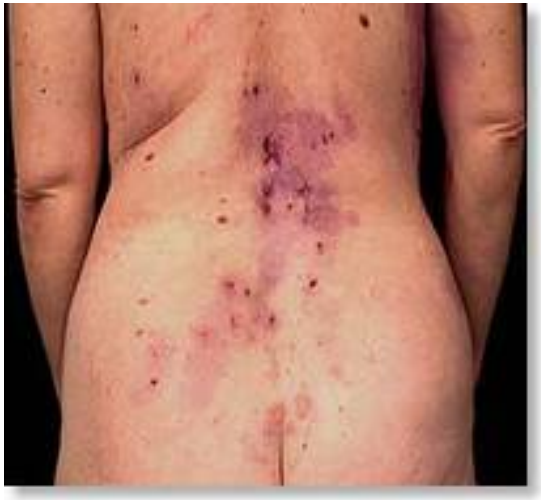

Scleroderma

- May occur as skin disorder
- May be systemic and affect viscera
- Primary cause unknown
  - Increased collagen deposition is observed in all cases.
  - Inflammation and fibrosis with decreased capillary networks
    - Hard, shiny, tight, immovable areas of skin
    - Impaired movement of mouth and eyes
- May cause renal failure, intestinal obstruction, respiratory failure caused by distortion of tissues

Scleroderma (Cont.)

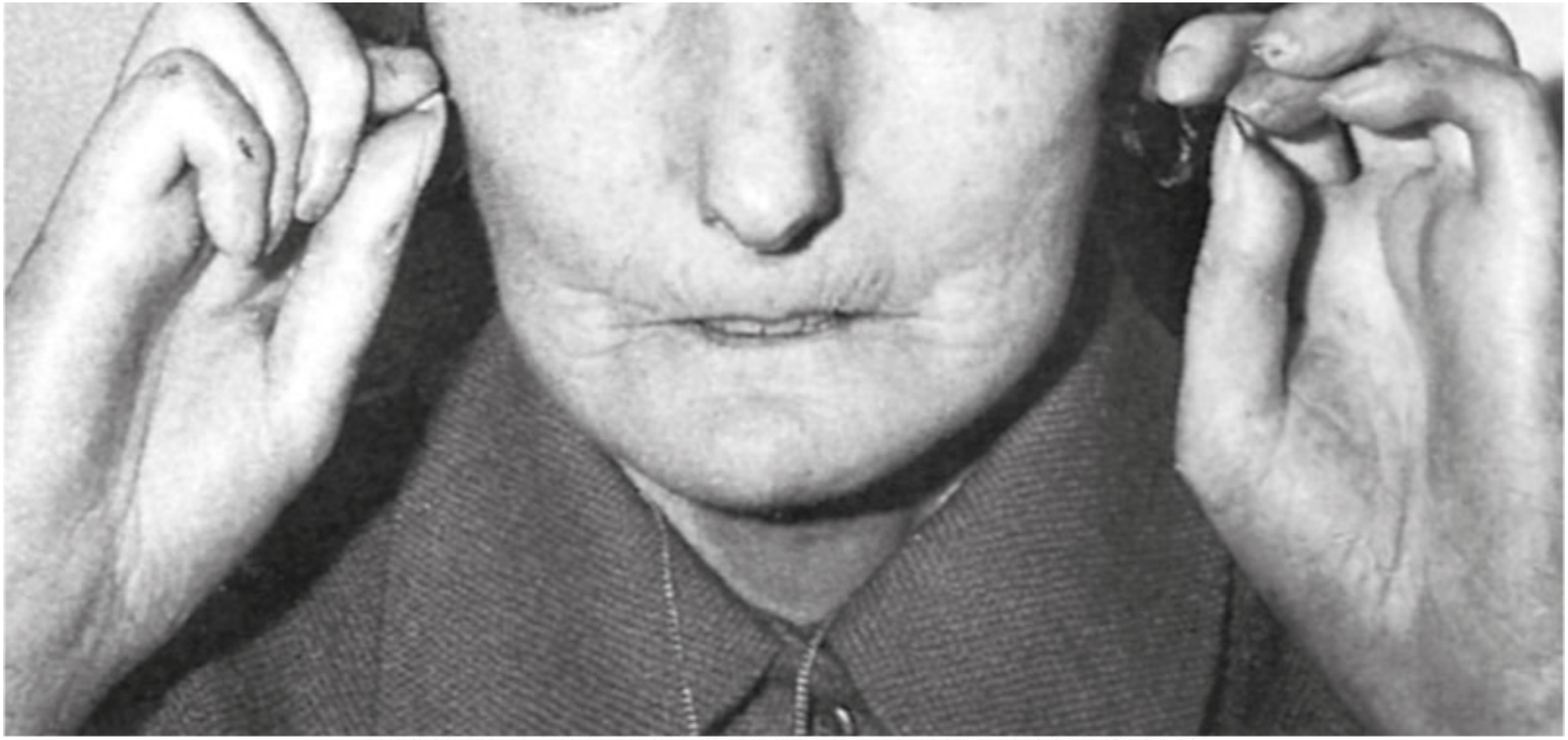

From Odom RB, James WD, Berger TG: Andrews' Diseases of the Skin, *ed 9, Philadelphia, 2000, Saunders.*

Skin Infections

Skin Infections

- May be caused by bacteria, viruses, fungi, other types of microbes, parasites
- Caused by opportunistic microbes
- Minor abrasions or cuts
- Serious infections may develop.
- Causative organism needs to be identified for appropriate treatment

Resident (Normal) Flora of the Skin

- Mixed flora (also referred to as the microbiota) components differ in various areas of the body.
- Microbes also reside under the fingernails, in hair follicles, and in glands.
- Opportunistic infections may occur because of injury or other inflammatory lesion.
- Infection may spread systemically from skin lesions.

Bacterial Infection // Cellulitis (erysipelas)

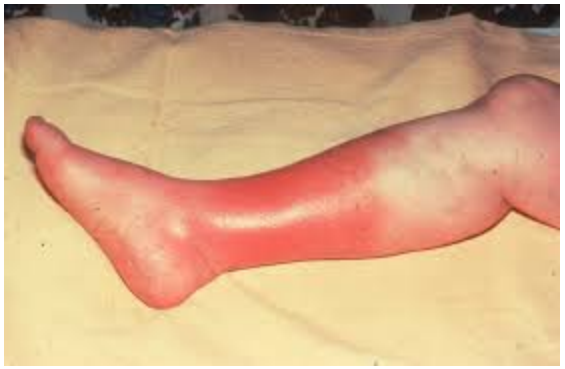

- Infection of the dermis and subcutaneous tissue
- Usually secondary to an injury
- May be iatrogenic (adverse condition in a patient resulting from treatment by a physician or surgeon).
- Causative organisms // Usually *Staphylococcus aureus* & Sometimes *Streptococcus*
- Frequently in lower trunks and legs /// Especially in individuals with restricted circulation in the extremities; also in immunocompromised individuals /// Area becomes red, swollen, and painful // Red streaks may develop, running along lymph vessels proximal to infected area

Bacterial Infection // Furuncles (Boils)

- Usually caused by *S. aureus* /// <u>Begins at hair follicles</u>
  - Face, neck, back
  - Frequently drains large amounts of purulent exudate
- Autoinoculation /// Squeezing boils can result in spread of infection to other areas of the skin.
- Carbuncles /// Collection of furuncles that coalesce to form a large infected mass

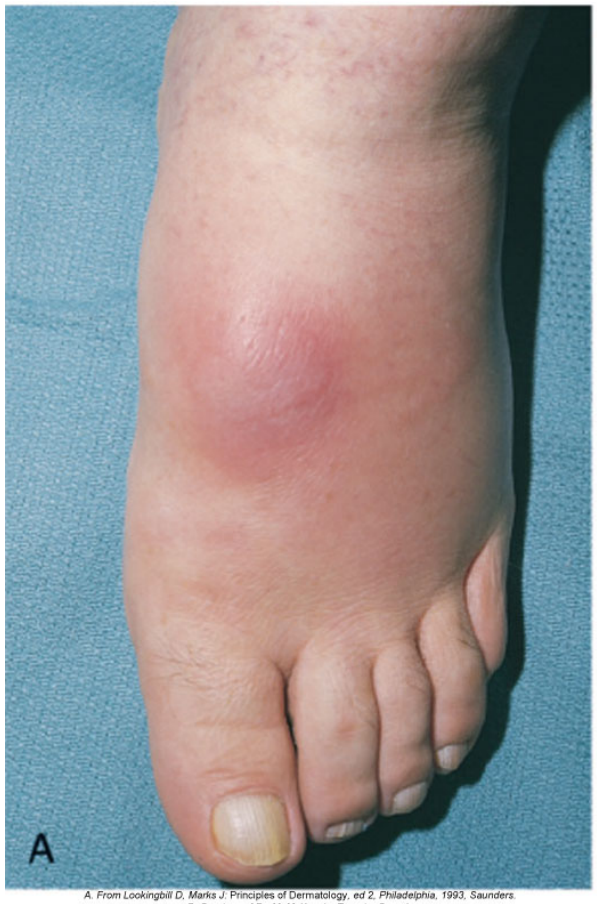

A. From Lookingbill D, Marks J. Principles of Dermatology, ed 2, Philadelphia, 1993, Saunders.
B. Courtesy of Dr. M. McKenzie, Toronto, Canada.

Impetigo

- Common infection in infants and children
  - May also occur in adults
  - *S. aureus*—highly contagious in neonates
- Lesions commonly on face
- Transmission may occur through close physical contact or through fomites
- Pruritus common // Leads to scratching and further spread of infection

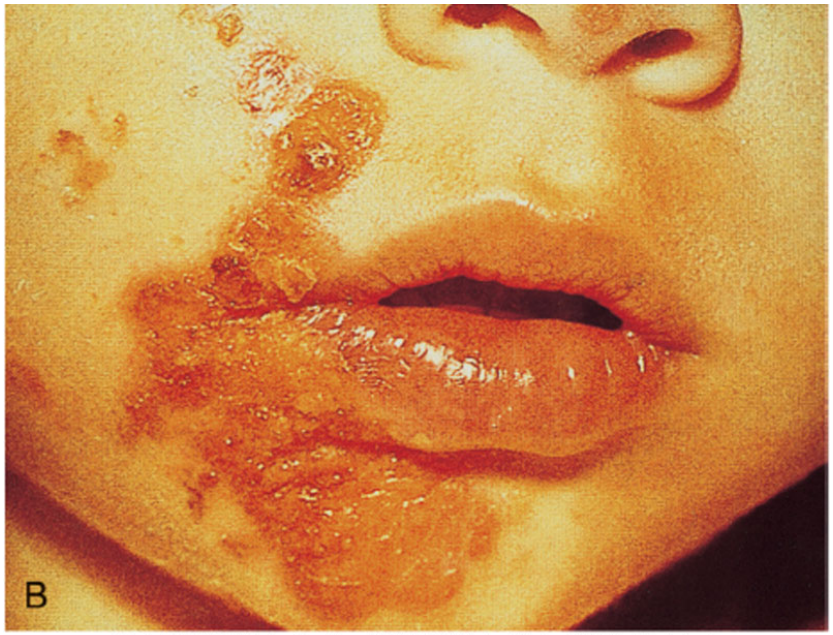

A. From Lookingbill D, Marks J: Principles of Dermatology, *ed 2, Philadelphia, 1993, Saunders.* B. Courtesy of Dr. M. McKenzie, Toronto, Canada.

Impetigo: Treatment

- Topical antibiotics in early stages
- Systemic administration if lesions are extensive
  - Antibiotic-resistant strains of *S. aureus* are increasing in numbers.
  - Local outbreaks of infection may result.

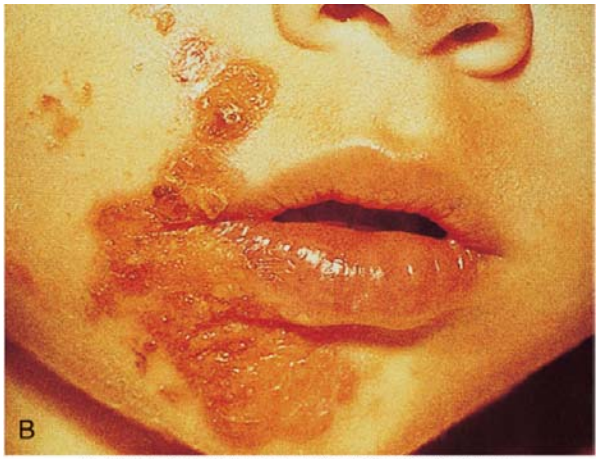

A. From Lookingbill D, Marks J: Principles of Dermatology, ed 2. Philadelphia, 1993, Saunders. B. Courtesy of Dr. M. McKenzie, Toronto, Canada.

Acute Necrotizing Fasiciitis

- Mixture of aerobic and anaerobic bacteria usually at site of infection
- Severe inflammation and tissue necrosis
  - Usually caused by virulent strain of gram-positive, group A beta-hemolytic *Streptococcus // also staphlococcus*
  - Bacteria secrete toxins that break down fascia and connective tissue // causing massive tissue destruction.
- Often a history of minor trauma or infection in the skin and subcutaneous tissue of an extremity

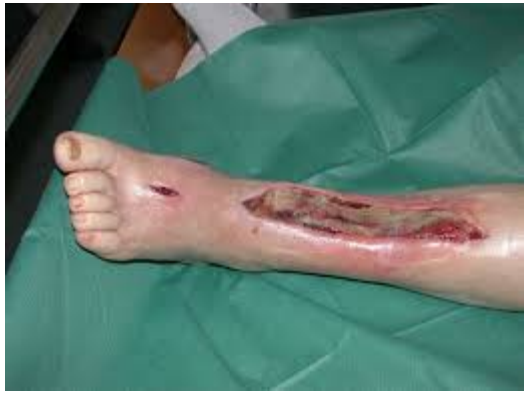

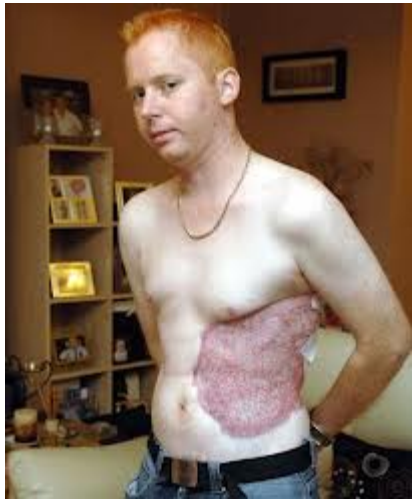

Acute Necrotizing Fasciitis (Cont.)

- Delay in treatment - greater tissue loss, potential amputation, higher probability of mortality
- Systemic toxicity develops with fever, tachycardia, hypotension, mental confusion, disorientation, possible organ failure
- Treatment
  - Aggressive antimicrobial therapy & fluid replacement
  - Excision of all infected tissue; amputation

Leprosy (Hansen's Disease)

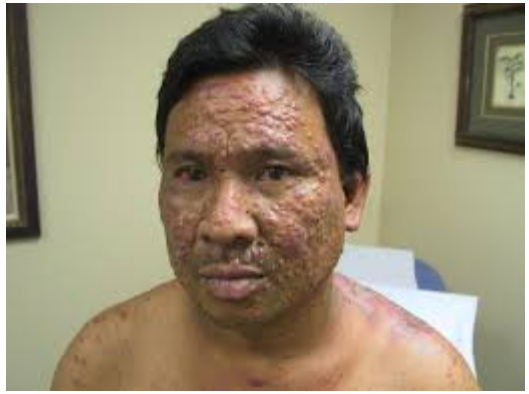

- Caused by *Mycobacterium leprae*
- Chronic disease
- Clinical signs and symptoms vary.
  - Generally affects skin, mucous membranes, and peripheral nerves
  - Damage can lead to loss of limbs.

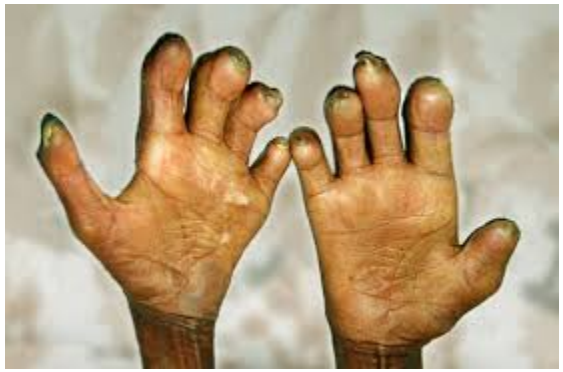

- Mechanism of pathogenicity largely unknown
- Diagnosis through microscopic examination of skin biopsy
- Treatment primarily with antibiotics

Viral Infections

Herpes Simplex

- Herpes simplex type 1 (HSV-1) /// Most common cause of cold sores or fever blisters
- Herpes simplex type 2 (HSV-2) - genital herpes
- Both types of HSV cause similar effects.
- Primary infection may be asymptomatic /// Virus remains latent in sensory nerve ganglia.
- Recurrence may be triggered by:
  - Common cold, sun exposure, stress

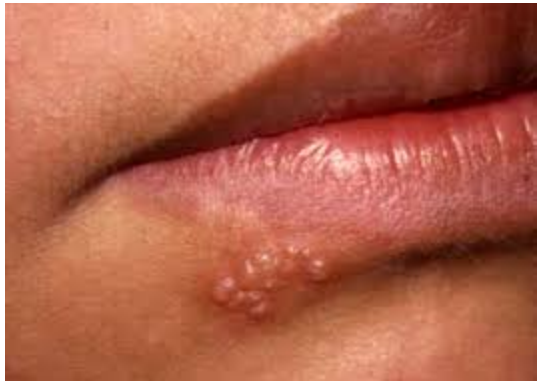

Herpes Simplex (Cont.)

- Spread by direct contact with fluid from lesion
- Spread of infection to others possible prior to appearance of lesions
- Potential complication
  - Spread of virus to eye // Keratitis
  - Herpetic whitlow // Painful infection of the fingers

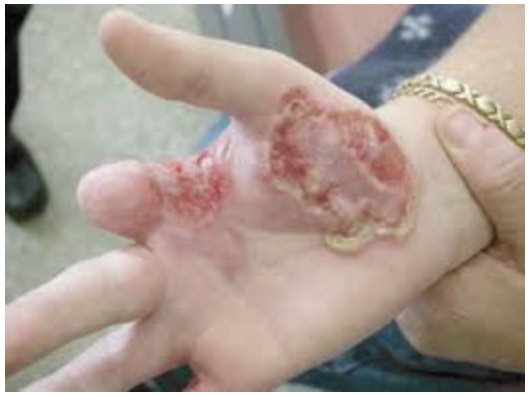

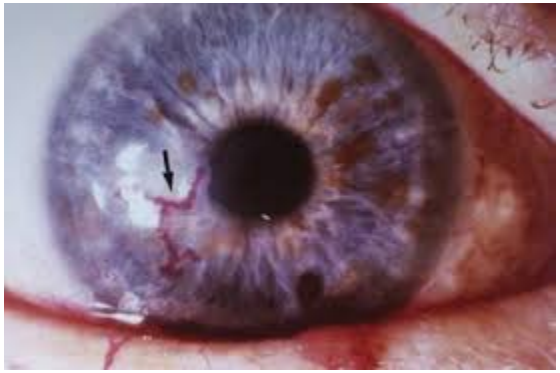

Herpes Simplex

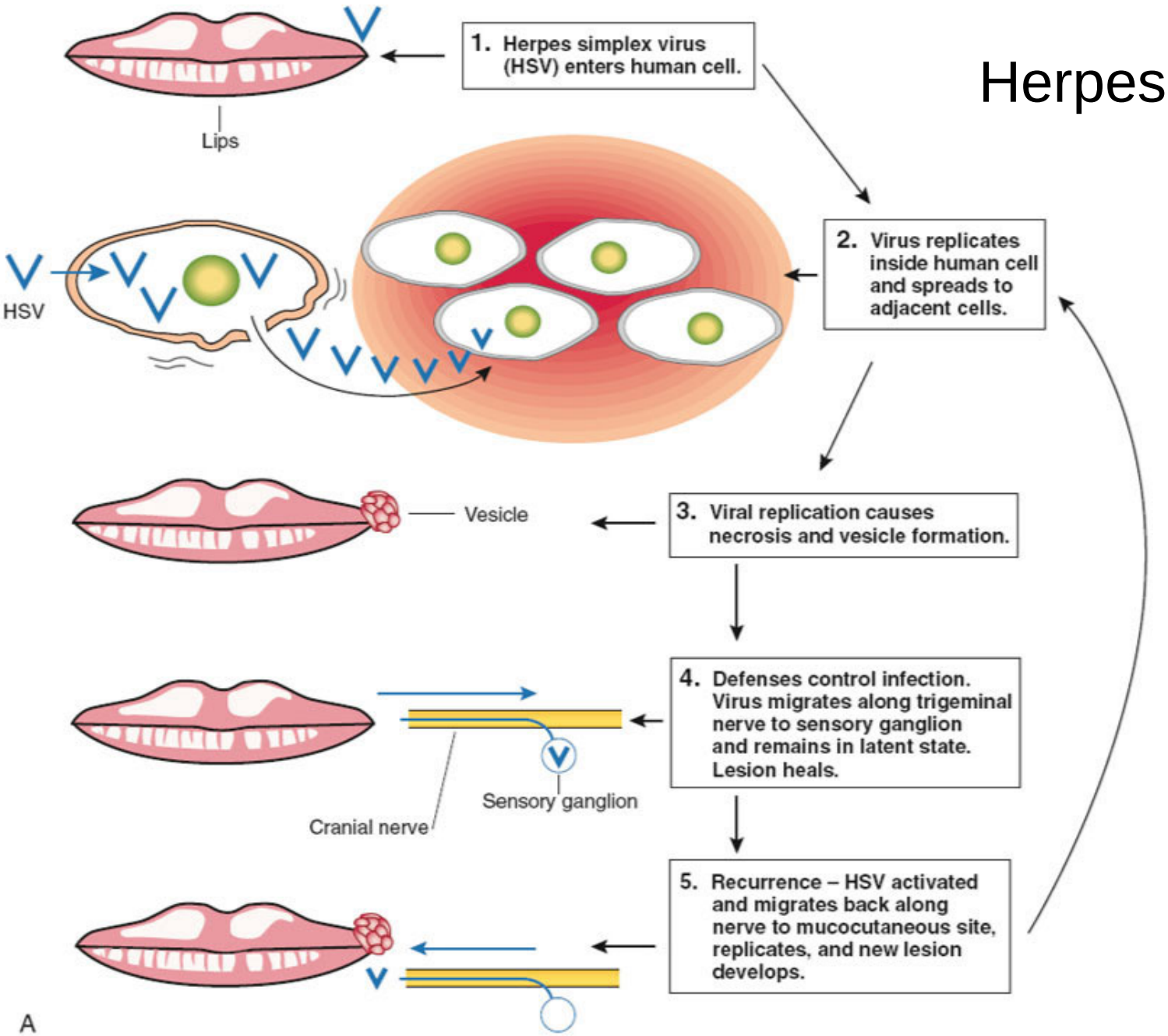

Courtesy of Dr. M. McKenzie, Toronto, Canada.

Verrucae (Warts)

- Human papillomavirus (HPV) types 1 to 4 /// Frequently develop in children and young adults
- Plantar warts are common.
- Spreads by viral shedding of the skin surface
- May resolve spontaneously with time
- Genital warts (HPV types 6 and 11)

Plantar Warts

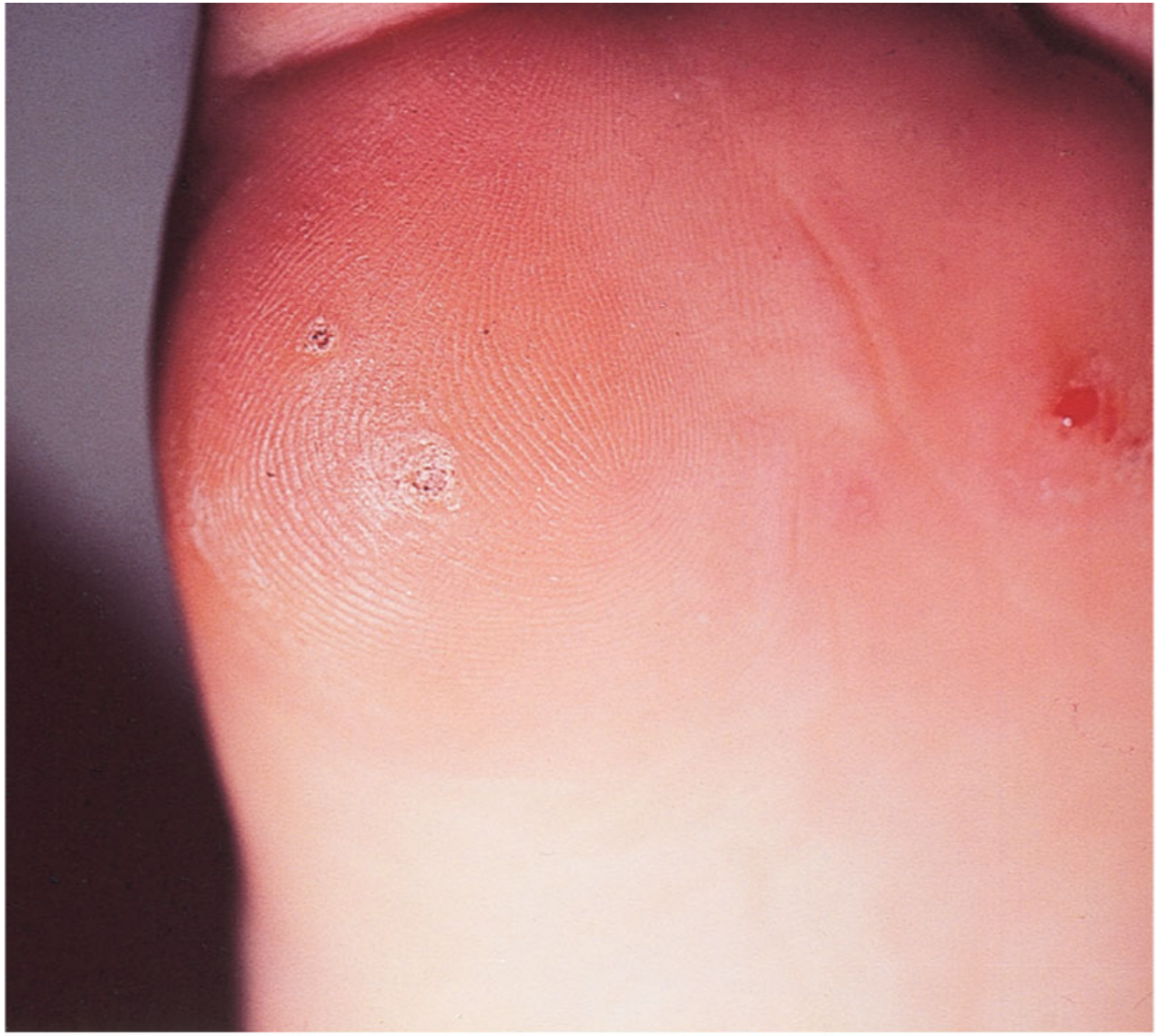

Courtesy of Dr. M. McKenzie, Toronto, Canada.

Fungal Infections (Mycoses)

- Most are superficial
  - *Candida* infection is associated with diabetes.
  - May spread systemically in immunocompromised individuals
- Diagnosed from skin scrapings
  - Become fluorescent in ultraviolet light
  - Microscopic examination
  - Culturing of samples

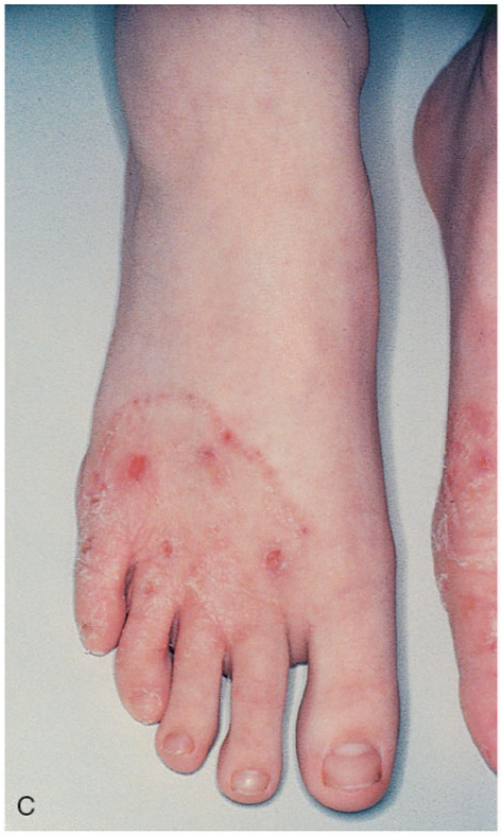

From Callen JP, et al: *Color Atlas of Dermatology*, Philadelphia, 1993, Saunders.

Tinea Pedis

Location of Tinea

- Tinea capitis
  - Infection of the scalp
  - Common in school-age children
  - Erythema may be apparent.
  - Oral antifungal medication
- Tinea corporis
  - Infection of the body, particularly of nonhairy parts
  - Round lesion with clear center (ringworm)
  - Pruritus may be present.
  - Topical antifungal medication

Location of Tinea

- Tinea pedis
  - Athlete's foot—involves the feet, particularly the toes
  - Associated with swimming pools and gymnasiums
  - May be part of normal flora that becomes opportunistic
  - Secondary bacterial infection may occur
  - Topical antifungal medication

Location of Tinea

- Tinea unguium
  - Infection of the nails, particularly the toenails
    - Nails turn white, then brown.
    - Nail thickens and cracks.
    - Infection tends to spread to other nails.

Other Infections

- Scabies
  - Invasion by mite *Sarcoptes scabiei*
  - Female burrows into epidermis /// Lays eggs over a period of several weeks
  - Male dies after fertilizing the female /// Female dies after laying the eggs.
  - Larvae migrate to skin surface. /// Burrow into skin in search of nutrients - Intensively pruritic!
  - Larvae mature and cycle is repeated
  - Burrows appear on skin as tiny, light brown lines.

Scabies

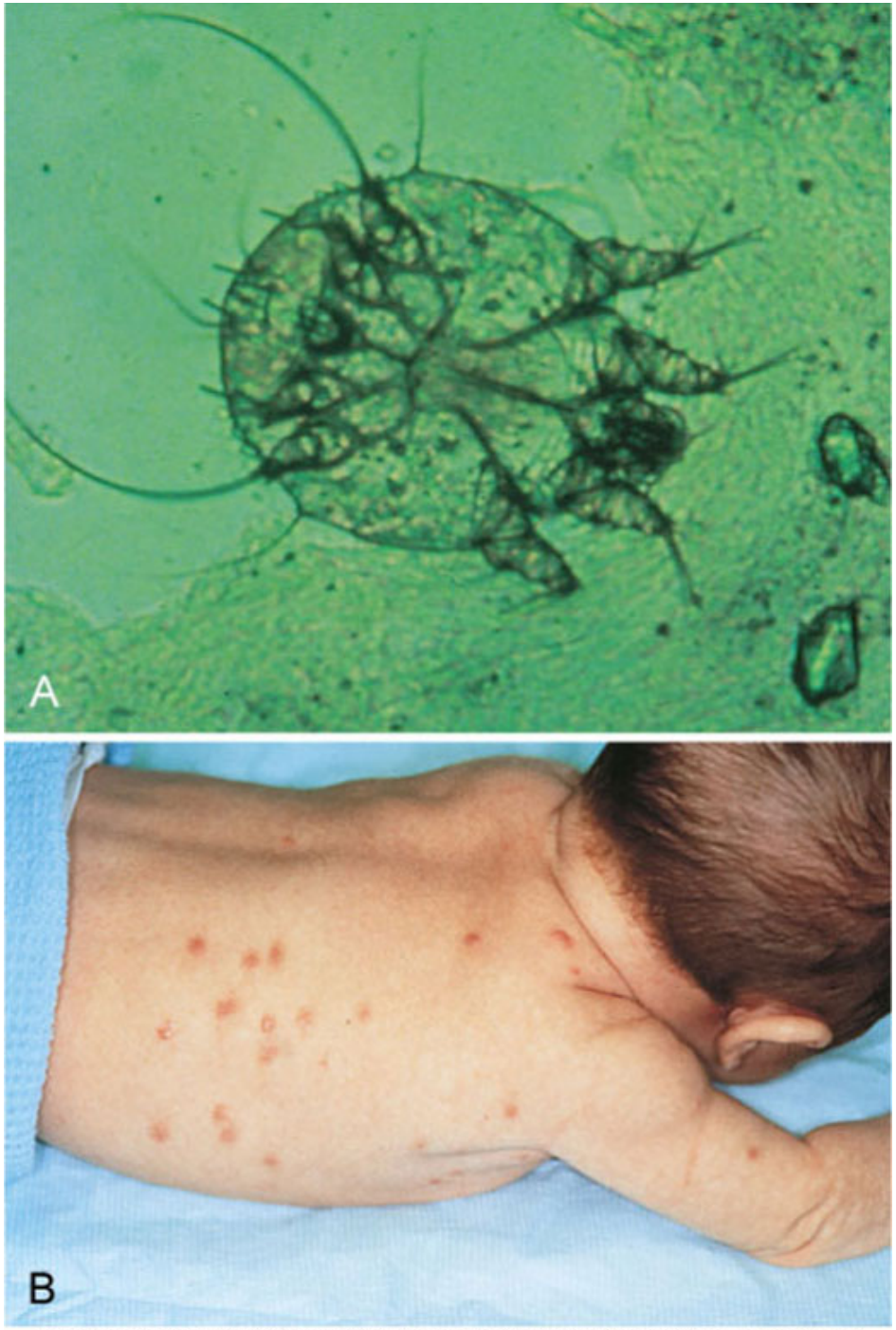

From McCance KL, et al: Pathophysiology, ed 6, St. Louis, 2010, Mosby. Courtesy Department of Dermatology, School of Medicine, University of Utah.

Other Infections (Cont.)

- Pediculosis (lice)
  - Pediculus humanus corporis—body louse
  - Pediculus humanus capitis—head louse
  - Pediculus humanus pubis—pubic louse
  - Female lice lay eggs on hair shafts.
  - After hatching, louse bites human host, sucking blood for production of ova
  - Excoriations result from scratching.

Pediculosis

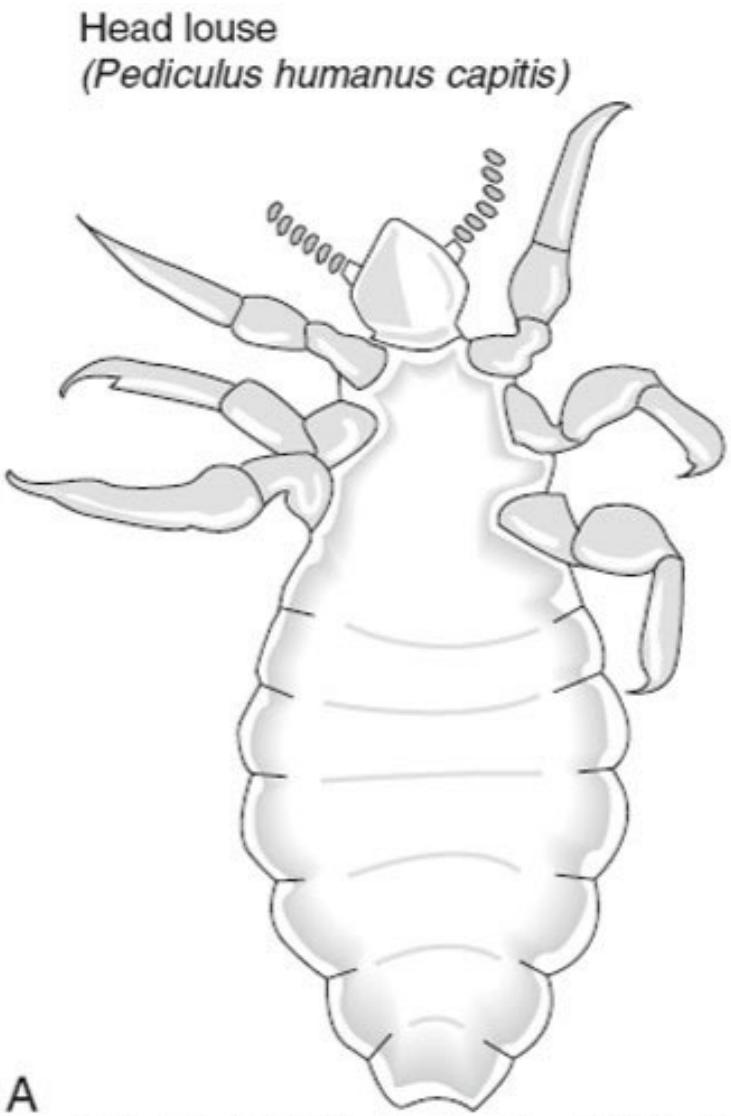

A,B. From Callen JP, et /al: Color Atlas of Dermatology, *Philadelphia, 1993, Saunders.C.* From Kumar V, Abbas AK, Fausto M: *Robbins and Cotran Pathologic Basis of Disease*, ed 7, Philadelphia, 2005, Saunders.

Skin Tumors

Keratoses

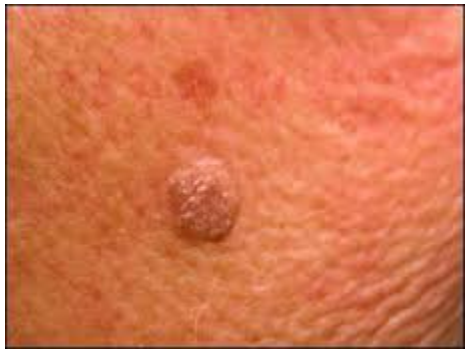

- Benign lesions usually associated with aging or skin damage.
- Seborrheic keratoses // Proliferation of basal cells // Lead to oval elevation // May be smooth or rough
- Actinic keratoses /// On skin exposed to ultraviolet radiation
  - Commonly in fair-skinned persons
  - Lesion appears as pigmented, scaly patch

Guidelines to Reduce Risk of Skin Cancers

- Reducing sun exposure at midday and early afternoon
- Covering up with clothing /// Remaining in shade // Wearing broad-brimmed hats to protect face and neck
- Applying sunscreen or sunblock
- Protecting infants and children from exposure and sun damage to skin
- Three form of skin cancer (see following slides)

Squamous Cell Carcinoma

- Painless, malignant tumor of the epidermis
- Lesions most commonly found on exposed areas of the skin but also in oral cavity
  - Face and neck
  - Base of tongue
- Excellent prognosis when lesion is removed within reasonable time
- Invasive type arises from premalignant condition.

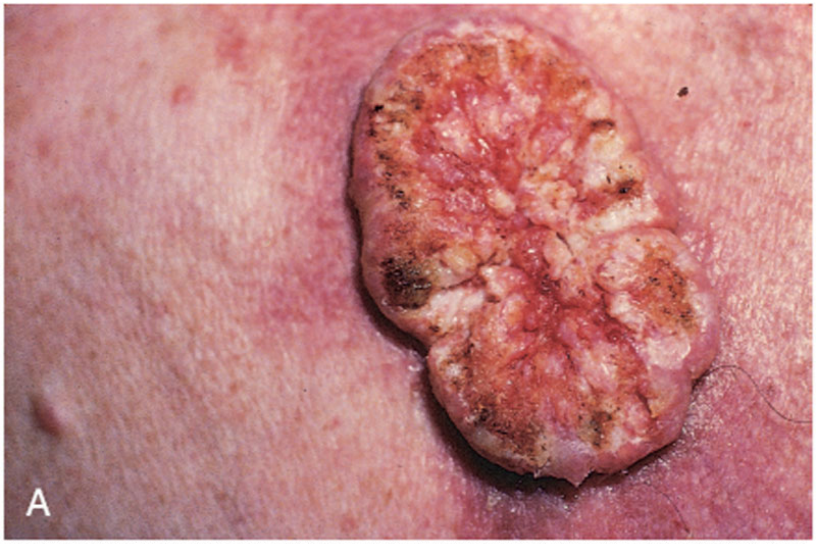

A. From Callen JP, et /al: Color Atlas of Dermatology, *Philadelphia, 1993, Saunders*. B. From Cooke RA, Stewart B: *Colour Atlas of Anatomical Pathology*, ed 3, Sydney, 2004, Churchill Livingstone.

Malignant Melanoma

- Highly metastatic form of skin cancer
- Develops in melanocytes /// From a nevus (mole)
- Often appear as multicolored lesion with irregular border
  - Grow quickly
  - Change in shape, color, size, texture
  - May bleed
- Treatment: surgical removal and radiation plus chemotherapy

Malignant Melanoma

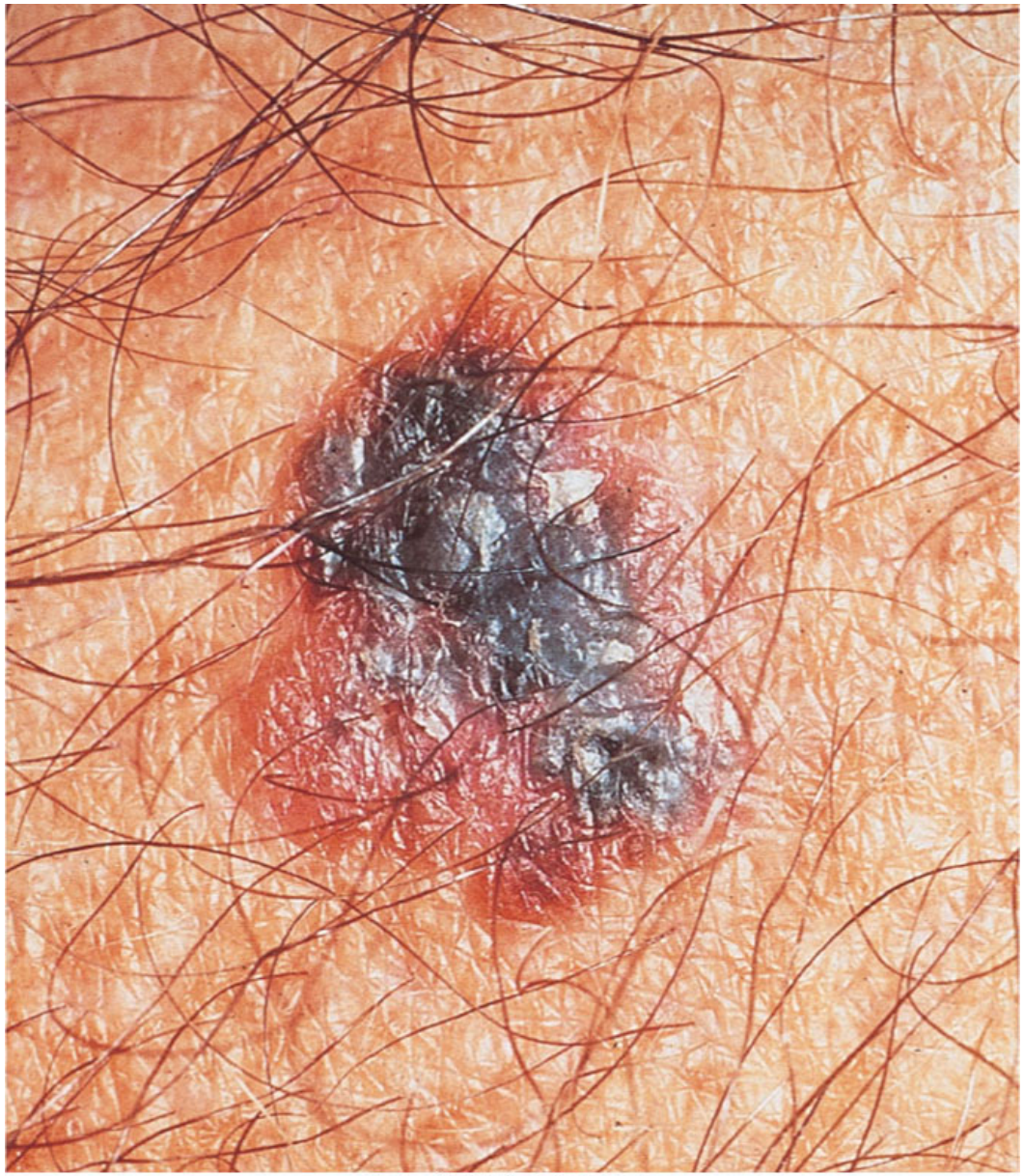

Courtesy of Dr. M. McKenzie, Toronto, Canada.

The ABCD of Melanoma

- Melanoma is suspected in any nevus that shows:
  - Change in ***appearance***
  - Change in ***border***
  - Change in ***color***
  - Increase in ***diameter***

Basal Cell Carcinoma

- Originates within the basal layer of the epidermis
- Least dangerous of the three skin cancers

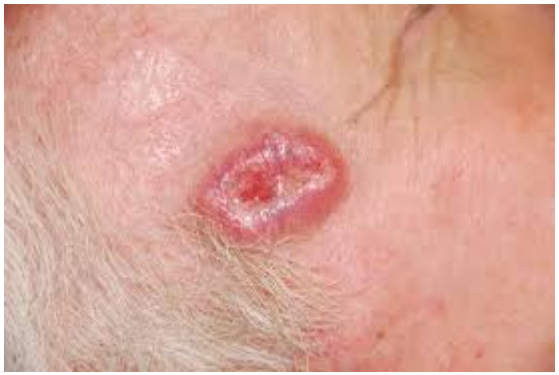

Kaposi's Sarcoma

- Occurs in those with AIDS and other immunodeficiency disorders
- May affect viscera as well as skin
- Malignant cells arise from endothelium in small blood vessels // Purplish macules // Nonpruritic, nonpainful
- In immunocompromised patients, lesions develop rapidly over upper body.
- Combination of radiation, chemotherapy, surgery, biological therapy